

HEALTH AND DISEASES OF ORAL CAVITY

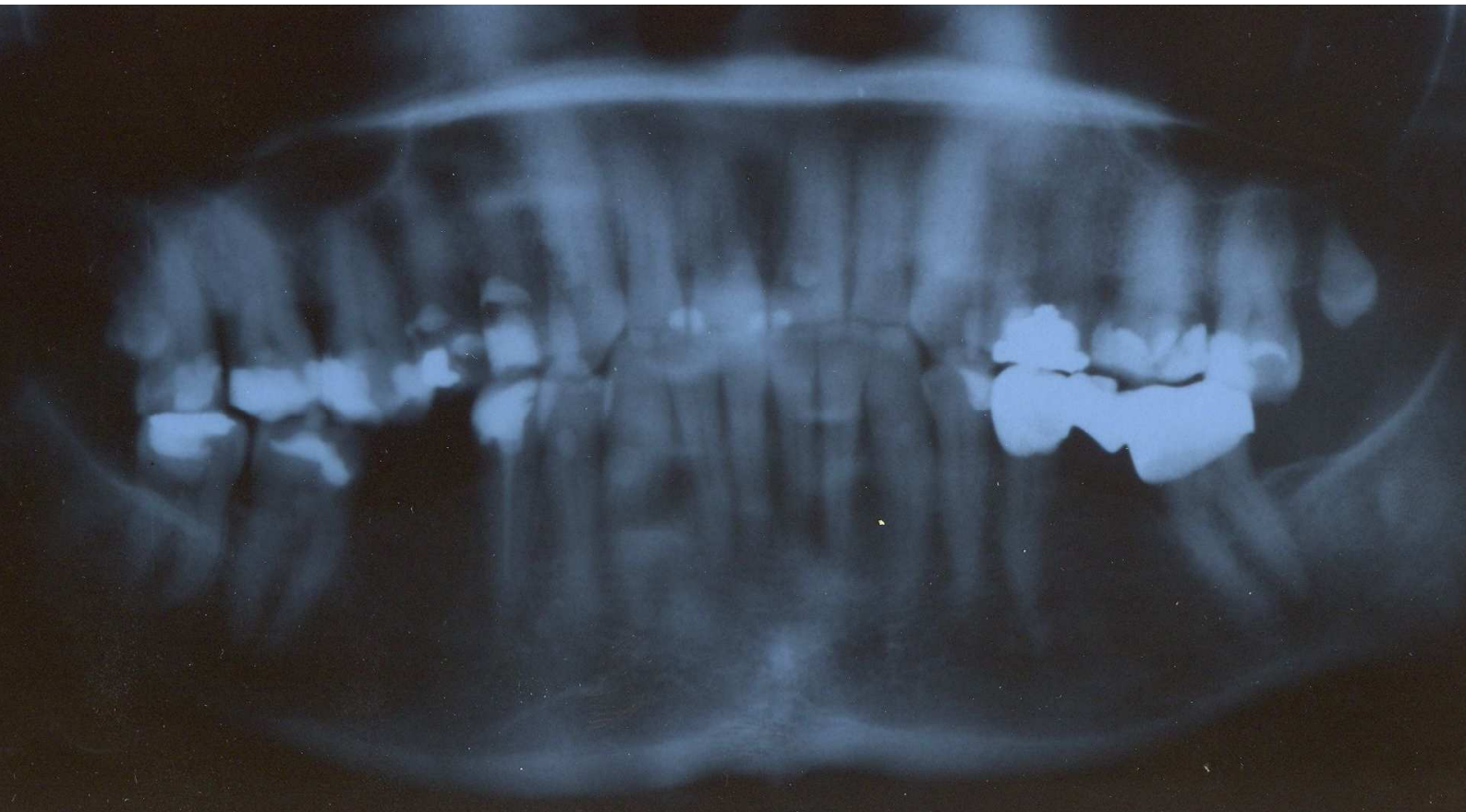
Tomasz M. Karpiński

Contribution:



Open Educational Resources
UKM Literasi Informasi & Perpustakaan Unsyiah

HEALTH AND DISEASES OF ORAL CAVITY



Edited by
Tomasz M. Karpiński

JB BOOKS

Poznań, Poland, 2017

Health and Diseases of Oral Cavity

Edited by

Tomasz M. Karpiński

Poznań University of Medical Sciences

Poznań, Poland

JB BOOKS

Poznań, Poland, 2017

Dr hab. Tomasz M. Karpiński, Assoc. Prof., DDS.
Department of Genetics and Pharmaceutical Microbiology
Poznań University of Medical Sciences
Święcickiego 4, 60-781 Poznań, Poland

TYPE OF PUBLICATION: REVIEWED SCIENTIFIC MONOGRAPH



Copyright: © Authors 2017. Licensee: Joanna Bródka.
This is an open access monograph licensed under the terms
of the Creative Commons Attribution Non-Commercial International License
(<http://creativecommons.org/licenses/by-nc/4.0/>)
which permits unrestricted, non-commercial use, distribution
and reproduction in any medium, provided the work is properly cited.

Cover Photo: Tomasz M. Karpiński

First Edition

ISBN 978-83-947078-1-1

DOI: <http://dx.doi.org/10.5281/zenodo.918266>

Publisher

Joanna Bródka
JB Books, Poznań, Poland
e-mail: jbbooks@interia.eu
www.jbrodka.com www.scitechopen.com

CONTENT

1. Desquamative gingivitis as the initial presentation of autoimmune bullous diseases <i>Hiroyasu Endo, Terry D. Rees, Hideo Niwa, Kayo Kuyama, Hiroya Gotouda, Hiroyuki Okada, Tetsuro Kono, Yoshiharu Kono, Hirotsugu Yamamoto, Takanori Ito</i>	2
2. Comparisons pseudo 3D Computer simulation and with Cone-Beam Computed Tomography (CBCT) for pathogenesis and rehabilitation of craniomandibular and cervical spine deformities by occlusal force <i>Kenji Doi</i>	22
3. Lifestyle and relationship with periodontal disease <i>Gaitán Fonseca Cesar, Araujo Espino Roxana, Aguilera Galaviz Luis Alejandro, Trejo Ortiz Perla, Correa Alcalde Teresina, Frias Muñoz Maribel</i>	61
4. Microbiology of dental plaque in periodontal health and disease <i>Shaila Kothiwale, Jyoti Ajbani</i>	78
5. Oral habits, malocclusion and postural changes in children <i>Luciana R. P. Cruz, Luciana A. Bezerra, Dayvson S. Santos, Hilton J. da Silva, Genival de O. Ramos Júnior, Niedje S. de Lima, Luciana B. C. Fontes</i>	95
6. Smile design with dental implants <i>Saurabh Gupta</i>	106

Desquamative gingivitis as the initial presentation of autoimmune bullous diseases

1

**Hiroyasu Endo^{1*}, Terry D. Rees², Hideo Niwa³,
Kayo Kuyama⁴, Hiroya Gotouda⁵, Hiroyuki Okada⁶,
Tetsuro Kono⁶, Yoshiharu Kono⁷, Hirotsugu Yamamoto⁴,
Takanori Ito¹**

¹ Department of Oral Diagnosis, Nihon University, School of Dentistry at Matsudo, 2-870-1 Sakaecho Nishi, Matsudo, Chiba, 271-8587, Japan

² Department of Periodontics, Texas A&M College of Dentistry, Dallas, TX, USA

³ Department of Head and Neck Surgery, Nihon University, School of Dentistry at Matsudo, Matsudo, Chiba, Japan

⁴ Department of Oral Pathology, Nihon University, School of Dentistry at Matsudo, Matsudo, Chiba, Japan

⁵ Department of Preventive and Public Oral Health, Nihon University, School of Dentistry at Matsudo, Matsudo, Chiba, Japan

⁶ Department of Histology, Nihon University, School of Dentistry at Matsudo, Matsudo, Chiba, Japan

⁷ Department of Dental Practice Administration, Nihon University, School of Dentistry at Matsudo, Matsudo, Chiba, Japan

* Corresponding author: Dr. Hiroyasu Endo; Tel: 81-47-360-9423; Fax: 81-47-360-9426;

E-mail: endo.hiroyasu@nihon-u.ac.jp

Copyright: © The Author(s) 2017. Licensee Joanna Bródka. This is an open access chapter licensed under the terms of the Creative Commons Attribution Non-Commercial 4.0 International License (<http://creativecommons.org/licenses/by-nc/4.0/>), which permits unrestricted, non-commercial use, distribution, and reproduction in any medium, provided the original work is properly cited.

ABSTRACT

Autoimmune bullous diseases are rare but represent a potentially devastating group of mucocutaneous diseases characterized by the presence of tissue-bound immunoreactants and circulating autoantibodies against various target antigens with disease specificity. Early signs and symptoms of mucous membrane pemphigoid (MMP) or pemphigus vulgaris (PV) develop in the oral cavity in almost all patients, so the symptomatic patient will usually seek care from their general dentist or periodontist. The purpose of this study was to describe

prominent clinical features that support a clinical diagnosis of autoimmune bullous diseases in the oral cavity. This study was based on a retrospective review of 24 records that were classified as MMP (16) or PV (8). All 24 patients were referred by general dental practitioners. The records included information on the referral letter, patient complaints, clinical sites, presence or absence of epithelial detachment, presence or absence of bulla formation on the oral mucosa and definitive diagnosis for the patient. The results indicate that the epithelial desquamation of the gingiva is a prominent clinical feature that supports early clinical diagnosis of autoimmune bullous diseases developed in the oral cavity. Asking for detailed symptoms will help confirm the clinical diagnosis since some patients are aware of the gingival desquamation. Dental healthcare providers should have greater knowledge of autoimmune bullous diseases, as careful interviewing and oral examinations will lead to a diagnosis and treatment for these diseases in the early stages. This early diagnosis and subsequent early treatment could significantly improve the clinical course of the diseases.

Keywords: Gingival diseases; Autoimmune diseases; Pemphigoid; Benign mucous membrane; Pemphigus.

1. INTRODUCTION

Autoimmune bullous diseases are rare but represent a potentially devastating group of mucocutaneous diseases characterized by the presence of tissue-bound immunoreactants and circulating autoantibodies against various target antigens with disease specificity [1]. The diseases are composed chiefly of two major groups, the subepithelial bullous diseases including pemphigoid [2], and pemphigus that forms intraepithelial acantholysis [3]. Among these, early signs and symptoms of mucous membrane pemphigoid (MMP) or pemphigus vulgaris (PV) develop in the oral cavity in almost all patients [4]. Consequently the symptomatic patient will usually seek care from their general dentist or periodontist.

MMP is one of a group of subepithelial bullous diseases predominantly affecting the mucous membranes. The target antigen of MMP is present in the basement membrane zone [2, 5]. Various components in the hemidesmosomes have been recognized as the target antigens of MMP, among which are 180 kDa bullous pemphigoid antigen (BP180), 230 kDa bullous pemphigoid antigen (BP230), $\alpha 6 \beta 4$ integrin, type VII collagen and laminin 332 [2, 5, 6]. Most patients with this disease are between 60 and 80 years of age [7-9]. It affects women

at a greater ratio of at least 2:1 compared to men [7-9]. Although MMP lesions may be present on any oral mucosal tissue, the gingiva is usually involved, and often desquamative gingivitis (DG) is the only oral manifestation of the disease [7, 10-12] (Table 1). Scarring and an associated loss of function are the major sequelae of some form of MMP, although it is rarely seen on the oral mucosa [11]. Histopathologic and direct immunofluorescence (DIF) examinations are critical to determine a definitive diagnosis of MMP. Histopathologically, MMP is characterized by subepithelial bullous formation [5, 13, 14]. The DIF examination of MMP patients shows the linear deposition of complement component C3 and immunoglobulin (Ig) G or other Ig in the basement membrane zone [5, 13, 14].

Table 1. Characteristic features of desquamative gingivitis

Gingival pain
Burning sensation, particularly after eating salty or spicy foods
Easy bleeding
Gingival erythema not resulting from plaque
Desquamation and erosion of gingival epithelium
Blister formation
Other intraoral and/or extraoral lesions
Possible positive Nikolsky's sign

Modified from Endo et al. [11] and Rees & Burkhart [12]

PV is a life-threatening condition characterized by intraepithelial acantholysis. During various phases of the disease, PV patients may have autoantibodies to the various antigens on the keratinocyte surface in the oral mucosa, skin tissue, and serum [1, 3]. It has been determined that the principal autoantigens in pemphigus patients are desmogleins (Dsgs), which are the components of desmosomes in the epithelium [15, 16]. Almost all patients with PV lesions restricted to the oral mucosa have only anti-Dsg 3 antibody in the serum, whereas patients with an advanced case of the disease involving the oral mucosa and skin may have both anti-Dsg 3 and anti-Dsg 1 antibodies [16, 17]. Most PV patients are in their fourth and fifth decade of life, and the disease is equally common in men and women [18-20].

Oral lesions are the first site of PV involvement in about 80% of patients [20, 21]. They are most commonly found in the buccal mucosa, palatal mucosa, gingiva and tongue, although they may develop in any region of the oral mucosa [18, 19, 22, 23]. On occasion, the

gingiva is the only site involved, and DG is a common manifestation of the disease [17, 18, 22, 24]. Histopathologic and DIF examinations are critical to make a definitive diagnosis of PV. In a histopathologic examination, PV is characterized by suprabasal acantholysis in the epithelium [13, 14]. The DIF examination in PV patients reveals that the deposition of IgG or other Ig and/or C3 in the intercellular space of the epithelium exhibits a characteristic "fishnet" or "chicken-wire" pattern [13, 14].

Table 2. The diseases or disorders responsible for desquamative gingivitis

The most frequent diseases or disorders
Oral lichen planus
Mucous membrane pemphigoid
Pemphigus vulgaris
Hypersensitivity reactions to dental hygiene products, food flavorings or preservatives
Other rare conditions*
Lupus erythematosus
Mixed connective tissue disease
Graft versus host disease
Erythema multiforme
Epidermolysis bullosa
Epidermolysis bullosa acquisita
Kindler syndrome
Chronic ulcerative stomatitis
Lichen planus pemphigoides
Plasmacytosis
Plasma cell gingivitis
Orofacial granulomatosis
Foreign body granulomas
Candidal infection
Linear IgA disease
Factitious injury of the gingiva
Crohn's disease
Psoriasis
Sarcoidosis
Adverse drug reactions

Modified from Endo et al. [26] and Rees & Burkhart [12]

* may possess some but usually not all of the clinical features of desquamative gingivitis

The term DG is a descriptive term that is common to several diseases or disorders [12, 14, 25, 26]. DG is not a disease entity, rather it connotes clinical signs of gingival epithelial sloughing, erythema, blister formation, pain etc, that may be associated with mucocutaneous or other diseases or disorders (Table 2). The severity and extent of DG caused by MMP or PV vary. Gingival erythema and desquamation of the epithelium may be minimal in some patients (Figs. 1, 2). In other patients, a wide range of gingival desquamation is observed (Figs. 3, 4). It is extremely important to accurately diagnose diseases or disorders causing DG because the prognosis varies depending on the underlying etiology. Although scarring is rarely a feature of the oral mucosa in patients with MMP, in extraoral mucosal sites scar formation may lead to an irreversible loss of function of the affected areas [11]. Sight-threatening ocular scarring and life-threatening upper airway obstruction have been reported [27, 28]. Early recognition and treatment of MMP lesions may prevent serious complications. Although PV rarely occurs, it is potentially fatal [29], so it is important to diagnose and treat it in its early stage. If the diagnosis is delayed due to inadequate initial management, the risk of disease spreading or complications may increase.

DG may be associated with painful symptoms of the gingiva that can significantly compromise a patient's ability to perform optimal oral hygiene practices, which will easily worsen plaque-related gingivitis and signs of DG [30-33]. As a result, periodontal therapy may be repeated, and the definitive diagnosis of the specific disease or disorder causing DG may be significantly delayed. If dental healthcare providers can identify characteristic lesions at an early stage, it will be possible to avoid delays in diagnosis.

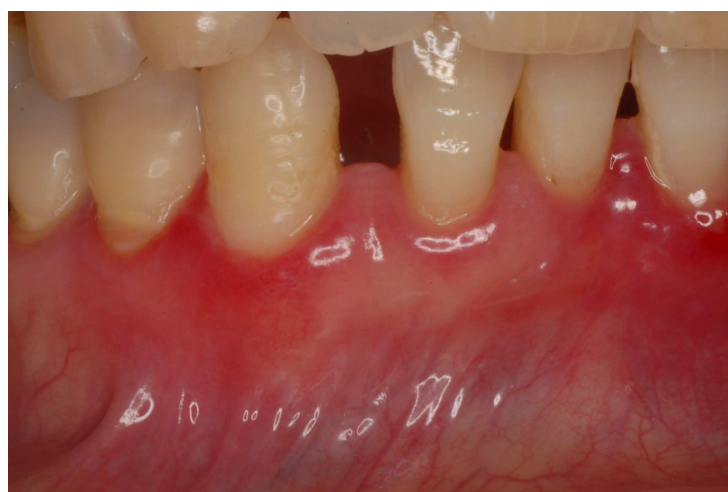

Fig. 1. Desquamative lesions featuring gingival erythema associated with mucous membrane pemphigoid

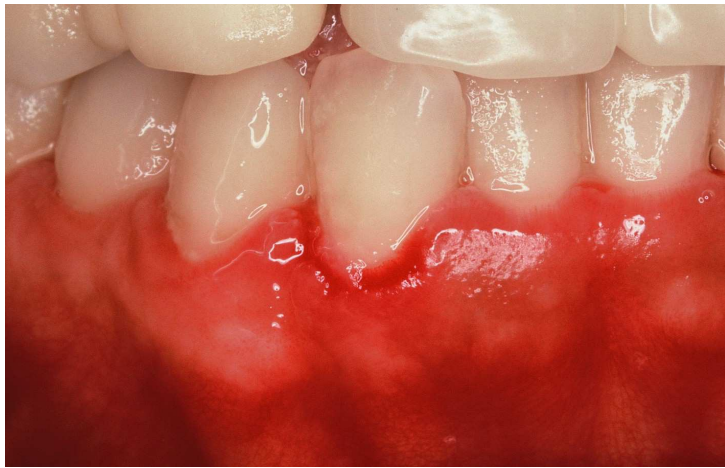

Fig. 2. Mild erythema of gingiva associated with pemphigus vulgaris

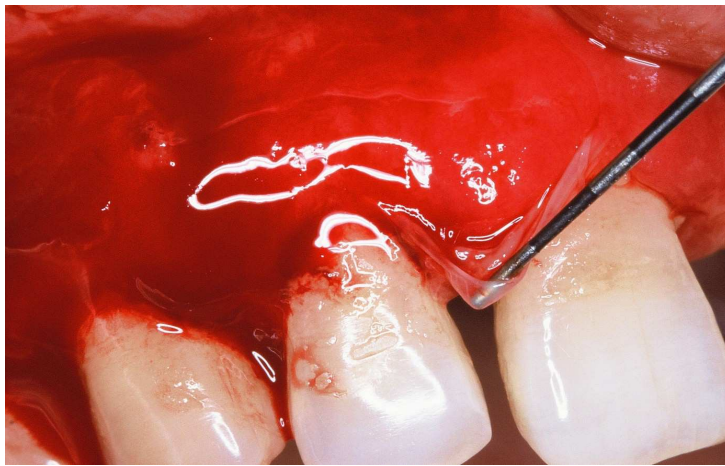


Fig. 3. Epithelial detachment of gingiva associated with mucous membrane pemphigoid

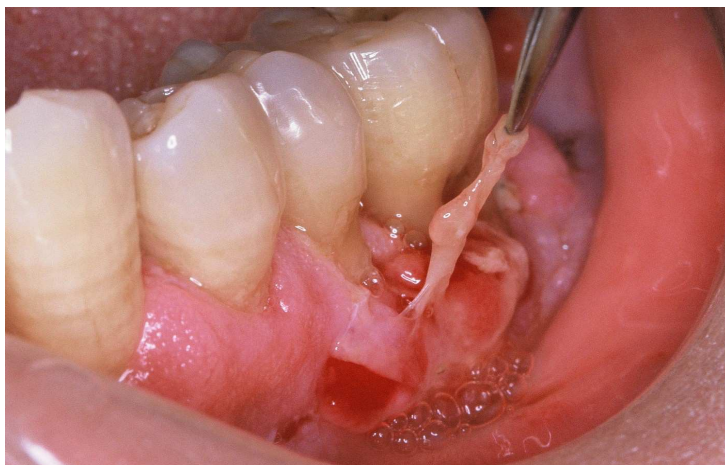


Fig. 4. Epithelial detachment of gingiva associated with pemphigus vulgaris

The purpose of this study was to describe prominent gingival features that support a clinical diagnosis of autoimmune bullous diseases such as MMP or PV in the oral cavity.

2. MATERIALS AND METHODS

This study was based on a retrospective review of 24 records that were classified as MMP (16 cases) or PV (8 cases) at Nihon University, School of Dentistry at Matsudo, from 2001 through 2016. The protocol of this study was approved by an institutional review board (Ethics Committee Approval no. EC14-011). Patients participating in the study included 7 males and 17 females, aged 24 to 80 years (mean age: 59.6 years). All 24 patients were referred to the author's facility by general dental practitioners. The records included information on the letters of referral, patient complaints, clinical sites, presence or absence of epithelial detachment by Nikolsky's test, presence or absence of bulla formation on the oral mucosa and definitive diagnosis for the patient. The descriptions in the referral letters also included the patient's clinical features, clinical diagnosis, and information on the treatment received from the referring dentist. At the initial appointment in the author's facility, a test for Nikolsky's sign was performed on all subjects by a single examiner (H.E.) using either a "marginal" method or by the "direct" method according to Mignogna et al. [34]. Briefly, a positive gingival Nikolsky's sign described extension of the erosion on the surrounding normal-appearing tissue by rubbing the edge of the affected area with a periodontal probe (the "marginal" method, Fig. 5), or the ease of inducing erosion by rubbing apparently unaffected gingiva distant from the lesions (the "direct" method, Fig. 6). A biopsy was performed that included perilesional tissue and was then submitted for routine histopathology and DIF study for each of the 24 patients (Figs. 7-10). All the gingival biopsies were performed by a single operator (H.E.) using the stab & roll technique [14]. The diagnostic criteria for MMP or PV are summarized in Table 3.

Table 3. Diagnostic criteria for autoimmune bullous diseases

Diagnosis	Histopathologic features	Direct immunofluorescence	
		Deposition	Location
MMP	Subepithelial clefting	C3, IgG or other Ig	BMZ
PV	Suprabasal clefting	C3, IgG or other Ig	ICS

MMP = mucous membrane pemphigoid; PV = pemphigus vulgaris; C3 = complement component C3; Ig = immunoglobulin; BMZ = basement membrane zone; ISC = intercellular space

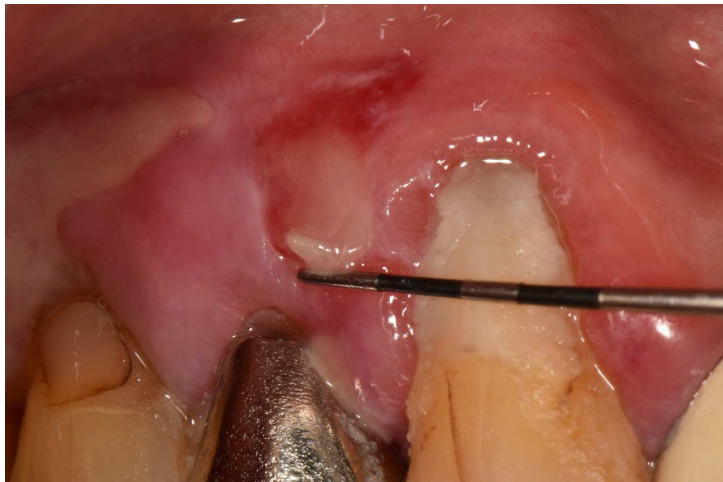

Fig. 5. Positive Nikolsky's sign associated with mucous membrane pemphigoid. The extension of the lesion on the surrounding normal-appearing tissue by rubbing the edge of the affected area with a periodontal probe (the "marginal" method)

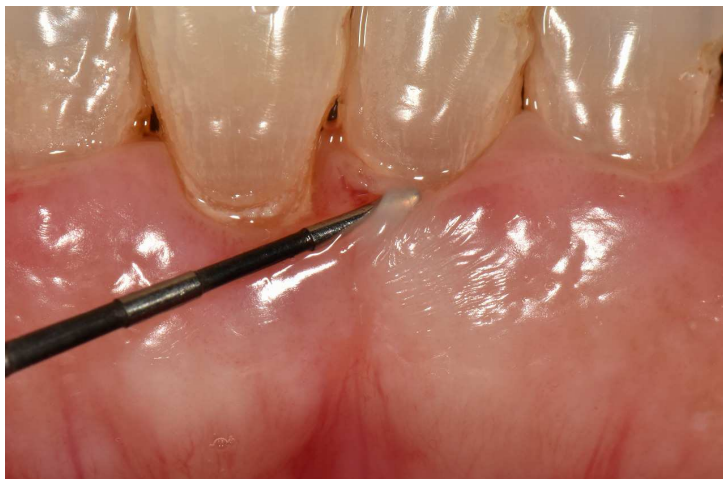

Fig. 6. Positive Nikolsky's sign associated with mucous membrane pemphigoid. The ease of inducing lesion by rubbing apparently unaffected gingiva distant from the lesions (the "direct" method)

3. RESULTS

Results summarizing the descriptions of the letters of referral are shown in Tables 4-6. The clinical features reported in the referral letter were ulcers/erosions (7 cases), epithelial desquamation (5 cases), gingival bleeding (5 cases), gingival erytnema (3 cases), gingival swelling (3 cases) and bulla formation (2 cases) (Table 4). Clinical diagnoses reported in the referral letter included pemphigus (2 cases), pemphigoid (1 case) and desquamatie gingivitis

(2 cases). Necrotizing ulcerative gingivitis, candidosis, herpetic gingivostomatitis, and lichen planus were also listed (Table 5). Periodontal therapy (11 cases, 45.8%) was the most common treatment received from the referral dentists, followed by a prescription for mouthwash (7 cases) and an antibiotic (5 cases). Topical steroid ointment was used in 4 cases (Table 6).

Table 4. Clinical features reported in 24 letters of referral

Clinical features	Number of patients*
Ulcers/erosions	7
Epithelial desquamation	5
Gingival bleeding	5
Gingival erythema	3
Gingival swelling	3
Bulla formation	2
Pseudo-membrane	1
White lesions	1
Others	5

* Patient had a description of one or more clinical symptoms

Table 5. Clinical diagnosis reported in 24 referral letters

Clinical diagnosis	Number of patients*
Stomatitis	3
Pemphigus	2
Desquamative gingivitis	2
Necrotizing ulcerative gingivitis	2
Candidosis	2
Periodontitis	2
Gingivitis	1
Pemphigoid	1
Lichen planus	1
Herpetic gingivostomatitis	1
Allergic reaction to metals	1
No description	2

* Patient had a description of one or more clinical diagnosis

Table 6. Treatment reported in 24 referral letters

Treatment	Number of patients*
Periodontal treatment	11
Prescription for mouthwash	7
Prescription for antibiotics	5
Prescription for topical steroid	4
Irrigations	2
No description	7

* Patient had a description of one or more treatment received

The results summarizing the patient complaints at the initial interview in the author's facility are shown in Table 7. Sore gums constituted the largest proportion (18 cases), followed by bleeding gums (16 cases) and swollen gums (13 cases). Nine patients complained of epithelial desquamation. Six patients had a history of bulla formation. Tables 8 and 9 show the results of the clinical examination of the oral mucosa. Gingival lesions consistent with DG were present in all 24 patients, as shown in Table 1. The lesions were localized to the gingiva in 18 patients (75%), although six (25%) also had involvement in the buccal mucosa, soft palate or tongue (Figs. 11, 12). A positive Nikolsky sign was demonstrated in 23 of the 24 patients (95.8%), and bulla formation (Fig. 13) was found in only two MMP patients (8.3%, Table 9).

Table 7. Patient complaints at the authors initial interview

Patient complaints	Number of patients*
Sore gums	18
Bleeding gums	16
Swelling gums	13
Epithelial desquamation	9
Burning sensation	7
Bulla formation	6

* Patient had a description of one or more complaints

Table 8. Sites of lesions at the initial intraoral clinical examination

	MMP (n=16)	PV (n=8)	Total
Gingiva alone	12	6	18 (75%)
Gingiva + other oral mucosa	4	2	6 (25%)

MMP = mucous membrane pemphigoid; PV = pemphigus vulgaris

Table 9. Nikolsky's sign and bulla formation at the initial intraoral clinical examination

	MMP (n=16)	PV (n=8)	Total
Positive Nikolsky's sign	15 (93.8%)	8 (100%)	23 (95.8%)
Bulla formation	2 (12.5%)	0 (0%)	2 (8.3%)

MMP = mucous membrane pemphigoid; PV = pemphigus vulgaris

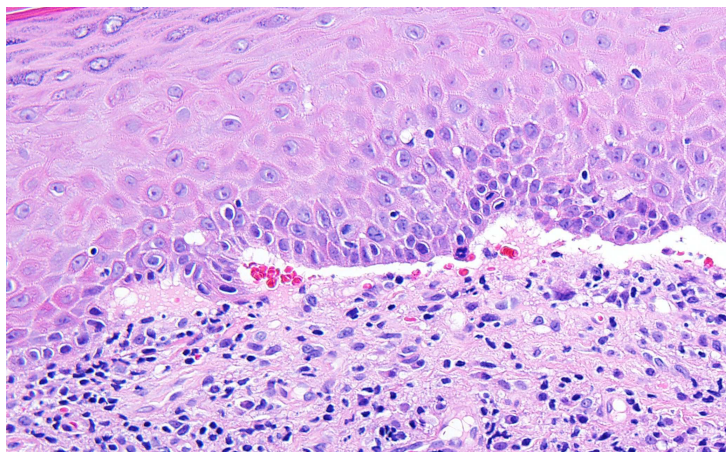


Fig. 7. Hematoxylin-eosin stained section of mucous membrane pemphigoid showing subepithelial bulla formation

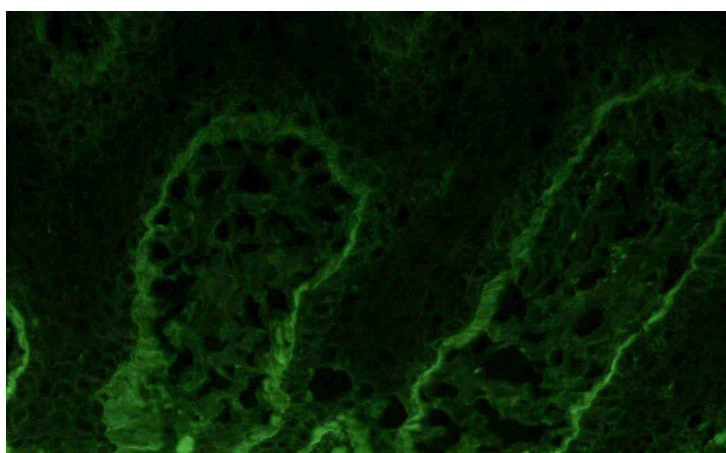


Fig. 8. Direct immunofluorescence of mucous membrane pemphigoid showing linear deposition of IgG at the basement membrane zone

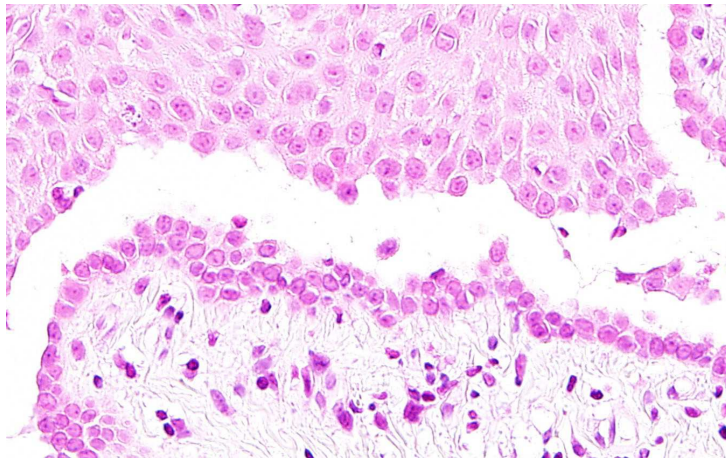


Fig. 9. Hematoxylin-eosin stained section of pemphigus vulgaris showing acantholysis and a suprabasilar split in the epithelium

Table 10 shows a summary of the epithelial desquamation of the gingiva. Epithelial desquamation was described in 11 of 24 patients (45.8%). Nine patients (Cases 3-11) themselves complained of this symptom. Among the letters of referral, there was a description of the epithelial desquamation in only three patients (Cases 3-5). In contrast, although there were no patient complaints, a description of epithelial desquamation was reported in two referral letters (Cases 1 and 2). A positive Nikolsky's sign was found in all 11 patients.

Table 10. Summary of the description of the epithelial desquamation of the gingiva (n=11)

Case	Reported in referral letter	Patient complaints	Nikolsky's sign	Diagnosis
1	+		positive	MMP
2	+		positive	MMP
3	+	+	positive	PV
4	+	+	positive	PV
5	+	+	positive	MMP
6		+	positive	PV
7		+	positive	MMP
8		+	positive	MMP
9		+	positive	MMP
10		+	positive	MMP
11		+	positive	MMP

+ = described epithelial desquamation; MMP = mucous membrane pemphigoid; PV = pemphigus vulgaris

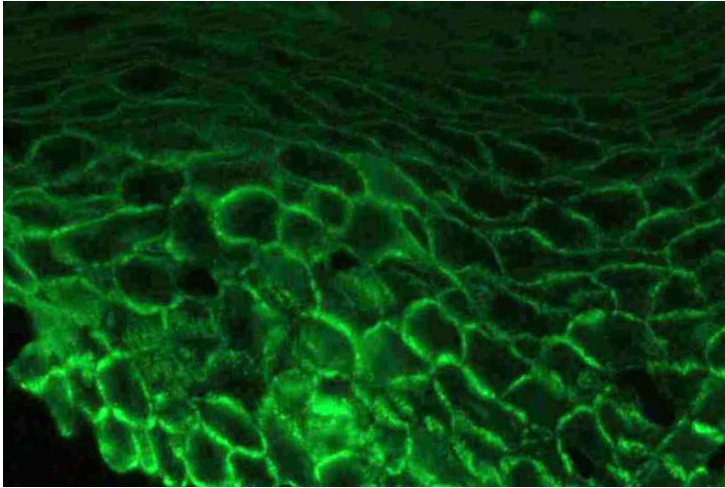


Fig. 10. Direct immunofluorescence of pemphigus vulgaris showing IgG in the intercellular spaces of the epithelium

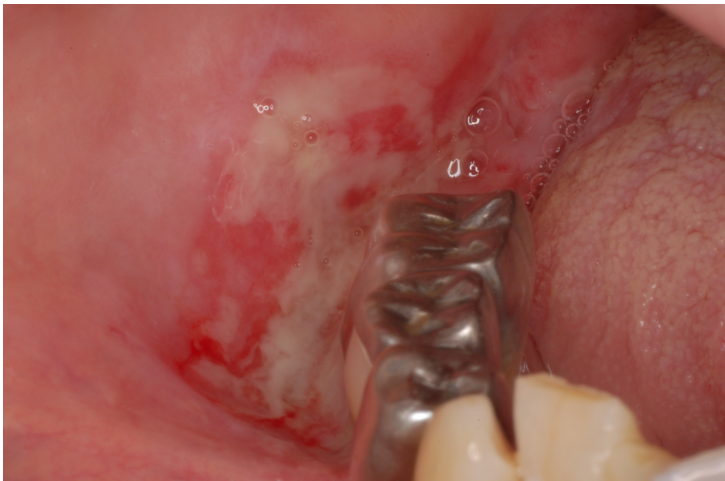


Fig. 11. Extragenital lesion of pemphigus vulgaris featuring erosion of buccal mucosa

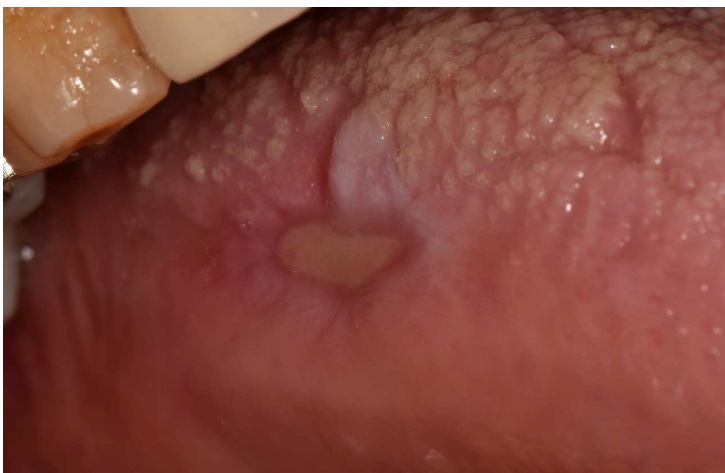

Fig. 12. Extragenital lesion of mucous membrane pemphigoid featuring ulceration of tongue

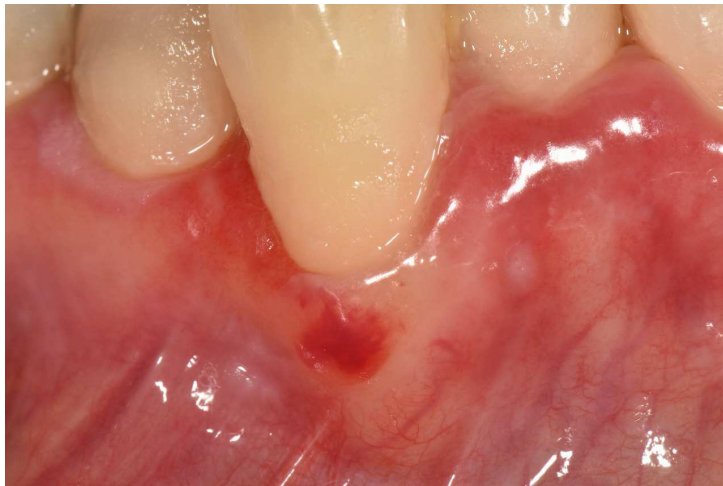

Fig. 13. A localized blood-filled bulla formed on attached gingiva associated with mucous membrane pemphigoid

4. DISCUSSION

The results of this study indicate that epithelial desquamation of the gingiva is a prominent clinical feature that supports early clinical diagnosis of autoimmune bullous diseases in the oral cavity. DG is often found to be closely associated with epithelial desquamation. Not all DG patients, however, display epithelial desquamation. DG patients associated with immune-mediated systemic connective tissue diseases or non-bullous lichen planus may only show clinical features limited to gingival erythema, swelling, erosions or ulcerations [34-39]. In this study, a positive reaction showing Nikolsky's sign was confirmed in 23 patients (95.8%). Nonetheless, there were only three referring dentists who made a clinical diagnosis of MMP or PV. DG was named as a clinical diagnosis in two cases, but it is important to remember that DG is a general descriptive term rather than a diagnosis. Carefully identifying the patient's symptoms may help to establish the situation involving the diagnosis since some patients are aware of epithelial desquamation of the gingiva. Epithelial desquamation was recognized by the patients themselves or referring dentists in 11 patients (45.8%, Table 10). It should be noted that despite mentioning epithelial desquamation in five patient referral letters, MMP or PV were not included in the differential diagnosis. This appears to indicate a limited understanding of the autoimmune bullous diseases that most often occur in the oral cavity. This study reconfirms that dental healthcare providers should

have knowledge of oral mucosal diseases as well as the ability to diagnose and manage dental caries and plaque-related periodontal diseases.

Nikolsky's sign is a simple diagnostic test that dental healthcare providers should use more often for the early diagnosis of oral autoimmune bullous diseases. The fact that 95.8% of the patients showed a positive Nikolsky's sign of the gingiva at the first visit in the author's facility indicates that if referring dentists were familiar with this test they would be more likely to include MMP and PV in the differential diagnosis. Nikolsky's sign was first described by Piotr Vasiliyevich Nikolskiy who was a Russian dermatologist [40]. Presently, "Nikolskiy" and "Nikolsky" are synonyms in the English literature [34, 40]. Originally, Nikolsky's sign was described as a characteristic of skin involvement in pemphigus foliaceus [41]. However, this phenomenon occurs not only in the active phase of pemphigus but also in diseases such as staphylococcal scalded skin syndrome [40, 41]. Therefore, Nikolsky's sign is characteristic of, but not diagnostic of pemphigus. Although the classic Nikolsky's sign is seen on the skin, it also appears in the oral mucosa [12, 25, 26, 34, 40]. In oral medicine, this phenomenon is commonly observed in several mucocutaneous diseases or disorders [12, 34]. The gingiva is a suitable site for Nikolsky's sign testing because of the ease of direct accessibility and the possibility of easily reproducing the test [34]. Generally, this sign is induced by applying a firm sliding or rubbing force to the mucosal surface using a dental tool such as a periodontal probe [11, 12, 25]. There are few studies on Nikolsky's sign for the oral mucosa, and there are almost no detailed descriptions of this technique. Grando et al. [40] introduced two modifications of the Nikolsky's sign: the "marginal" and the "direct". Mignogna et al. [34] used these techniques on gingiva to determine the specificity and sensitivity of gingival Nikolsky's sign in the identification of autoimmune mucocutaneous bullous diseases. The specificity of Nikolsky's sign was higher (96.3%) than sensitivity (46.7%), indicating that this sign is useful in the clinical diagnosis of oral blistering diseases and may represent a simple clinical tool for dental healthcare providers [34].

Bulla formation is also a characteristic finding of autoimmune bullous diseases. Blisters that develop in the oral mucosa, however, are rarely seen because they break quickly and show erosions or ulcerations instead. In this study, only two individuals with MMP (8.3%) had bulla at the first visit at the author's facility. However, it was possible to get the information on their history of oral bulla formation from six additional patients by doing careful interviews. This indicates that it is important to ask patients carefully thought out questions regarding the history of their oral disorder(s).

Many of these patients received periodontal therapy repeatedly at the referral dental clinic (Table 6) because the most frequent clinical site was the gingiva and because the DG was believed to represent unusual periodontal disease. The systemic administration of antimicrobial drugs was also often prescribed, but no benefits for DG were detected. Patients in this study had complaints of sore gums and burning sensations (Table 7), which may have hindered their oral hygiene. Plaque-induced gingivitis is almost universal in patients with symptomatic DG [30-33]. Gingival features of erythema, bleeding, or swelling seen in DG patients in this study are also commonly found in plaque-induced gingivitis, which may further compromise and delay the diagnosis and treatment of the autoimmune bullous diseases. Asking questions regarding a patient's response to previous periodontal treatment can often be a valuable basis for the diagnosis of autoimmune bullous diseases [12]. The clinical diagnosis for MMP or PV is often supported by the presence of extragingival or extraoral lesions consistent with a specific disease [12, 13, 36]. In this study, six patients (25%) had lesions on the buccal mucosa, soft palate or tongue in addition to DG. These extragingival lesions, of course, do not normally occur in plaque-induced gingivitis. A careful evaluation of the patient for both extraoral and intraoral involvement is essential to establish the diagnosis. In addition to oral lesions, MMP or PV may involve the skin, eyes, nose, pharynx, larynx, genitalia or anus [8, 10-12, 26-28]. Patients diagnosed with MMP or PV should be closely followed, as they may require immediate referral to other healthcare professionals, especially if they develop extraoral lesions. After MMP has been diagnosed from DG or concomitant lesions, patients should be examined by medical professionals including ophthalmologists and otolaryngologists, and the presence or absence of extraoral lesions should be determined. PV patients with exclusively DG lesions should be immediately referred to other experts if similar lesions occur elsewhere on the body. Dental healthcare providers are largely responsible for early detection, diagnosis and treatment or appropriate referral after identifying suspicious lesions.

5. CONCLUSIONS

DG is a clinical manifestation found in multiple diseases or disorders and often manifests as an initial sign of autoimmune bullous diseases including MMP or PV. Therefore, dental healthcare providers should always keep MMP or PV in mind as a possible differential diagnosis when they encounter DG. Epithelial desquamation of the gingiva is a prominent

clinical feature that supports a clinical diagnosis of MMP or PV. Asking detailed questions about signs and symptoms will help confirm the clinical diagnosis since some patients are aware of their gingival desquamation. Nikolsky's sign is a simple diagnostic test that can confirm the existence of gingival desquamation. It should be used often to facilitate clinical diagnosis of autoimmune bullous diseases. Steps in a definitive diagnosis should include a biopsy with histologic evaluation as well as DIF studies for autoimmune disorders. Dental healthcare providers should have greater knowledge of autoimmune bullous diseases, as carefully conducted interviews and oral examinations will lead to a diagnosis and treatment for these diseases in their early stages.

6. ACKNOWLEDGEMENTS

This study was supported by a Grant-in-Aid for Young Researcher Scientists, Nihon University School of Dentistry at Matsudo (2015). The authors report no conflicts of interest related to this study.

REFERENCES

1. Schmidt E, Zillikens D. Modern diagnosis of autoimmune blistering skin diseases. *Autoimmun Rev.* 2010; 10(2): 84-89.
2. Schmidt E, Zillikens D. Pemphigoid diseases. *Lancet.* 2013; 381(9863): 320-332.
3. Bystryń JC, Rudolph JL. Pemphigus. *Lancet.* 2005; 366(9479): 61-73.
4. Casiglia J, Woo SB, Ahmed AR. Oral involvement in autoimmune blistering diseases. *Clin Dermatol.* 2001; 19: 737-741.
5. Chan LS, Ahmed AR, Anhalt GJ, et al. The first international consensus on mucous membrane pemphigoid: definition, diagnostic criteria, pathogenic factors, medical treatment, and prognostic indicators. *Arch Dermatol.* 2002; 138: 370-379.
6. Calabresi V, Carrozzo M, Cozzani E, et al. Oral pemphigoid autoantibodies preferentially target BP180 ectodomain. *Clin Immunol.* 2007; 122: 207-213.
7. Lamey PJ, Rees TD, Binnie WH, Rankin KV. Mucous membrane pemphigoid. Treatment experience at two institutions. *Oral Surg Oral Med Oral Pathol* 1992; 74: 50-53.
8. Ahmed AR, Hombal SM. Cicatricial pemphigoid. *Int J Dermatol.* 1986; 25(2): 90-96.
9. Silverman S Jr, Gorsky M, Lozada-Nur F, Liu A. Oral mucous membrane pemphigoid. A study of sixty-five patients. *Oral Surg Oral Med Oral Pathol.* 1986; 61(3): 233-237.
10. Endo H, Rees TD, Kuyama K, Kono Y, Yamamoto H. Clinical and diagnostic features of

- mucous membrane pemphigoid. *Compend Contin Educ Dent*. 2006; 27: 512-516; quiz 517-518.
11. Endo H, Rees TD, Niwa H, Kuyama K, Yamamoto H, Ito T. Desquamative gingivitis as an oral manifestation of mucous membrane pemphigoid: Diagnosis and treatment. In: Vega JP ed. *Advances in Dermatology Research*. New York, USA: Nova Science Publishers; 2015, pp. 73-86.
 12. Rees TD, Burkhart N. Desquamative gingivitis. 2016 [cited 2017 Feb 9]. Available from: <https://www.dentalcare.com/en-us/professional-education/ce-courses/ce481>
 13. Rees TD. Desquamative gingivitis/mucocutaneous diseases commonly affecting the gingiva. In: Harpenau LA, Kao RT, Lundergan WP, Sanz M, eds. *Hall's Critical Decisions in Periodontology and Dental Implantology*, 5th edn. Connecticut, USA: People's Medical Publishing House; 2013, pp. 68-73.
 14. Endo H, Rees TD, Allen EP, et al. A stab-and-roll biopsy technique to maintain gingival epithelium for desquamative gingivitis. *J Periodontol*. 2014; 85(6): 802-809.
 15. Amagai M, Klaus-Kovtun V, Stanley JR. Autoantibodies against a novel epithelial cadherin in pemphigus vulgaris, a disease of cell adhesion. *Cell*. 1991; 67: 869-877.
 16. Amagai M, Tsunoda K, Zillikens D, Nagai T, Nishikawa T. The clinical phenotype of pemphigus is defined by the anti-desmoglein autoantibody profile. *J Am Acad Dermatol*. 1999; 40: 167-170.
 17. Endo H, Rees TD, Hallmon WW, et al. Disease progression from mucosal to mucocutaneous involvement in a patient with desquamative gingivitis associated with pemphigus vulgaris. *J Periodontol*. 2008; 79: 369-375.
 18. Lamey PJ, Rees TD, Binnie WH, Wright JM, Rankin KV, Simpson NB. Oral presentation of pemphigus vulgaris and its response to systemic steroid therapy. *Oral Surg Oral Med Oral Pathol*. 1992; 74: 54-57.
 19. Scully C, Paes De Almeida O, Porter SR, Gilkes JJ. Pemphigus vulgaris: the manifestations and long-term management of 55 patients with oral lesions. *Br J Dermatol*. 1999; 140(1): 84-89.
 20. Chams-Davatchi C, Valikhani M, Daneshpazhooh M, et al. Pemphigus: analysis of 1209 cases. *Int J Dermatol*. 2005; 44: 470-476.
 21. Sirois DA, Fatahzadeh M, Roth R, Ettl D. Diagnostic patterns and delays in pemphigus vulgaris: experience with 99 patients. *Arch Dermatol*. 2000; 136(12): 1569-1570.
 22. Mignogna MD, Lo Muzio L, Bucci E. Clinical features of gingival pemphigus vulgaris. *J Clin Periodontol*. 2001; 28: 489-493.
 23. Sirois D, Leigh JE, Sollecito TP. Oral pemphigus vulgaris preceding cutaneous lesions: recognition and diagnosis. *J Am Dent Assoc*. 2000; 131: 1156-1160.
 24. Endo H, Rees TD, Matsue M, Kuyama K, Nakadai M, Yamamoto H. Early detection and

- successful management of oral pemphigus vulgaris: a case report. *J Periodontol.* 2005; 76: 154-160.
25. Endo H, Rees TD. Diagnosis and management of desquamative gingivitis. In: Panagakos FS, Davies RM, eds. *Gingival Diseases - Their Aetiology, Prevention and Treatment*. Rijeka, Croatia: InTech; 2011, pp. 171-188.
 26. Endo H, Rees TD, Niwa H, et al. Desquamative Gingivitis. In: Manakil J editor. *Insights into Various Aspects of Oral Health*. Rijeka, Croatia: InTech; 2017. (in press).
 27. Higgins GT, Allan RB, Hall R, Field EA, Kaye SB. Development of ocular disease in patients with mucous membrane pemphigoid involving the oral mucosa. *Br J Ophthalmol.* 2006; 90: 964-967.
 28. Higgins TS, Cohen JC, Sinacori JT. Laryngeal mucous membrane pemphigoid: a systematic review and pooled-data analysis. *Laryngoscope.* 2010; 120: 529-536.
 29. Nair PS, Moorthy PK, Yogiragan K. A study of mortality in dermatology. *Indian J Dermatol Venereol Leprol.* 2005; 71: 23-25.
 30. Tricamo MB, Rees TD, Hallmon WW, Wright JM, Cueva MA, Plemons JM. Periodontal status in patients with gingival mucous membrane pemphigoid. *J Periodontol.* 2006; 77: 398-405.
 31. Schellinck AE, Rees TD, Plemons JM, Kessler HP, Rivera-Hidalgo F, Solomon ES. A comparison of the periodontal status in patients with mucous membrane pemphigoid: a 5-year follow-up. *J Periodontol.* 2009; 80: 1765-1773.
 32. Arduino PG, Lopetuso E, Carcieri P, et al. Professional oral hygiene treatment and detailed oral hygiene instructions in patients affected by mucous membrane pemphigoid with specific gingival localization: a pilot study in 12 patients. *Int J Dent Hyg.* 2012; 10: 138-141.
 33. Leao JC, Ingafou M, Khan A, Scully C, Porter S. Desquamative gingivitis: retrospective analysis of disease associations of a large cohort. *Oral Dis.* 2008; 14: 556-560.
 34. Mignogna MD, Fortuna G, Leuci S, Ruoppo E, Marasca F, Matarasso S. Nikolsky's sign on the gingival mucosa: a clinical tool for oral health practitioners. *J Periodontol.* 2008; 79(12): 2241-2246.
 35. Suresh L, Neiders ME. Definitive and differential diagnosis of desquamative gingivitis through direct immunofluorescence studies. *J Periodontol.* 2012; 83: 1270-1278.
 36. Lo Russo L, Fedele S, Guiglia R, et al. Diagnostic pathways and clinical significance of desquamative gingivitis. *J Periodontol.* 2008; 79: 4-24.
 37. Lorenzana ER, Rees TD, Glass M, Detweiler JG. Chronic ulcerative stomatitis: a case report. *J Periodontol.* 2000; 71: 104-111.
 38. Qari H, Villasante C, Richert J, Rees TD, Kessler H. The diagnostic challenges of separating chronic ulcerative stomatitis from oral lichen planus. *Oral Surg Oral Med Oral*

- Pathol Oral Radiol. 2015; 120: 622-627.
39. Endo H, Rees TD, Kuyama K, Matsue M, Yamamoto H. Successful treatment using occlusive steroid therapy in patients with erosive lichen planus: a report on 2 cases. *Quintessence Int.* 2008; 39(4): e162-e172.
 40. Grando SA, Grando AA, Glukhenky BT, Doguzov V, Nguyen VT, Holubar K. History and clinical significance of mechanical symptoms in blistering dermatoses: a reappraisal. *J Am Acad Dermatol.* 2003; 48(1): 86-92.
 41. Doubleday CW. Who is Nikolsky and what does his sign mean? *Am Acad Dermatol.* 1987; 16(5 Pt 1): 1054-1055.

Comparisons pseudo 3D Computer simulation and with Cone-Beam Computed Tomography (CBCT) for pathogenesis and rehabilitation of craniomandibular and cervical spine deformities by occlusal force

2

Kenji Doi

Yokohama Yamate Dental Clinic / Doi Research Institute of Oral Science, 60 Yamatechou, Nakaku,
231-0862 Yokohama, Japan

Copyright: © The Author(s) 2017. Licensee Joanna Bródka. This is an open access chapter licensed under the terms of the Creative Commons Attribution Non-Commercial 4.0 International License (<http://creativecommons.org/licenses/by-nc/4.0/>), which permits unrestricted, non-commercial use, distribution, and reproduction in any medium, provided the original work is properly cited.

ABSTRACT

The objective of this study is to investigate the biomechanical effects of the occlusal conditions on problems in musculoskeletal dysfunction of the head, neck and TMJ. We have tried to simulate the spine deformities in the cervical region caused by malocclusion using a displacement incremental method (DIM) in the pseudo-three-dimensional finite element method (FEM) based on the spanning element theory. For the simulation of the deformity process, DIM was used to accumulate the displacements at each stage of FEM analysis iteratively. The same loads were repeatedly applied on the displaced model so that the deformity gradually developed. The development process of postural abnormality or kyphotic deformity of the spine was simulated under a malocclusion condition. We analyzed the patient's spine deformities with 3D images (CBCT) and compared the pseudo 3D FEM model to 3D (CBCT). Further, we compared the FEM model to CBCT and MRI images, and sought to integrate the results of biomechanical analysis with the findings from this vast clinical area.

Keywords: Pseudo 3D FEM; CBCT; Cervical spine deformity; Malocclusion; Unbalanced Cranial Cervical Temporomandibular System; Lateral pterygoid muscle; Mandibular position (Gravitational Relation); Deformation and dislocation of the TMJ, head, neck and body; Doi Balanced Home Position Theory.

1. INTRODUCTION

There have been multiple reports of cases where patients describe a series of conditions including vertigo, chronic headaches, facial pain, and pain in the head, neck, shoulders and lower back. Although it could be suspected that these symptoms may be caused by abnormalities in the nervous system, circulatory system, musculoskeletal system or in some cases endocrine systems, objective symptoms or abnormalities could not be detected through examinations and tests. Thus, these patients were diagnosed as having dysfunctions of unknown cause. Those who are diagnosed as having “general malaise” are said to make up roughly 65% of all patients that go to see a physician and 35% of those who seek the aid of gynecologists [1, 2]. It is also said that 229.5 per 1000 female people in Japan experience pain in the shoulders and lower back [3].

Furthermore, there are reports that of all patients who regularly visit an orthopedist, about 8% of them, despite having symptoms that seemingly relate to the field of orthopedics, are diagnosed as having disease of unknown etiology [4]. It has also been reported that adolescent scoliosis patients often have temporomandibular joint (TMJ) problems and the treatment to correct their malocclusion showed a marked improvement in the curvature of the spine [5].

On the other hand, it has also been pointed out by carefully observing dental care providers that many patients suffering from general malaise also have malocclusion. In these patients, history of trauma, cervical spine deformities, or atlanto-axial subluxations were not found by radiologists and orthopedists.

Patients suffering from general malaise caused by malocclusion often seek the help of physicians, psychosomatists, orthopedists, neurosurgeons or even ophthalmologists and psychiatrists. Despite being tested, they will be diagnosed to be normal. But the symptoms will only grow worse. We have previously reported the mechanism of how malocclusion may cause dentally induced general malaise [6, 7].

In the author's private practice, many patients with general malaise are encountered. Typically, they express symptoms in more than a few organs, accompanied by symptoms indicating emotional stress such as anxiety, depression, and irritation.

The author has, based on the results from the aforementioned study, has developed an intraoral device which corrects occlusion so that the mandible is guided to a 3-dimensional position where it is in a biomechanically optimal relation to the (1) head and neck, (2) the craniofacial area, and (3) Body Trunk. This device was applied to consenting patients. Many patients reported there to be significant improvements in symptoms.

The objective of this study was to figure out how to achieve a biomechanically optimal relation. The findings from the biomechanical analysis and clinical reality was integrated, after observing that they match, into the figure below:

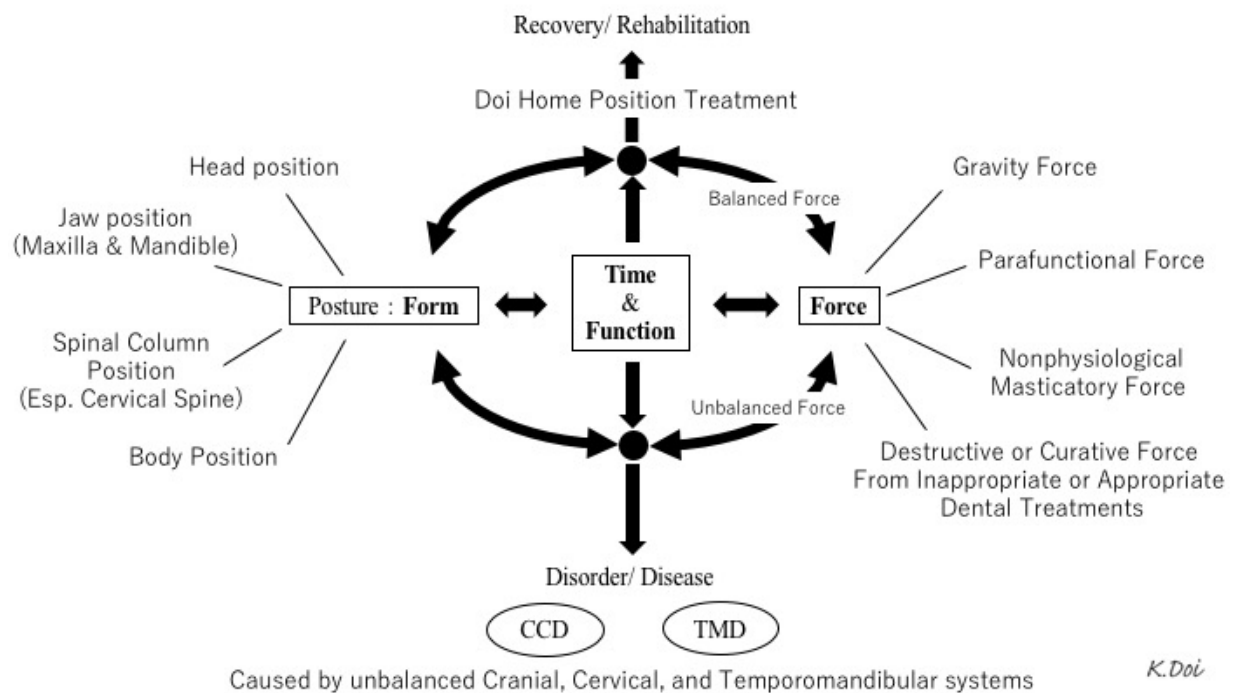


Fig. 1. The relationship between Force, Form and Function, which could create a downward or upward spiral

For example, a change to the force (making it balanced or unbalanced) leads to a change in the form (the posture of the human body), which in turn causes the function of the body to change over time. The function and/or form could cause the forces at play to change

as well. In other words, Force, form and function affects each other. If the changes are destructive, it will cause disorders or diseases like CCD (Cervical spine Craniomandibular Disorder) and TMD (Temporomandibular Disorder). If appropriate changes are made, it will lead to recovery and rehabilitation from diseases.

There is a point I want to make regarding parafunctional force. Parafunctional Force is usually seen as a destructive force. This is usually the case, especially as an oral function. But from a clinical perspective regarding the brain, sleep bruxism the during night involving the horizontal movement of the mandible caused by the lateral pterygoid muscle, when the head is liberated from gravitational force, may play an important role in the recovery of the brain function relieving stress. In this context, this parafunctional force can be regarded as being beneficial to the brain.

In this paper, the author would like to clearly explain why this intraoral device improved the symptoms in patients, how it affected which organ systems, and suggest it become a new form of treatment for general malaise.

I propose that general malaise, resulting from the oral area, be called Cervical spine Craniomandibular Disorder (CCD), and recognized by those in the medical field as well, becoming part of the differential diagnosis process. Before checking for endocrine disorders, dysautonomia, psychiatric disorders and organic diseases, I suggest that we suspect CCD. If it is indeed CCD, most of the time it can be treated by diagnosing and treating dental diseases. As a result, the patient can benefit from gaining the time and money that would otherwise be wasted on unneeded treatments.

I would like to go on to explain why CCD develops, in what kind of cases we should suspect CCD, and why it can be cured.

The functions of organic systems, or other systems of the body, are maintained through balance, including well balanced biomechanical factors. In recent years, it came to be known that the collapse of such balance is the cause of a wide range of illnesses.

It was predicted that the system comprised of maxilomandibular, facial, cranial, and cervical components would work in the same way, resulting in illness when biomechanical factors were out of balance. It was also predicted that biomechanical factors need to be considered in order to cure such conditions. The purpose of this study was to figure out the specific conditions of the biomechanical factors needed to keep this system in balance.

The author's results of the following experiment matched those seen in over 40 years of its appliance in clinical situations. These experiments and treatments alike were done according to this common principle: The mandible must be autonomously guided to a position

where it is in a biomechanically optimal relation to the face, head, neck, and rest of the body. The author treated many clinical cases based on this principal and saw clinical improvements. The experiment involves a computer-simulated biomechanical mathematical model uniquely developed for this purpose. The model was used to recreate the process from normal to deformed state. The same model was then used to determine the mechanism and conditions in which this process can be reversed; from the deformed state to the recovered state. The conditions thereof match the properties of the intraoral device created by the author (Doi Balanced Home Positioner). The state of the recovered model, created using finite element method (FEM), matches the data of patients who received treatment. This proves the validity of this treatment.

The pseudo-3D FEM model was created so that it replicates the unique factors of the body such as its nonlinearity, its continuity of all adjacent components within, and the layered structure of its components. Using this model, it was possible to clearly see the effect of the forces at play, thus making it possible to determine at what levels it will create significant stress, dislocation, or deformation.

In most cases, a recurrent behavior of the body can be judged as one of its function. In this experiment, uneven use of the mandible on either side or uneven contact of maxillary and mandibular teeth can be considered a destructive form of “recurrent behavior”. This creates change in the position of the head and deformations of the cranial spine, forming a decrepit posture. This decrepit posture causes more change and deformations; the repetitive gravitational conditions accumulating and amplifying over time. This method can be thought of as recreating aging; the displacements representing the functional adaptation or remodeling process of bone structure.

There have been no reports concerning a biomechanical analysis of the complete relationship between unbalanced biting strength, unbalanced posture, temporomandibular disorders (TMD), and CCD. This paper aims to report the findings of the experiment so that it illustrates the whole picture of these relationships, giving the parts and the whole a sense of entirety with the element of time considered (Fig. 1).

Furthermore, we will study and analyze cases by comparing the results from the simulation experiment and images from patients including CBCT and MRI.

2. MATERIALS AND METHODS

2.1. Materials and methods of the simulation model experiment

First, a pseudo-3D model was constructed. The sagittal view of the cervical spine, maxilla and mandible was modeled and divided into six slices with 1072 nodes and 2069 elements composed of the cortex and spongiosa of spinal bodies, endplate of the vertebral bodies, annulus fibrous and nucleus pulposus of the intervertebral discs, anterior and posterior longitudinal ligaments, laminae, spinous processes, ligamenta flava, interspinous and supraspinous ligaments, upper and lower teeth, articular disc, and a part of the cranium (Fig. 2).

Table 1. Material properties for the model

Material	Elastic Modulus (MPa)	Poisson's ratio
Mandibular, maxilla bone	10000	0.29
Tooth	20000	0.29
TMJ - disk	1	0.49
Food	1	0.49
Cortex	10000	0.29
Spongiosa	450	0.25
Endplate	150	0.30
Nucleus pulposus	160	0.49
Anulus fibrous	35	0.49
Ligament (tensile) ^a	170	0.36
Ligament (compressive) ^a	1	0.45
Facet	25	0.45
Cranium	10000	0.29

^a When a tensile stress in the vertical direction is observed in the ligament, the ligament's property takes upper values. When a compressive stress is observed in the ligament, its property takes lower values

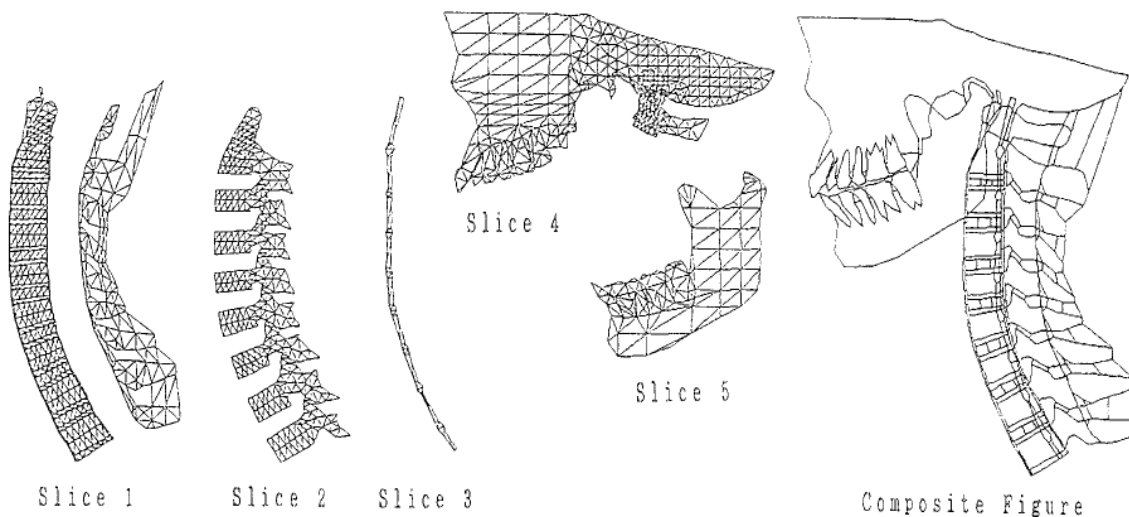


Fig. 2. The complete form and slices of the model

In general, the activities of muscles on the skeleton are classified in three types: (1) effect on joint movement, (2) effect on stabilizing of joint and bone, and maintaining of body posture, and (3) effect on the motor unit toward the outside. While the ligaments around the cervical spine have much stronger and more rigid effect of the type (2) on stability of all the seven cervical vertebrae (C1-C7), the neck extensor and flexor muscles have mainly the effects of type (1) and (3) and attach only to some parts of the cervical spine and head. It seems that the ligaments would be much more important for the mechanical maintenance and reaction against the influence of the malocclusion than the muscles, apart from the masticatory muscles. Therefore, the muscles around the cervical spine were ignored in this model to examine the pure influence of malocclusion on posture and remodeling of the tissues in the cervical spine areas.

The materials properties were listed in table 1. The slices were connected together with the spanning nodal points where those slices join anatomically and forces are transmitted from one slice to other. For example, in the vertebral body the upper, lower and anterior borders were connected, but the internal part of the vertebral body and the posterior border were left free as shown in Fig. 3. The mandible was connected with the maxilla through the TMJ disk and food between biting teeth. Those slices were assembled together and bonded at the anatomically connecting nodes according to the spanning element theory [7]. Thus, this model can be called a pseudo three-dimensional model.

The lower border of the 2nd thoracic vertebra was fixed as a boundary condition. As loading conditions, forces derived from four masticatory muscle groups (Fig. 4) and head

weight were taken into account. Since the forces of each muscle group have never been measured directly and reported, we assumed that the muscle forces are proportional to their anatomical weights. The forces were assigned ten times as much as their statistical mean weights in our anatomical measurements of Japanese adults; masseter = 15.6 N, temporalis = 12.5 N, lateral pterygoid = 8.8 N, and medial pterygoid = 11.3 N. The resultant occlusal force by those four muscle forces was 48.6 N calculated as a reaction force in our FEM analysis, and this suggests the adequacy of the muscle forces. The head weight of 40 N was applied vertically at a supposed center of gravity marked by an asterisk (Fig. 4).

Using this model, we simulated and analyzed the (1) deformity process and (2) recovery process using the displacement incremental method (DIM). This was used to accumulate the displacements at each stage of FEM calculation iteratively. The same loads were repeatedly applied on the displaced model so that the deformity gradually developed. The same loads were repeatedly applied on the model a given number of times to produce the final results. In this experiment, the loads were applied 250 or 500 times. The number of times the loads are applied represents how much time has elapsed since the forces were applied in this way. But it is unclear whether the 250 times calculation, for example, is equivalent to 250 days or 25 years in real life. This is a matter that needs further exploration.

During each experiment, the mandible was connected to the maxilla through the TMJ disk and a food element between biting teeth. This “food” element was used not to simulate food, but rather to control were the maxillary and mandibular teeth contact. In the deformity process experiment, the food element was placed so that the premolars contact. This was to simulate clinical cases were (1) molars were missing on one side resulting in a displacement of the mandible to either side or when (2) crowns or restorations were too high resulting in abnormally heavy bite forces to the teeth in question. In the two-staged recovery process experiment, a number of conditions with the "food" with varying thickness, length (partial or full coverage), location (position) were tried. (The condition which was most successful in cervical spine dislocation and deformation recovery was determined. This condition became the basis of creating the intraoral devices that we will later refer to as the Doi Balanced Home Positioner. See the clinical findings section for details). Also, another run of the experiment was done to recreate the effects of a normal occlusion.

After all the experiments were finished, the minimum and maximum principal stress was analyzed.

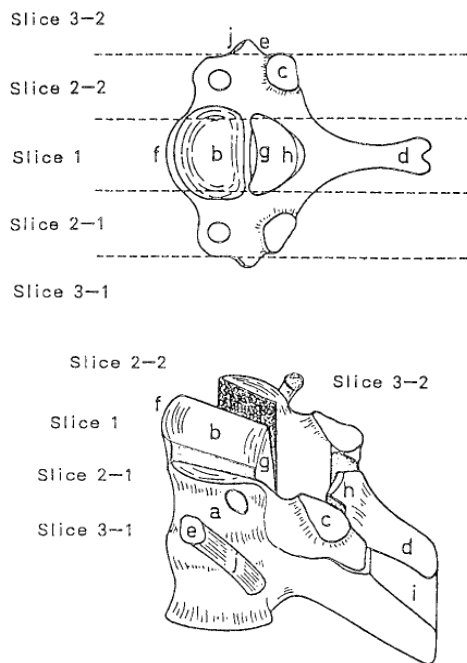


Fig. 3. Anatomical figures of a cervical spine motion segment. These show (a) spinal body; (b) disc; (c) facet; (d) spinal process; (e) transverse process; (g) anterior longitudinal ligament; (h) ligamentum flavum; (i) interspinous and supraspinous ligaments, and (j) transverse ligaments. The divisions of the cervical spine into slices 1, 2-1, 2-2, 3-1, 3-2 are shown by the broken lines

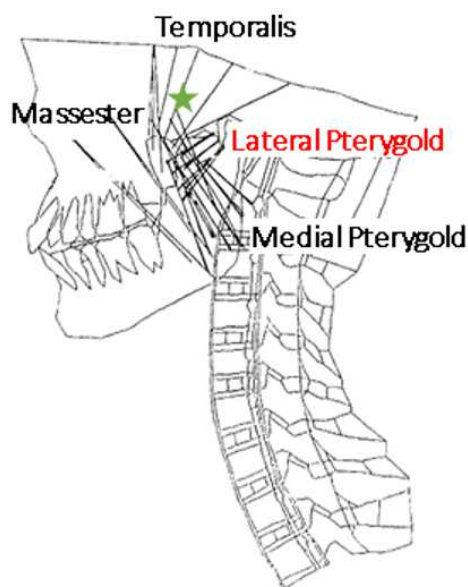


Fig. 4. The loading condition of the model with the forces by the four masticatory muscles and the weight of the head at its center of gravity (asterisk) indicated. The lateral pterygoid muscle and the center of gravity will be an important focal point of the experiment

2.2. Materials and methods of CBCT analysis

Invivo5 (Anatomage Inc.) software was used to calculate the angles between the lateral pterygoid muscle and the occlusal plane. The lateral pterygoid muscle was defined as the line connecting the anatomical points on bones that represents the origin and insertion of the muscle. The occlusal plane was defined as the line connecting the mesiobuccal cusp of the lower first and second molars. Both the left and right sides were calculated.

The techniques were used as follows:

First, the CBCT images were imported into Invivo5. Then, using the built-in 3D analyzing function of the software, reference points and planes were determined and set. The Frankfurt horizontal plane was used as the standard reference plane. Although during taking the CT, measures were taken to fix the head so that the Frankfurt plane of the patient would almost be parallel to the floor, it would not be exact every time. Since the CBCT data used were the raw data, it was necessary to plot the reference points and “standardize” the measurements for every patient. To do this, predetermined anatomical points were plotted using the software to create a 3-dimensional standard. The anatomical points referenced to create the standard were “Or” of both sides, “Po” of both sides and “N”.

After setting the 3-dimensional standard, the occlusal plane of the lower molars was determined. The points 6R, 7R, 6L, and 7L were set to the mesiobuccal cusp of the lower right first molar (#46 in FDI), lower right second molar (#47), lower left first molar (#36), and lower left second molar (#37) respectively. The points set were then checked using the 3D analyzing feature of the software. As for the lateral pterygoid muscle, Proc mR and Proc mL (we will call this the "D point" or "Doi point"), defined as the mid-point of the superior margin (where the great wing of sphenoid and pterygoid plate meet) and inferior margin (the end of the pterygoid plate), were used as reference points. The points set were checked using ScaleGrid (Daiichi System Engineering Inc.) (Fig. 7). As for the condyloid process, the most concaved point in a sagittal cross-section on the anterior surface (Co_R and Co_L) was used as the reference point. After all the points above were plotted, measurements were taken using the measurement function of the software and used for analysis.

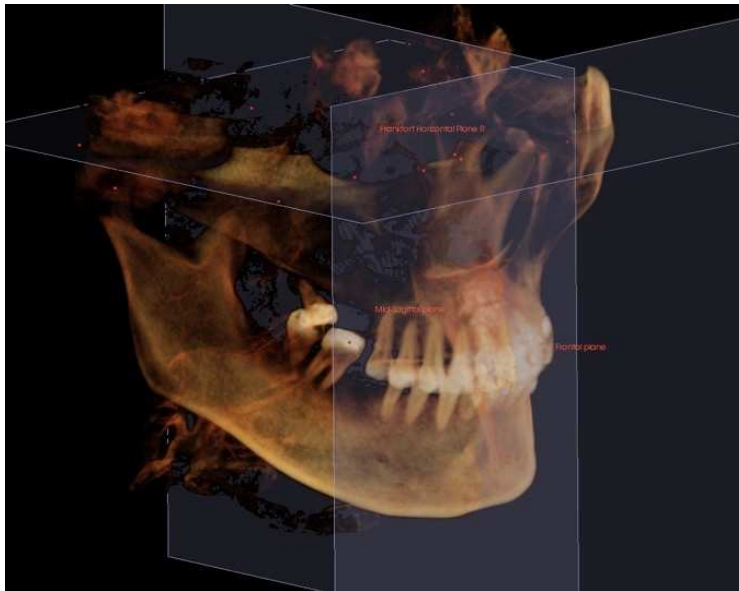

Fig. 5. A cartesian coordinate system was chosen to represent points within the three-dimensional space, with the “N” defined as the origin. (N(0,0,0)) The figure shows the three planes that are perpendicular to each axis. The mid-sagittal plane was defined as the plane that goes through “N” and goes through the line that connects the right and left “Po” perpendicularly. The horizontal plane was defined as the plane perpendicular to the sagittal plane, and goes through the mid points of “Po” and “Or” on both the left and right side. (When defined in this way, this horizontal plane is the same as the Frankfort Horizontal Plane). The frontal plane was defined as being perpendicular to both the sagittal plane and the horizontal plane.

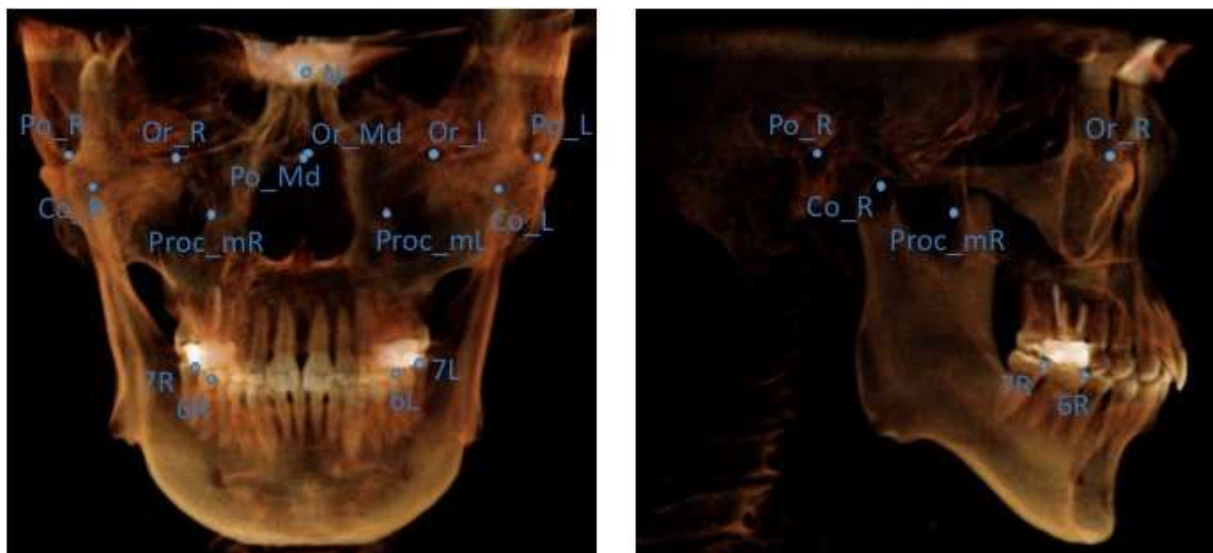


Fig. 6. The points used to determine the FH plane and to take the measurements

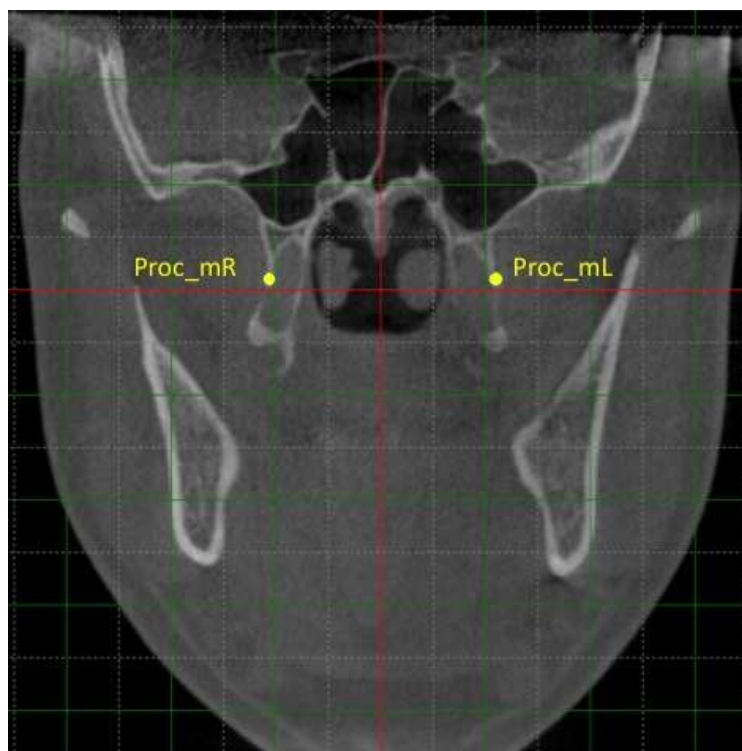


Fig. 7. Setting the reference points for the origin of lateral pterygoid muscle. The reference points were set at the mid-point of the superior margin (where the great wing of sphenoid and pterygoid plate meet) and inferior margin (the end of the pterygoid plate). After the points were set, it was examined and checked using ScaleGrid.

3. RESULTS

3.1. The deformity process model

By changing the position of the food element, an unbalanced biting condition was recreated. The damaging force present during clenching (vertical bruxism) is compressive stress. So, simulating where compressive force is acted upon, in what direction the force is applied, and the duration of the force is meaningful. The maximum principal stress (σ_{\max}) were, in this experiment, of positive value, representing tensile force. The minimum principal stress (σ_{\min}) were of negative value, representing compressive force.

The results were:

(1) Cervical Spine

(i) Minimum principal stress was high in second, third, and fourth cervical vertebra (C2-C4) (Fig. 8c). The forces were particularly high in the anterior part of the vertebral body.

Clinically this may act as pushing the intervertebral disc posteriorly.

(ii) The displacement of the cervical vertebrae was such that it bent at the fifth (C5) and sixth (C6) cervical vertebra, forming a “straight neck” (“V” or “<” shape deformation). This matches with the X-rays from Type B patients (see Fig. 13 and 14 in the clinical findings section for details.)

Looking at the relation between the anterior arch of atlas (C1) and the odontoid process of axis (C2), it can be said that it is anteriorly/posteriorly and superiorly/inferiorly displaced. (Fig. 8c) On the other hand, the results of the “normal occlusion” simulation showed almost no signs of deformation in cervical spine structure (Fig. 8b).

When the loads were applied 500 times instead of 250 in the deformity process model, the curvature of the superior cervical vertebrae matched those of kyphosis patients. This also matches the X-rays of Type C patients (Fig. 13 and 14).

Especially when observing atlas and axis (C1-C2), a major change in the intervertebral gap created by the Anterior atlantoaxial joint and the Syndesmo-dental joint can be observed. The odontoid process moved superiorly resembling a vertical atlanto-axial subluxation (Fig. 10b).

Slipping of the vertebra forward on the adjacent vertebrae, forming a step ladder formation (cervical spondylolisthesis) can also be examined in the inferior cervical vertebrae. This also matches the x-rays of patients.

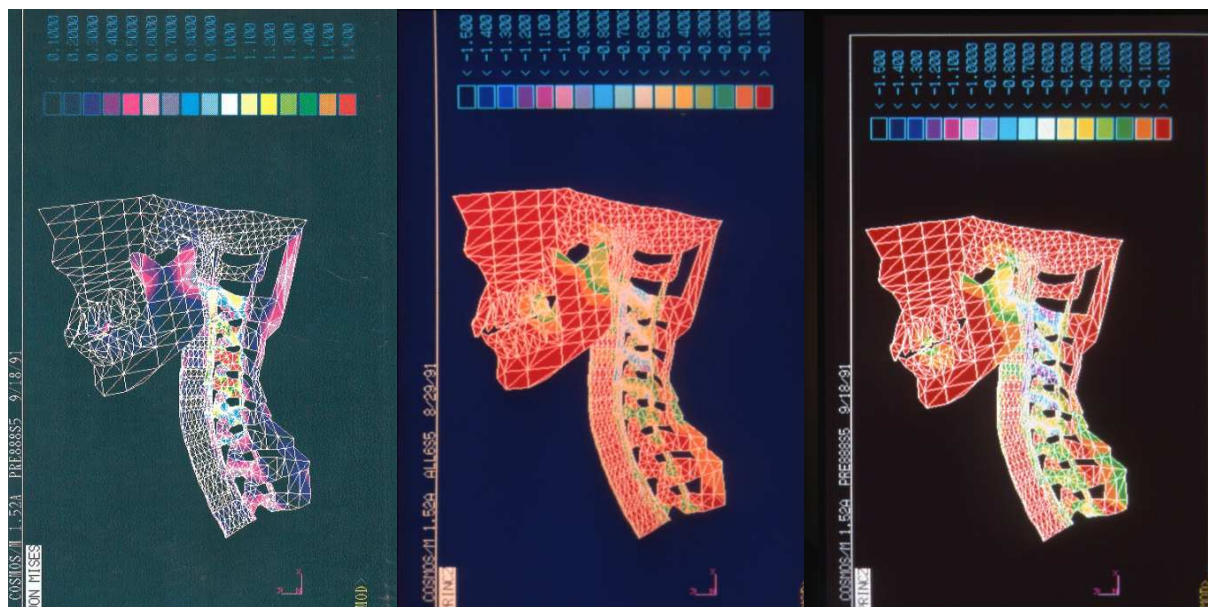


Fig. 8a (left), 8b (middle), 8c (right). Figures showing the results of the deformity process model and normal occlusion model 8a: maximum principal stress of the deformity model 8b: minimum principal stress of the normal model 8c: minimum principal stress of the deformity model

Looking at the enlarged figure (Fig. 10a and 10b), a wedge shaped intervertebral gap of the first to third cervical vertebra (C1-C2-C3) can be observed.

(2) Head Posture (position)

The position of the head inclines forward by 2 degrees compared to the normal occlusion model. This also matches patient X-rays from before treatment.

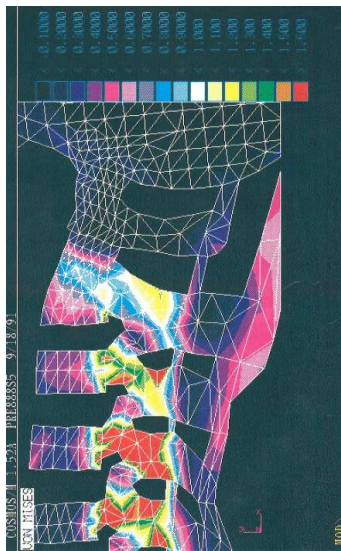


Fig. 9. Results from the deformity process; maximum principal stress. Enlargement of cervical spine portion

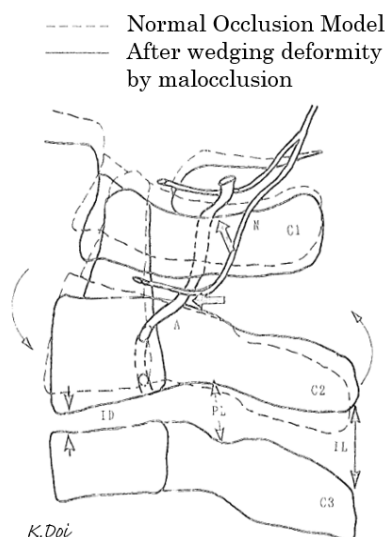
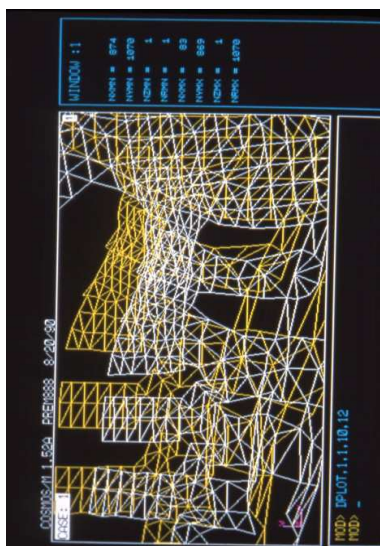


Fig. 10a (left) and 10b (right). 10a: The white line shows the form and position of the deformity process model, after calculations were done 500 times. The yellow line shows the position of the model before the calculation began. 10b: Figure showing wedging deformity of the cervical spine

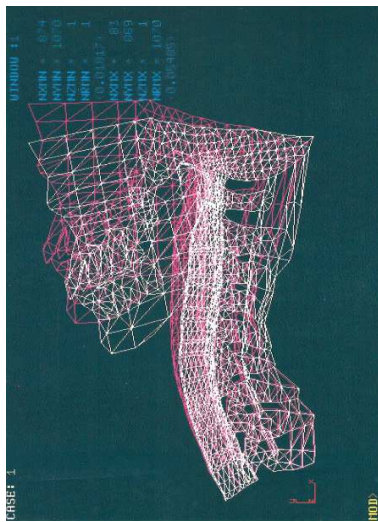


Fig. 11. Figure showing the accumulated displacements of the deformity process model. Red: model forms before displacements were calculated. White: result of the deformity process model (loads applied 500 times). An inclination of the head, and “swan neck”-like appearance of the cervical spine can be observed

(3) Mechanical stress applied to the Temporomandibular joint (TMJ)

In the 250 times model, the forces observed were: less than -0.1 MPa in the occipital condyle, less than -0.1 MPa in the mandibular fossa, and -0.1~-0.2 in the TMJ disk (Fig. 8c). In the 500 times model, the amount of stress to the TMJ increases as and the length of time biting down increase.

In the normal occlusion model, even when the loads were applied up to 500 times, it showed little signs of deformities of (1) the cervical spine (2) head posture and (3) the mechanical stress applied to the TMJ (See Fig. 8b for 250 times calculation).

This shows that when dealing with patient with missing molars, it is advisable to stress the importance of preventing daytime and sleep clenching during health counselling as part of the initial treatment.

3.2. The recovery process model

Using the results from the deformity process experiment, the initial conditions for the recovery process experiment was determined. The state of the neck portion from when the forces were applied 250 times in the first experiment was used to recreate the “diseased” state. Only the head was moved to a normal state, and the “diseased” neck configuration was used to create the initial state of the recovery model. These conditions are equivalent to those

needed to guide the position of the mandible so that it optimize the balance between the mandible and the entire body in a clinical setting. The forces were then applied 500 times on the model to simulate the recovery process.

Recovery stage 1

A 2 mm “food” element was placed only on the occlusal surface of the premolars. The results were as follows:

- (a) Forces applied to the TMJ area reduced by 0.1 MPa. (-0.5 MPa compared to -0.6 MPa in the initial diseased state)
- (b) Stress to the atlanto-axial joint reduced; -0.2 MPa compared to -1.1 MPa of the initial diseased state
- (c) Improvements in the curvature of the cervical spine were observed. The inclination of the head also improved by 1.1 degrees. These results matched the X-rays of patients after they completed stage 1 of the treatments.

Recovery stage 2

Using the resulting model from stage 1, the second stage of the experiment was performed with the following settings. The mandible was moved 2 mm anteriorly and 2 mm inferiorly, and a 10 mm “food element” was placed on the occlusal surface of all teeth. The results were as follows:

- (a) The force applied to the TMJ area became less than -0.1 MPa (the difference between that of the “diseased” state becoming more than 0.3 MPa)

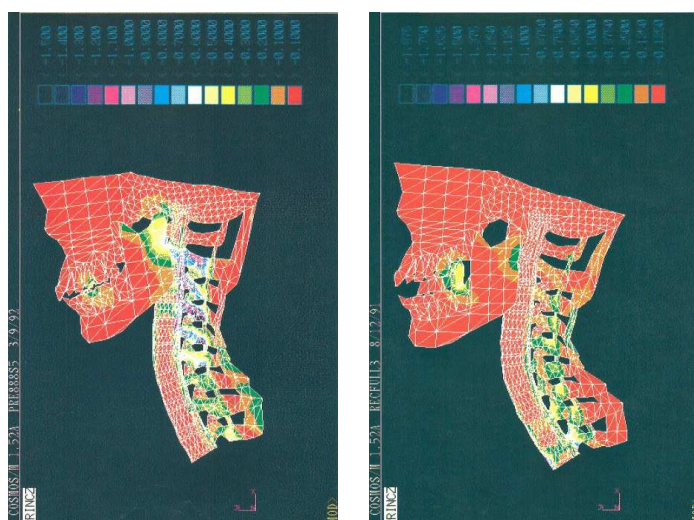


Fig. 12a (left) and 12b (right). Results showing minimum principal stress. 12a: deformity process model (loads applied 500 times) 12b: results of the recovery process model

(b)

* The inclination of the head improved by 4.9 degrees, nearing a normal state.

* When comparing the alinement of the cervical vertebrae in both the deformed/diseased model and the recovered model the following could be said:

(i) In the diseased model, the odontoid process of axis (C2) receives stress of -0.1MPa, with a large amount of the force concentrating on the anterior side of the odontoid process. The stress was high in the superior articular surface of atlas and in the occipital bone stretching from the occipital condyle to a large area anterior to it. (Fig. 12a)

(ii) On the other hand, in the recovered model:

* The odontoid process of axis (C2) receives stress of less than -0.1MPa. In areas of the first to third cervical vertebra (C1-C2-C3) where the vertebral artery and cervical nerves pass thorough, the forces applied were -0.8 MPa. When compared with the diseased model, a decrease in the stress levels on these areas can be observed.

* The relatively high levels of stress on the occipital bone of more than -0.1 MPa in the diseased model, stretching from the occipital condyle to a large area anterior to it, decreased to less than -0.1 MPa in the recovered model.

* The distance between each of the cervical vertebra (C1 to C4) neared the normal state. The cervical spine convexed forward and regained a normal curvature.

* The stress inflicted upon the mandibular fossa of the temporal bone were less than -0.1 MPa, and the force from the mandibular fossa to the temporomandibular joint were less than -0.1 MPa (Fig. 12b).

The stress distribution of the recovered model became close to the original normal model by undergoing recovery stages 1 and 2; the angle of the inclination of the head and curvature of the cervical spine recovering dramatically. The same results can be clearly seen in patients who received treatments based on this model (see clinical findings section), not only by observing their X-rays but by simply through visual examination of the body.

3.3. The results of the MRI and CBCT analysis

The results from the CBCT analysis, and the MRI analysis done prior to the CBCT analysis are shown in Tables 2 and 3.

An initial experiment, involving 30 cases, was performed before any data was accumulated for this experiment. This proved that measurements of the angle between lateral pterygoid muscle and the occlusal plane of molars taken from CBCT images closely matched

those obtained from MRI images and that both were interchangeable for this experiment's purpose.

4. CLINICAL FINDINGS

4.1. Analysis of cephalometric radiographs

The patients visiting the author's private clinic with a chief complaint of systematic general malaise, were asked to fill out a questionnaire with 47 questions about their subjective symptoms and to point out where they feel pain or abnormalities on a figure depicting the head and neck area with 61 questions that could be answered. From the concept that these symptoms arise when mechanical forces are not in equilibrium, the patients were asked to use the Doi Balanced Home Positioner as a therapeutic appliance.

Of the many cases experienced over more than 40 years in practice, I present 13 randomly extracted cases where standardized X-rays of the oral cavity, maxilla and mandible, head and neck was present from both before and after treatment. The cases considered for extraction was those that began before July of year 2003. (The method has since changed, incorporating different examination methods other than cephalometric radiographs. We report the findings of the new method in section 4.2.). The X-rays were examined and analyzed. The clinical symptoms improved in all 13 cases. The results were as follows:

- (1) A displacement of the mandibular condyle within the mandibular fossa was observed in all 13 cases.
- (2) Horizontal deviations in the position of atlas (C1) and the odontoid process (or dens) of axis (C2) were found in 5 out of 13 cases. In 1 of the 5 cases, the head position recovered to an upright state, which caused the skull and atlas (C1) to move posteriorly and the odontoid process of axis to move anteriorly and recover to a normal position. In the other 4 cases, the skull and atlas (C1) moved anteriorly and the odontoid process of axis moved posteriorly to recover to a normal position.
- (3) Vertical deviations in the position of atlas (C1) and the odontoid process of axis (C2) were found in 9 out of 13 cases. In 6 of the 9 cases, the head position recovered to an upright state, which caused the skull and atlas (C1) to move inferiorly and the odontoid process of axis to move superiorly and recover to a normal position. In the other 3 cases, the skull and atlas (C1)

moved superiorly and the odontoid process of axis to moved inferiorly to recover to a normal position.

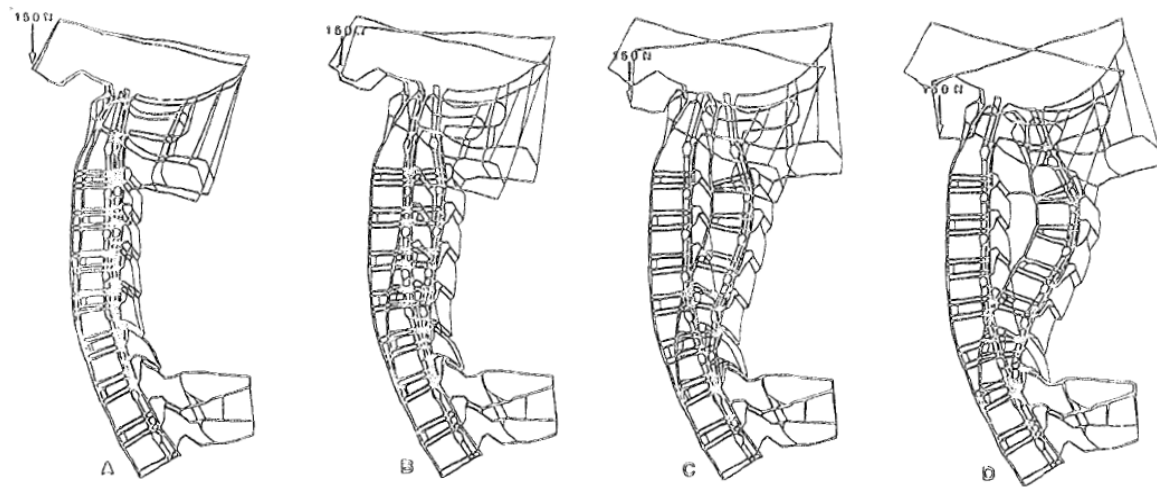


Fig. 13. Results of a simulation model for the kyphotic deformity of the cervical spine following a cervical laminectomy. A, B, C and D represent the deformations of the 1st, 5th, 10th and 14th stage of the iterative simulation [8]

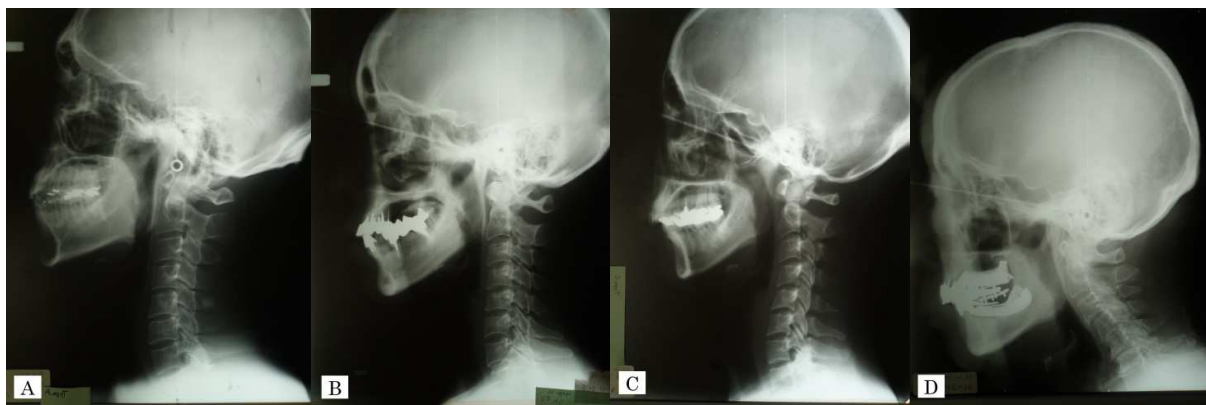

Fig. 14. Cephalometric x-ray of patients. These cases can be classified as A, B, C, and D type cervical spine deformation; A: Normal, B: “Straight-neck” deformation with “V” or “<” Shape bending starting, C: posterior convex, D:” Swan neck”-like deformation. Patients were those visiting Yokohama Yamate Dental Clinic

(4)

(a) The distance between each of the superior cervical vertebrae, composed of atlas (C1), axis (C2) and the third cervical vertebra (C3), and the distance and angle between each of the

spinous processes were observed. A wedge-like appearance was seen in all cases before treatment.

(b) Abnormal cervical spine curvatures (C1-C7) were present in all 13 cases. Changes to the form and location of the cervical spine accompanied by improvements of systematic symptoms of general malaise were observed in all cases after the Doi Balanced Home Positioner was used on the patients.

The improvements as described in (a) and (b) was also observed in the cephalometric evaluations of all 13 cases.

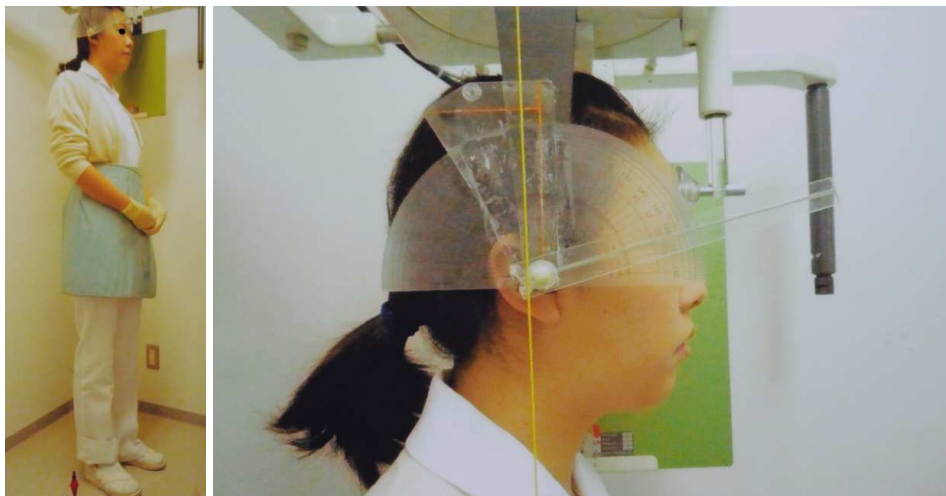

Fig. 15. Conditions when obtaining cephalometric radiographs in this study

The x-rays taken were lateral cephalometric radiographs. A free-hanging plumb-bob was hung from the ceiling. The patient's body trunk was positioned so that the shoulder (acromion), and feet (medial malleolus) align vertically. The string attached to the plumb-bob was used as the reference to do this. The head inclination was also fixed. The inclination of the natural head position was recorded during the initial visit. A protractor fixed on the right ear rod was used to determine the angle of the line that goes through the ear and the outer corner of the eye. An indicator with the line painted with lead paint was used so that the x-ray When taking an x-ray at a later time, the head inclination was adjusted so that this angle would be the same. By doing the above, the head and trunk position would be the same in the x-rays taken before and after treatment. This enables us to examine the isolated changes to the neck.

4.2. CBCT and MRI Analysis

We report the findings from MRI and CBCT images of patients in the tables below.

Table 2. The measurements taken from MRI images of patients: The angle between lateral pterygoid muscle and occlusal plane (right and left). As the difference between right and left angles increased, it was more likely that abnormalities in the lateral pterygoid muscle were present (denoted with a “+” mark)

Pt no.	Sex	Age	Angle between lateral pterygoid muscle and occlusal plane (right) [°]	Angle between lateral pterygoid muscle and occlusal plane (left) [°]	Difference between right and left angles [°]	Abnormality in lateral pterygoid muscle (+): objective symptoms present (-): no symptoms	Remarks
1	F	32	6.34	6.49	0.15	-	
2	F	61	8.2	7.8	0.4	-	Vertebral artery stenosis
3	M	61	1.44	0.96	0.48	+	Occlusal trauma
4	F	24	7.64	8.16	0.52	-	Inflammation present in medial pterygoid m.
5	F	70	2.4	1.5	0.9	+	
6	F	74	10.91	10	0.91	-	
7	M	23	2.4	1.4	1	-	
8	F	66	11.81	10.03	1.78	-	Vertebral artery stenosis
9	M	34	1.1	3.1	2	-	
10	M	60	18.75	16.63	2.12	+	Swelling of the lateral pterygoid m.
11	M	66	9.26	7.08	2.18	-	Vertebral artery stenosis
12	F	69	4.4	2.1	2.3	-	Inflammation present in medial pterygoid m.
13	M	49	5.82	8.34	2.52	-	Inflammation present in masseter
14	F	58	6.25	3.54	2.71	+	Crossbite

Pt no.	Sex	Age	Angle between lateral pterygoid muscle and occlusal plane (right) [°]	Angle between lateral pterygoid muscle and occlusal plane (left) [°]	Difference between right and left angles [°]	Abnormality in lateral pterygoid muscle (+): objective symptoms present (-): no symptoms	Remarks
15	M	66	22.09	18.08	4.01	+	
16	F	72	0.49	4.87	4.38	+	Missing teeth
17	M	50	0.49	6	5.51	+	Swelling of the lateral pterygoid m.
18	F	66	9.9	4	5.9	+	
19	M	69	3.03	9.33	6.3	-	Vertebral artery stenosis
20	F	32	10.76	17.16	6.4	+	Condylar hyperplasia
21	F	65	2.1	8.8	6.7	+	
22	F	68	12.5	5.26	7.24	+	
23	F	26	0.49	8.19	7.7	+	Inflammation present in lateral pterygoid m.
24	F	39	1.09	10.52	9.43	-	
25	F	47	12.14	24.11	11.97	+	Missing teeth
26	F	38	30.9	18.79	12.11	+	Condylar hyperplasia
27	M	20	15.19	1.82	13.37	+	Jaw deformity/ deviation of mandible
28	F	51	34.42	2.74	31.68	+	Jaw deformity/ deviation of mandible
29	F	69	N/A (missing molars)	6.22	N/A	+	Actinomycosis of mandible

Table 3. The measurements taken from CBCT images of patients. The angle between lateral pterygoid muscle and occlusal plane (right and left) were calculated. The abnormal side of the pterygoid muscle matched the side of TMJ with problems in almost all the cases (These are not the same patients from the cephalometric examination). Abnormalities were found in the cervical spine in all 13 cases. The auditory ossicles and airway was also checked for abnormalities

Pt no.	Sex	Age	Angle between lateral pterygoid muscle and occlusal plane (right) [°]	Angle between lateral pterygoid muscle and occlusal plane (left) [°]	Difference between right and left angles [°]	Abnormal Side of lateral pterygoid muscle and occlusal plane	Abnormal side of TMJ	Abnormality of cervical spine	Remarks
1	M	59	16.23	3.92	12.31	R	R	+	Deformity of right condyle, dislocated auditory ossicles
2	F	62	7.56	6.81	0.75	R	R	+	Deformity of right condyle, cervical scoliosis, restricted airway
3	M	54	9.66	15.44	5.78	L	L	+	Deformity of left condyle, dislocated auditory ossicles
4	F	55	2.23	2.61	0.38	L	L	+	dislocated auditory ossicles, restricted airway
5	F	50	7.11	23.48	16.37	L	L	+	Dislocated auditory ossicles
6	F	56	6.63	8.04	1.41	L	L	+	Dislocated auditory ossicles
7	F	52	8.22	19.65	11.43	L	L	+	Restricted airway
8	F	26	10.56	4.68	5.88	R	R	+	
9	F	42	1.09	6.43	5.34	L	L	+	“Straight-neck”/Type B dislocation of cervical spine

Pt no.	Sex	Age	Angle between lateral pterygoid muscle and occlusal plane (right) [°]	Angle between lateral pterygoid muscle and occlusal plane (left) [°]	Difference between right and left angles [°]	Abnormal Side of lateral pterygoid muscle and occlusal plane	Abnormal side of TMJ	Abnormality of cervical spine	Remarks
10	F	73	5.15	5.71	0.56	L	The mandible is dislocated to the left and the right condyle is dislocated posteriorly	+	
11	F	52	5.81	9.1	3.29	L	L	+	
12	M	39	4.32	2.85	1.47	R	R	+	Deformity of right condyle
13	M	69	9.5	9.95	0.45	L	L	+	

4.3. Clinical Case 1

We aim, not only to improve the masticatory function and dental esthetics of patients, but also to profoundly improve facial features, widen the airway, recover from diseased postures and improve head position. We also aim to see fundamental recovery from TMD and CCD, resulting in improvements, not only in the oral and facial area, but also the whole body. In this patient, (1) improvements to the inclination of the head, (2) improvements to the asymmetric facial features (Fig. 16.), (3) recovery to the normal curvature of the cervical spine, and (4) Recovery of symptoms of general malaise were observed.

The initial stage (stage 1) of the splint therapy (Fig. 18.). The objective of this stage in treatment is to obtain balanced mandible, head, and cervical spine position. After such balance is obtained, appropriate occlusal plane, the vertical dimension of occlusion, tongue space, and airway is considered and adjusted if necessary in stage 2. In stage 2, we aim to achieve a symmetrical maxillary and mandibular occlusal plane based on the mandibular position obtained in stage 1. The Doi Positioner used in this stage is the No. 3 Splint (Fig. 19.). The new criteria for doing so involves looking at (1) The balance of the lateral pterygoid muscle (2) The balance of the upper cervical vertebrae, (3) Head position and (4) changes to the TMJ

position. After the adjustments are made and symptoms are relieved, a No. 4 Splint is fabricated to finalize the adjustments.

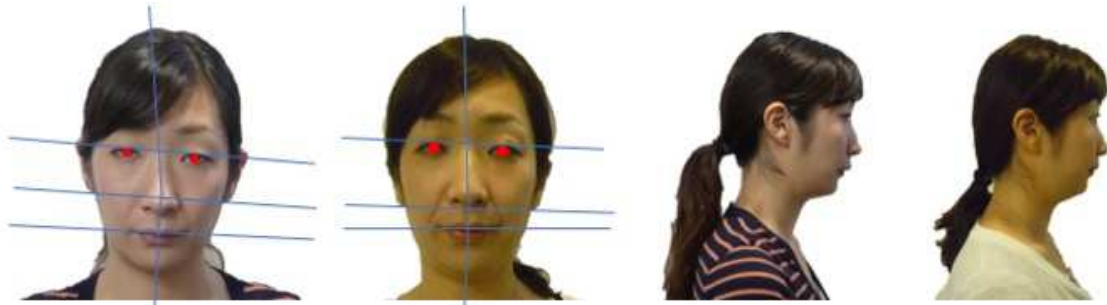


Fig. 16. Improvements to the facial features of patient. Improvements to the asymmetric facial features were observed. The reference lines (going the left and right upper margin of the eye, the lower margin of the ear, the corners of the mouth) became more parallel to the floor

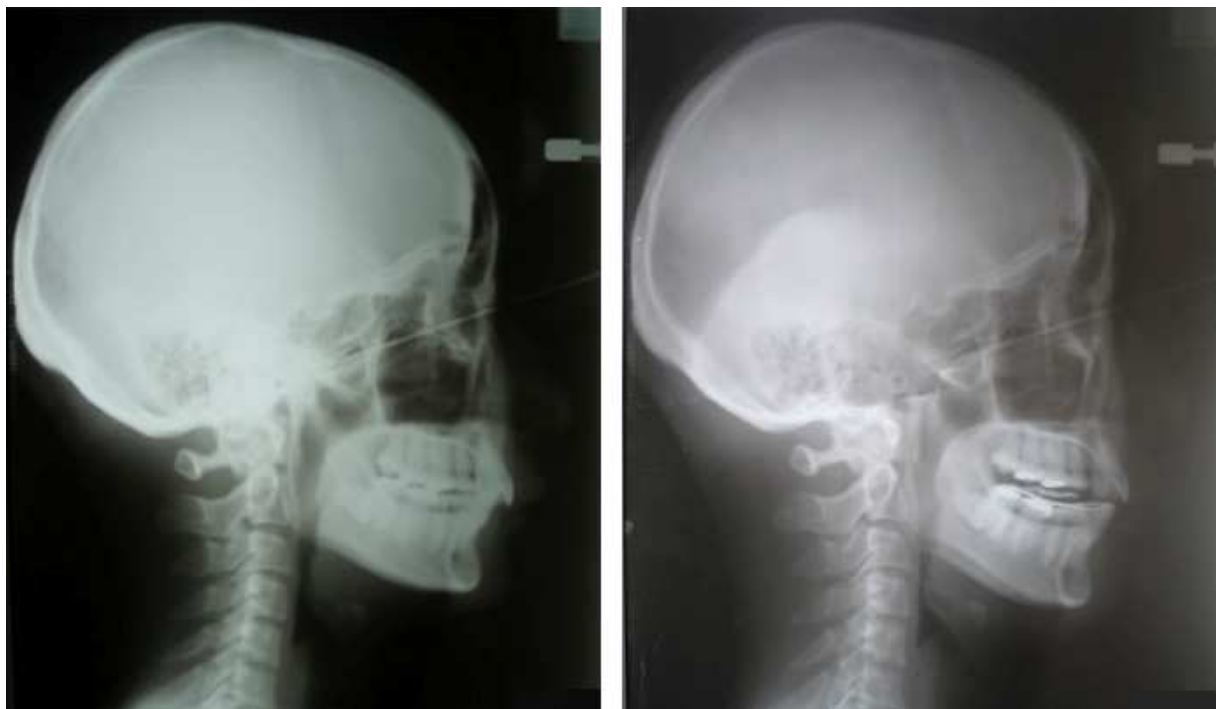

Fig. 17. Cephalometric X-ray of patient from before and after the insertion of Doi Balanced Home Positioner. Left: Before the insertion. The cervical spine below C4 is curved but C3 to C1 is in a straight orientation. This is a “straight-neck” or Type B cervical deformation (Fig. 13 and 14). Right: After the insertion. The use of the Doi Balanced Home Positioner improved the cervical spine. The patient is beginning to regain a normal curvature of the cervical spine

In the treatment described above, the motion vector of occlusal force is determined by the direction of muscle fibers of muscles. This is due to the fact that muscular force is the main source of power in living organisms. While the importance of the centric relation has been stressed by many clinicians, we think this alone is not enough. We are proposing here that the mandibular position should be determined by the balance of biomechanical forces.

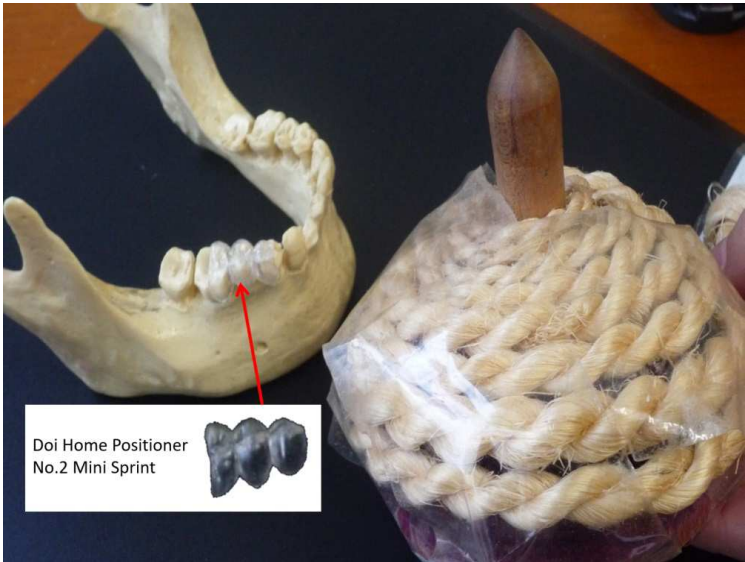


Fig. 18. No. 2 Mini Splint used during the initial stage of the splint therapy

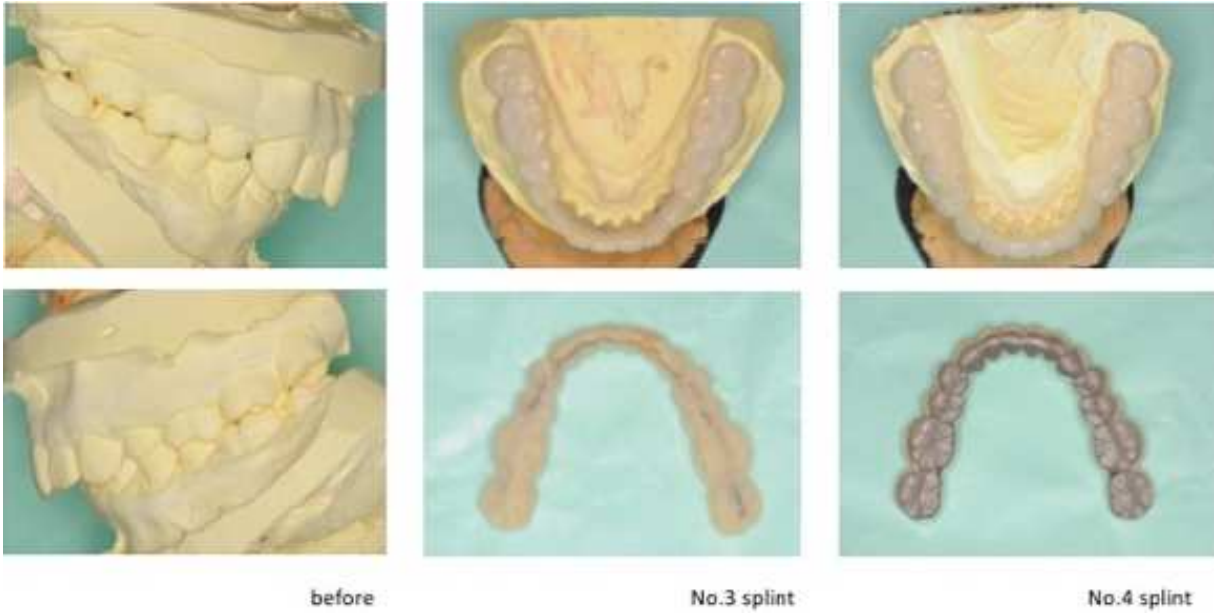


Fig. 19. Left: The study casts taken before treatments. Middle and Right: The splints used in each stage of therapy

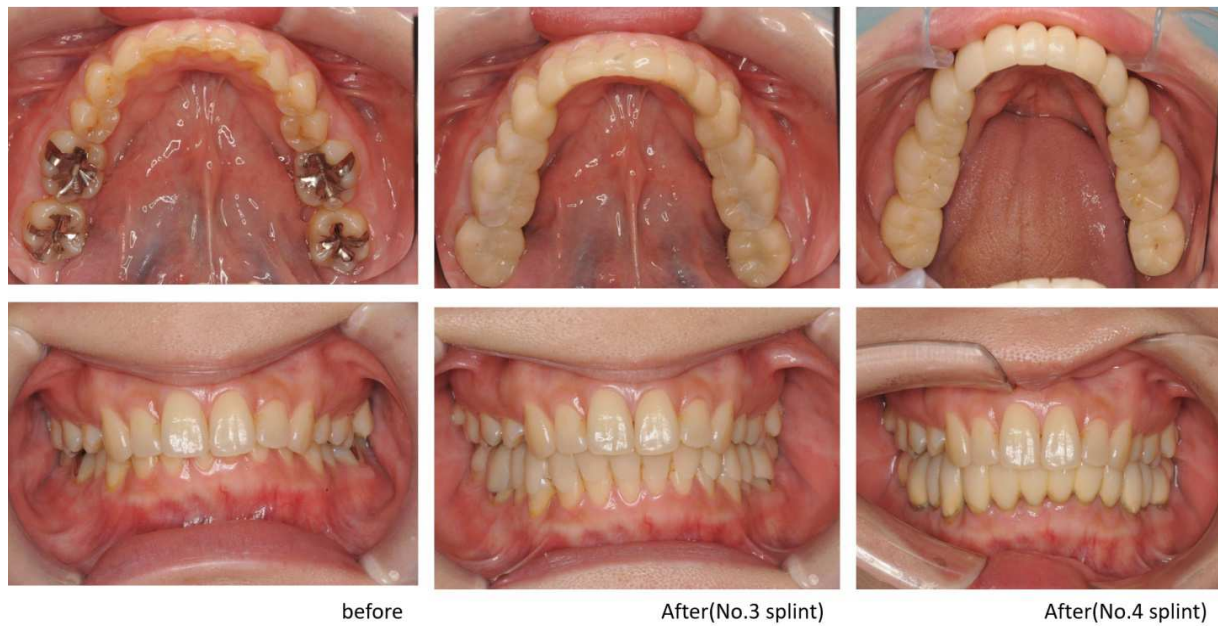


Fig. 20. The intraoral photographs taken at each stage of therapy

4.4. Clinical Case 2

The biomechanical analysis of the pseudo-3D model of the deformity and recovery model was performed using FEM as shown in the results section. In this section, actual clinical data will be examined and compared to the results from of the biomechanical model. The model suggests that an imbalanced contact of maxillary and mandibular teeth affects the position of the mandible and head, and form of the cervical spine, which in turn affects posture. There have been no reports of diseased postures occurring in this way and the CBCT images of such patients, suggesting a relationship between parafunction (unbalanced clenching or grinding) and TMD or CCD.

Table 4. The occurrence of unbalanced position of the mandible and the damaging effects of parafunction that can be caused

-
1. Deformation and dislocation of TMJ
 2. Deformation and dislocation of the cervical spine
 3. Deformation and dislocation of the vertebral artery resulting in transient ischemic attack (TIA)
 4. Changes in the position of the head
-

The changes described above, causes changes in the position of the mandible, which in turn causes malocclusion and parafunction. This may lead to the following:

1. Occlusal vertical dimension loss
2. Missing posterior teeth
3. Abnormal position of maximum closure stop
4. Abnormal anterior guidance in dentition
5. Abnormal premature occlusal contact during the jaw movement
6. Facet of bruxism
7. Changing of the jaw rest position
8. Abnormal dental arch

During sleep bruxism, muscles responsible for both adduction and abduction of the jaw come into play. The relationship between the maxillary and mandibular molars is involved in how the mandible is guided.

There may be a relationship between the eruption direction of the maxillary and mandibular molars and the direction of gravitational force. The angles between the occlusion plane of the molars to the lateral pterygoid muscle is maintained almost parallel to each other. The maxilla grows and develops earlier compared to the mandible. So relatively speaking, the maxilla moves backwards and upwards while the mandible moves forwards and downwards. After the eruption of the molars, the occlusion plane angle of the molars may play a vital role in how the maxilla and mandible “moves” in relation to each other as they grow. Furthermore, in some patients, it can be observed that when the mandible is guided to a posterior position (retraction of the mandible), the mesiolingual incline of the distobuccal cusp of the upper molars may play a role in guiding the mandible. The mandible will be guided along this plane posterosuperiorly, both to the upper right and upper left (This could be considered as equivalent to the working side and balancing side during lateral excursion. While it is possible to retract the mandible simply backwards, it may be important to note that there is a degree to which the mandible can be guided slightly to the right and left).

Also, during sleep bruxism, horizontal parafunction is mainly caused by contraction of the lateral pterygoid muscle, moving the mandible forcibly backwards. This parafunction causes CCD, which includes the dysfunction of the temporomandibular joint (TMD). It can be suspected that when this occurs, the molars, especially the mesiolingual incline of the distobuccal cusp of the upper molars, causes the mandible to stop moving backwards. This suggest that it is important that the occlusal plane is parallel to the lateral pterygoid muscle especially during bruxism.

It is important during occlusal adjustments, to treat patients so that non-physiological bruxism does not occur. In our clinic, we aim to alter the occlusal plane so that it becomes parallel to the lateral pterygoid muscle.

We have reported the angle between lateral pterygoid muscle and occlusal plane of patients in a table (Table 2). Those patients with a great difference between the angles (right and left) were more likely to have symptoms of TMD or CCD. As the difference in the left and right angles between the occlusal plane of the molars and lateral pterygoid muscle increases, the stronger the symptoms become. These symptoms are more likely to occur on the side with the larger angle. The anterior/posterior position of the condyle in relation to the mandibular fossa is especially important. In such cases, the face becomes asymmetrical (in relation to the left and right “Po”). These unbalanced positions also affect the cervical spine.

Next, we will closely examine one case where there were symptoms on the left side. The patient is a 70-year-old male. His chief complaint was that he experienced dizziness; vertigo upon waking up, and dizziness (non-vertigo) after bathing. This patient was examined by an otolaryngologist, but no problems were found. He also reported that he had missing teeth and he had trouble biting. He was also experiencing discomfort in the left temporomandibular joint. The patient’s medical history includes epimacular membrane (left), prostatitis, prostatomegaly, hypertension, and dyslipidemia. Silodosin, Dutasteride, Amlodipine besilate were taken regularly by the patient. We report the findings as follows:

This patient had abnormalities in the left side and the left condyle is positioned 3 mm posterior in relation to the right condyle. An asymmetrical face was observed. The cervical spine was also affected (Fig. 26b). Cervical scoliosis was also observed (Fig. 26a). This suggests that the right vertebral artery is deviated relative to the left vertebral artery. This could be considered the cause of the constriction of the vertebral artery which was also observed (Fig. 27a and 27b). Also, when seen from the sagittal view, a nonphysiological “straight-neck” curvature of the cervical spine can be observed. Furthermore, the Atlanto-Dens Interval (ADI) decreased and can be considered a horizontal subluxation of the odontoid process of axis (C2). A vertical subluxation between atlas (C1) and axis (C2) was also observed.

The airway was also analyzed. When considering the horizontal cross-sections of the airway, the area was smallest in the area near axis (C2).

In this way, TMD and CCD affects the whole body. It can also be speculated it also affects the brain due to possible reduction in blood flow.

In summary, abnormality in the left side affected the right cervical vertebrae and right vertebral artery.

1. The effects of TMD and CCD are not limited to the oral area, and it affects the whole body
2. Vertigo experienced by the patient could be thought of as cervical vertigo caused by diseases such as TMD and CCD. One of the causes of TMD and CCD is malocclusion.

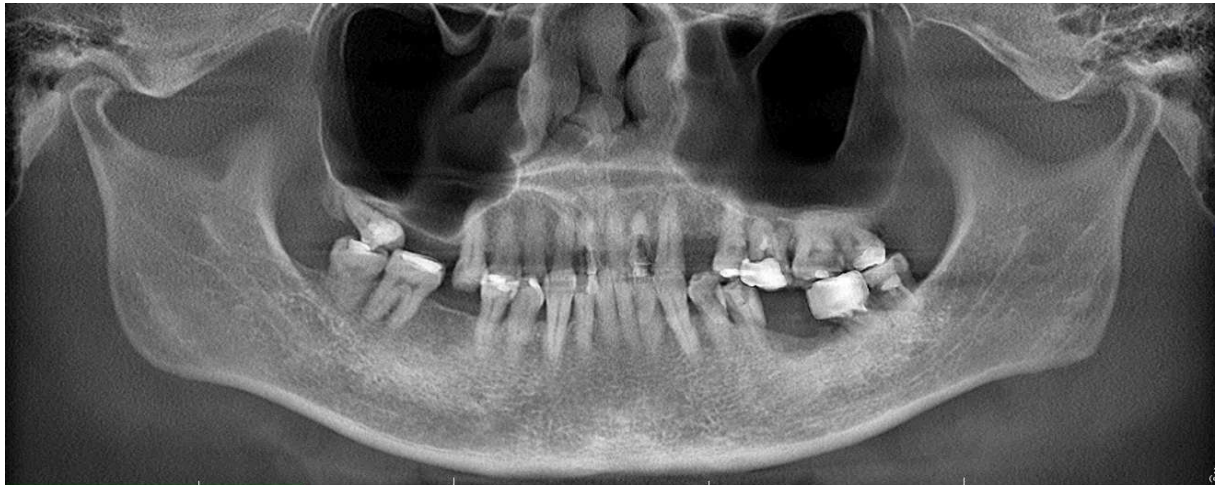


Fig. 21. A CBCT image of the Patient, shown in panoramic mode. The CBCT was taken during the initial visit. A great difference between the right and left the occlusal plane of the molars can be observed

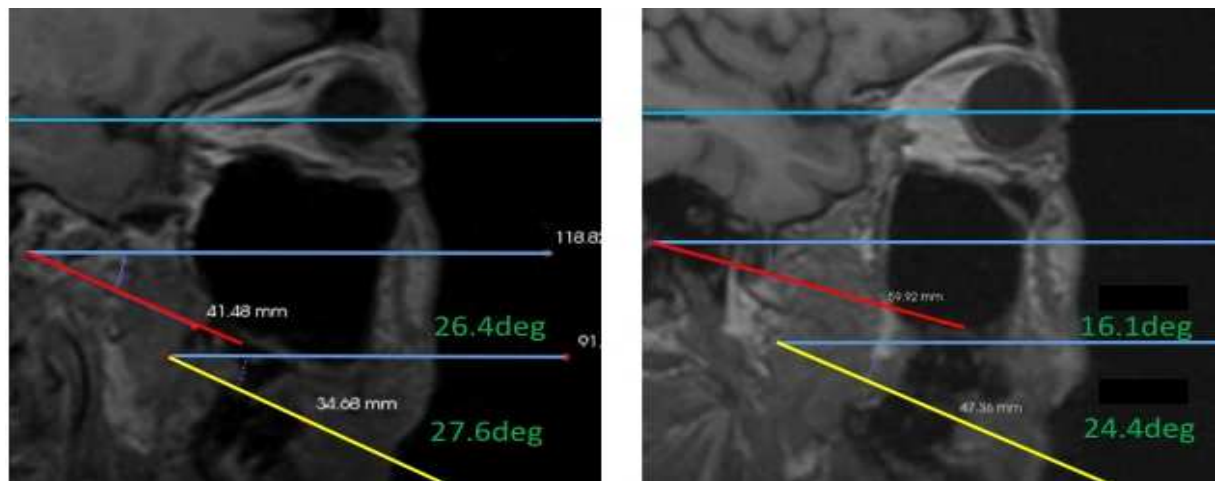


Fig. 22a (left) and 22b (right). MRI image of patient. Shown above are the angles measured; the angle between the FH plane and the lateral pterygoid muscle, and the angle between the FH plane and occlusal plane. Fig. 22a shows the left side and Fig. 22b shows the left side. The angle between lateral pterygoid muscle and occlusal plane was larger on the left side, compared to the right side, by 7.1° . The patient had symptoms on the left side

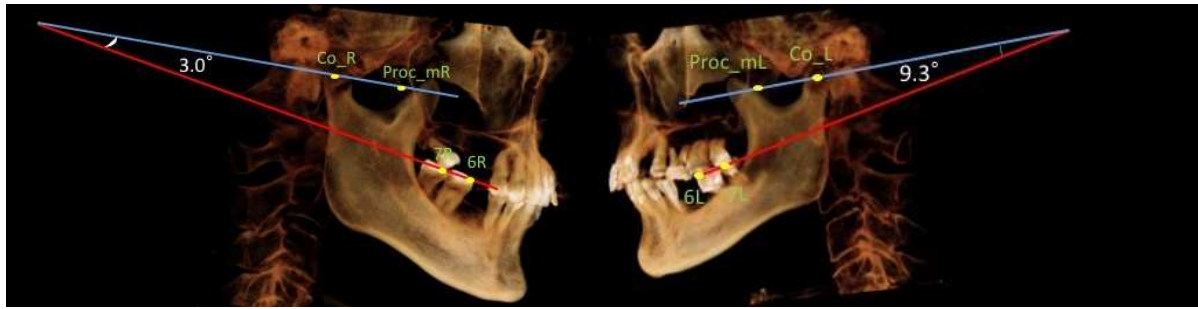

Fig. 23a (left) and 23b (right). The angle between the lateral pterygoid muscle and occlusal plane. Left: Showing the measurements taken on the right side Right: Showing the measurements taken on the left side

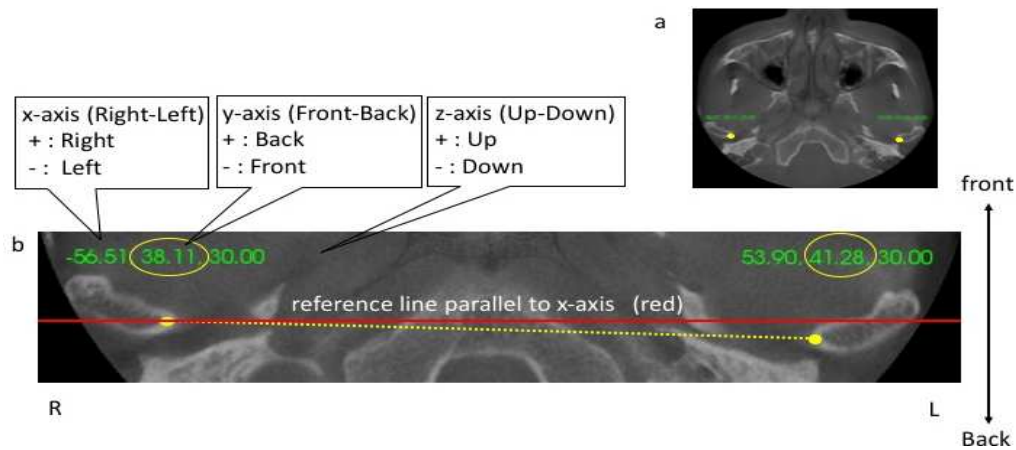


Fig. 24a (upper right) and 24b (below). The figures show an axial cross- section of CBCT images. Fig. 24b is an enlarged figure of Fig. 24a. The figures show that the left (affected side) condyle (41.28 mm) is positioned nearly 3 mm posteriorly, compared to the right (unaffected side) condyle (38.11 mm)

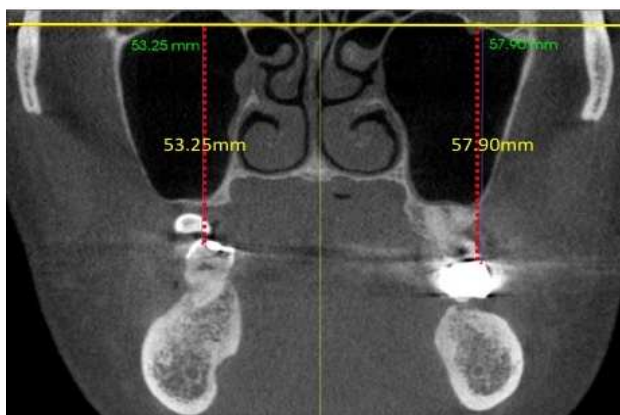


Fig. 25. The figure shows a coronal cross-section of a CBCT images. The “Or” on both sides was used to create a reference line. The length from this line to the mesio Buccal cusp of the first lower molar was measured. The measurements were taken on both sides. The left first molar is positioned about 4.7 below the right first molar. This indicates that the two are not parallel to each other

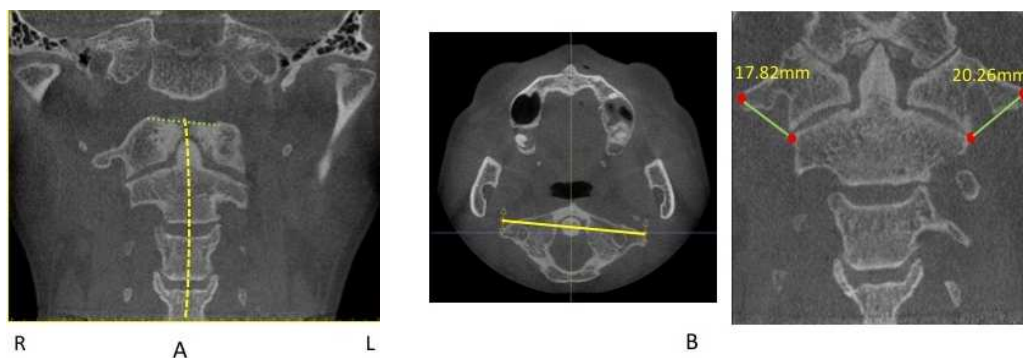


Fig. 26a (left) and 26b (right). A: cervical scoliosis was observed, B: The distance between C1 and C2 was 2.44 mm shorter on the right side

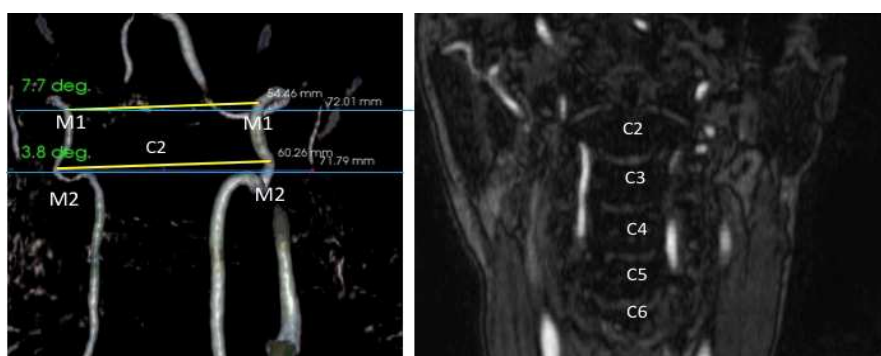


Fig. 27a (left) and 27b (right). The comparison of the left and right vertebral artery. The right vertebral artery is apparently thinner than the left vertebral artery. The M1 (as shown in Fig. 27a) of the right side is positioned lower than the left M1. The angle between the line that runs through left and right M1 and the reference line was 7.7° . Also, the M2 of the right side is positioned lower than the left M2. The angle between the line that runs through left and right M2 and the reference line was 3.8° . This suggests that the right vertebral artery is deviated relative to the left vertebral artery. This could be considered the cause of the constriction of the vertebral artery

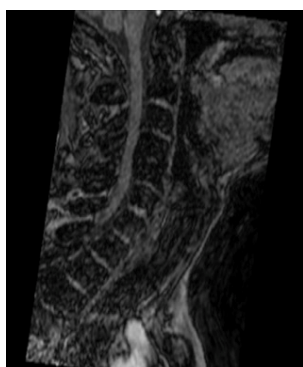


Fig. 28. An MRI image of the cervical spine area. A “straight-neck” style deformation can be observed. Using the classification from Fig. 14, this can be considered what we call type B deformations

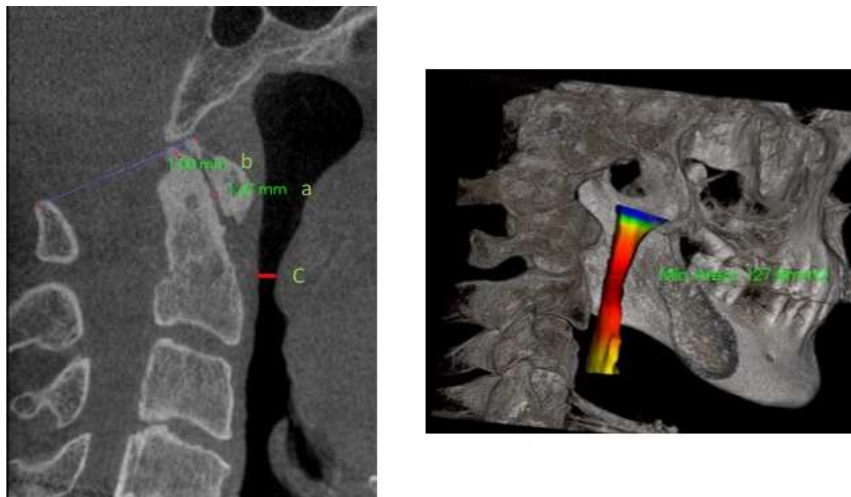

Fig. 29a (left) and 29b (right). The figure depicts the following a: Atlanto Axial distance (the horizontal distance between the anterior aspect of the odontoid process (C2) and the posterior aspect of the anterior ring of the atlas (C1)) b: The vertical distance between the odontoid process and the posterior aspect of the anterior ring of the atlas c: The section of the airway where it becomes most narrow. The area of that section was calculated.
 a: 1.47 mm (horizontal subluxation; the ADI is smaller than average) b: 1.00 mm (vertical subluxation) c: 127.8 mm² (Restricted Airway)

4.5. Clinical Case 3

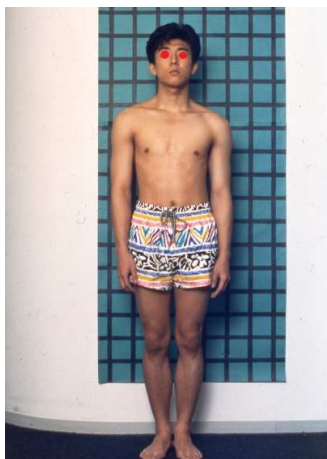

Fig. 30. The figure depicts the posture of the patient as seen from the front side. The head position (center of gravity) is deviated to the right side. The mandible is deviated to the left side and posteriorly and superiorly. Cervical and thoracicscoliosis was also observed. The eyebrows, eyes, angulus oris on the left side is positioned higher than that of the right side. On the other hand, the right side of the pelvis is positioned higher than the left side. The outward bowing of the right leg can be observed, with the right foot abducted pointing outwards

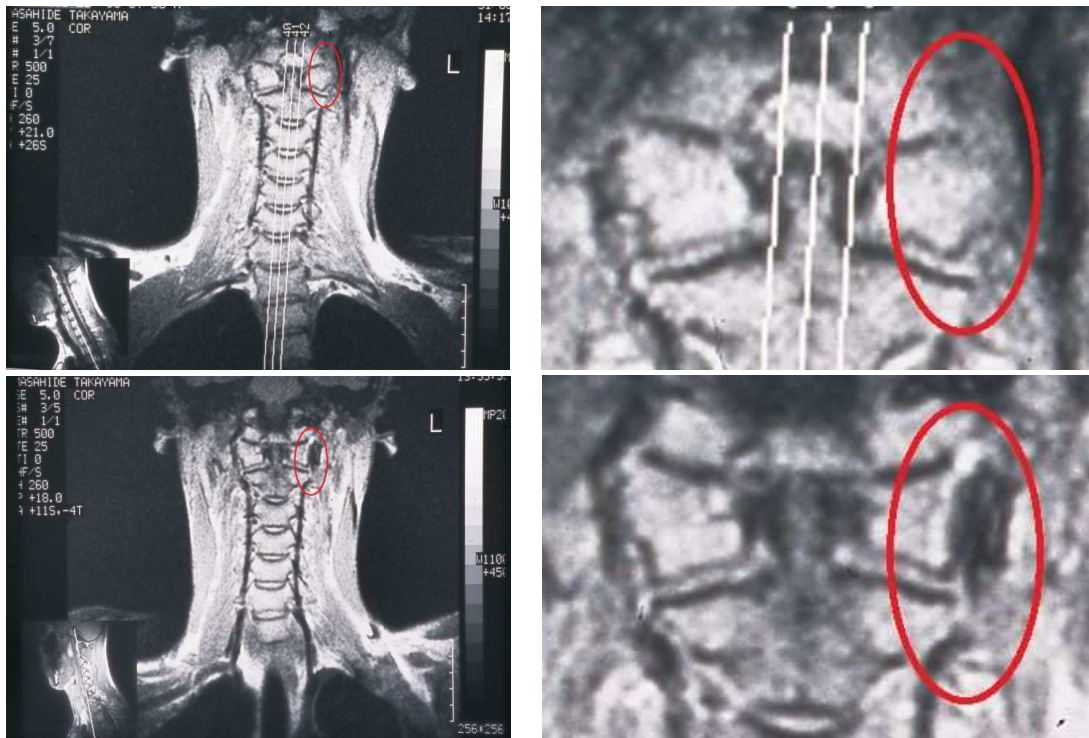


Fig. 31a (top) and 31b (bottom). a: Contrast-enhanced MRI image taken before treatment. The left vertebral artery going into the base of the brain is not apparent. b: Contrast-enhanced MRI image taken after Doi Home Balance Treatment. The left vertebral artery going into the base of the brain can be seen

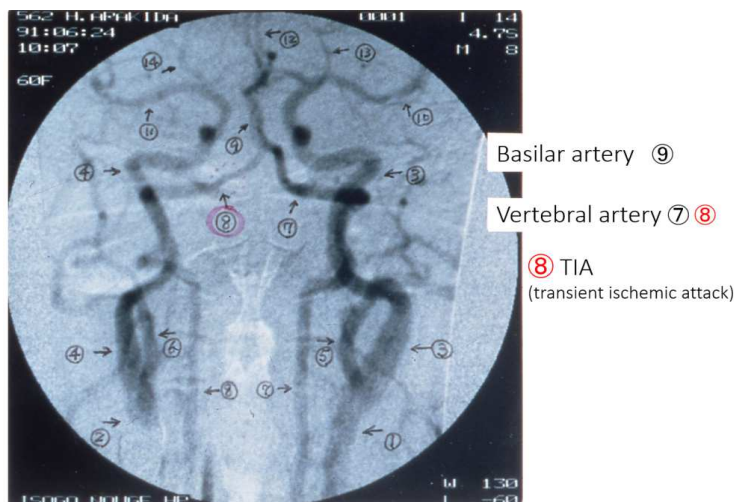


Fig. 32. DSA of the vertebrobasilar insufficiency

Furthermore, MRIs were taken to see the changes in the vertebral artery to assess the success of the treatment. Clinical improvements of the symptoms occurred as changes were observed in the MRI images. (MRI images were taken as needed to evaluate the effect of the treatments.)

5. DISCUSSION

(1) The results of the treatment using the Doi Balanced Home Positioner matched those of the simulation experiment. The improvements of the configuration of the cervical spine, especially the intervertebral gap between the first 3 cervical vertebrae (C1 C2 and C3), where the vertebral artery runs through, seem to play a major role in the improvements of symptoms. When the vertebral artery is compressed due to the dislocation of the cervical spine, a reduction of blood flow to the brain and/or embolism of peripheral vessels may occur. In other words, transient ischemic attack (TIA), stemming from problems in the dental area, may cause clinical symptoms such as vertigo, headaches and pain in the shoulders and neck. Also, high compressive forces can cause mechanical stress to the nerve roots. This may cause sympathetic nervous system malfunction in the cervical ganglia; numbness of fingers, pain in the facial/cranial area and the neck, and cervical spondylosis. The results of the experiment show that the forces concentrating on the anterior part of the vertebral body which may push the intervertebral disc posteriorly resulting in cervical disc herniation. Clinically, this may be observed as the worsening of neurologic symptoms. This is in accordance with the fact that the head posture changes over long periods of time.

(2) The inclination of the head position is referred to as some in the medical field as thoracic outlet syndrome (or *utsumuki shoukougun* in Japanese, literally meaning “head inclined posture syndrome”). It can also be considered to be Cervical Neuro Muscular Syndrome. The characteristic symptoms of these diseases include muscle contraction headaches, shoulder and neck pain, and in severe cases, pain in the back of eyes. The biggest cause of this is the head-inclined posture. Patients experienced improvements in their symptoms as their head posture was corrected by using the Doi Balanced Home Positioner. This is consistent with the recovery of the head posture from the experiment model.

(3) On the horizontal and vertical relationship of atlas and odontoid process:

The horizontal relationship between atlas (C1) and the odontoid process of axis (C2) are typically described by using the atlanto-dens interval or ADI. ADI is defined as the distance between the anterior aspect of the odontoid process and the posterior aspect of the anterior ring of the atlas. An unbalanced ADI to posterior atlanto-dens interval (PADI) ratio may cause compression of nerves. So, it can be said that it is desirable that the space between atlas and the odontoid process of axis be within normal limits. There were 5 cases (see section 4.1. Analysis of cephalometric radiographs) where the horizontal changes to the configuration

of atlas and axis were seen after treatment. It can be speculated that the compression of nerves and blood vessels, due to the horizontal displacement of atlas and the odontoid process (horizontal atlanto-axial subluxations), were one of the cause of the clinical systematic symptoms of CCD.

On the other hand, vertical displacement of atlas (C1) and the odontoid process of axis (C2) (vertical atlanto-axial subluxations) may also cause clinical discomforting symptoms. If the odontoid process deviates upwards, it may cause physical compression of the medulla oblongata, base of the brain, or the vertebral artery which in turn may cause all kinds of diseases including TIA. In the 6 out of 13 cases considered in this study (see section 4.1 Analysis of cephalometric radiographs), where a decrease in the vertical distance between atlas and odontoid process were observed, the patient might have showed signs of CCD because of this. In 3 of the 13 cases, an increase in the vertical distance between atlas and odontoid process were initially observed. A decrease in this distance was observed along with the recovery of patients. In these patients, their symptoms may have been caused by horizontal displacements of the atlas and axis. As the atlas and axis rotated, regaining normal ADI, the vertical distance decreased. So, in these cases, symptoms of patients may have been caused by horizontal atlanto-axial subluxations.

(4) In the simulated experimental model, the Doi Balanced Home Positioner decreased the compressive stress on the temporomandibular joint region. In clinical situations, the appliance relieved clinical symptoms. It was especially effective on patients who suffered from unrestrainable sleep bruxism. The appliance was effective, not only on the temporomandibular joint region but also on the joints between each cervical vertebra, making it possible to be “physiologically harmonious” with each other, biomechanical stress dispersed evenly. Pain is said to account for 66% of all symptoms associated with the temporomandibular joint, and the Doi Balanced Home Positioner seems to be effective to these pains. The results from the simulation experiment support this.

(5) Biomechanical unbalance may cause stress to patients. This psychosomatic stress may affect (1) the hypothalamus which may in turn affect the autonomic nervous system and the endocrine system of the pituitary gland. It is also easy to speculate that this stress also affects the (2) endocrine and immune systems. Some patients using the Doi Balanced Home Positioner also showed signs of improvements in symptoms caused by the malfunction of endocrine and/or immune system.

6. CONCLUSIONS

(1) The function of the system composed of the jaw, face, skull and cervical spine is retained when biomechanical forces are in balance. The biomechanical computer simulation made it clear that mechanical forces play a major role in the occurrence and recovery of maladies caused by the imbalance of such forces and further verification was needed. The results from the simulation experiment matched the results of the countless clinical cases experienced over the course of more than 40 years especially when compared to the results of CBCT analysis.

(2) The results from this experiment proved that, in clinically common cases where missing molars and the lack of vertical contact of anterior teeth (maxillary anterior labial flaring) are observed, clenching of the premolars acts as a para-functional force, causing biomechanical imbalance between the jaw, face, skull, and cervical spine. This imbalance causes the dislocation and deformation of the cervical vertebra, temporomandibular joint and occipital condyle which in turn cause the forward inclination of the head. This change in head position may affect all the organ systems of the body, causing a biomechanical imbalance of each system it composes. The head, weighing approximately 5 to 8 kg, is a component positioned farthest from the ground. When the head inclines forward, it causes the center of gravity to change, causing the body to form a diseased posture. The simulation experiment suggest that this diseased posture gets worse over time; the affects amplifying under the repetitive influence of gravity. This posture may change the configuration of bones from all over the body causing its function to collapse. The disease, caused by the collapse of balance in the head and neck area, may affect many organs, causing symptoms, known as general malaise due to its unknown etiology.

(3) The results from the simulation experiment matches the results from clinical treatments, which shows that the Doi Balanced Home Positioner is effective in both theory and in practice, and why it is effective. (Fig.16 and 17) The appliance used in stage 1 of treatment is a mini-splint, covering only a part of the mandibular arch. The “food” element in the simulation experiment or the appliance used in treatment can be regarded as an exercise (balance) ball / spinning top -like object placed between two planes; the occlusal plane of the maxillary and mandibular arch. With the “ball” placed in between, the maxilla and mandible moves cooperatively, autonomously, without major constrains. In the process, the two becomes biomechanically balanced. In both theory and in practice, the forward inclination of

the head and its center of gravity begins to normalize through this process. To amplify this effect, a second balanced positioner, a full coverage splint, is applied to the patient in stage 2 of the treatment. The position of the mandible creates a self-stabilizing mechanism with the maxilla which is joined to the cranium. This oral appliance has stabilizing and balancing effects to the whole body. In the experiment, the diseased model returned to a normal state. Clinically, improvements in symptoms were seen. In other words, symptoms of unknown etiology improved by breaking the negative cycle, stemming from impaired form, force, and function, created by an imbalanced oral system. The negative cycle was broken by the autonomous reconfiguration of the mandible, creating a positive cycle.

(4) If clinical and experimental facts match, accompanied by many improvements in symptoms, the series of symptoms should no longer be considered to be “general malaise”. It would be possible to specify and differentiate these symptoms as symptoms of “Unbalanced oral system syndrome” (CCD and TMD. See Fig. 1.), and should be reclassified as such. In the tenth revision of International Statistical Classification of Diseases and Related Health Problems (ICD-10), there is no classification of a disease which corresponds to general malaise. It can be speculated that it is not considered to be a single disease, but rather, a series of symptoms that are unrelated to each other. But, when taking the matching results from the recovery model and clinical treatments into consideration, it seems that this should be considered one disease.

An advancement in medicine in a holistic way should be accomplished by cooperation of both medical and dental experts.

Finally, we would like to question the assumption that the centric relation is the standard for mandibular position. In October 2016, the Academy of Prosthodontics came to an agreement on single definition of centric relation which was both controversial and divisive. But we would like to urge reconsideration on treatments based on centric relation.

In the author’s perspective, it is important to consider gravity as a means to decide the best mandibular position. The mandible should be positioned so that the body can balance the weight of the head. This can be considered the standard for mandibular position, a gravitational relation of the mandible to the head. Treatments in clinical settings should be performed taking into account the effects of force on bone and other components, 1. biologically, 2. biomechanically, considering 3. patient specific factors, and the change to bone over time.

We hope that the Doi Home Position Theory will be of great benefit to clinicians and patients around the globe.

ACKNOWLEDGEMENTS

The author wishes to thank patients who volunteered to take part in this study. Also, the author would like to thank Dr. Tige Fukuda, Shohei Hasegawa, and the other members of Yokohama Yamate Dental Clinic.

REFERENCES

1. Tsutsui S. Examining psychosomatic diseases [in Japanese]. Life Science Publisher, 1985.
2. Hasegawa N. Psychosomatic diseases in the field of gynecology [in Japanese]. Kalahari Publisher, 1965.
3. Information Department, Ministry of Health, Labor and Welfare of Japan. Year 2000, The state of households shown in graphs, 2000.
4. Saika M, et al. Clinical study about the treatment of atlanto-axial subluxation. Clinical Orthopedic Surgery, 1989.
5. Kaufman RS. Case reports of TMJ repositioning to improve scoliosis and the performance by athletes. New York State Dental J. 1980; 46(4): 206-209.
6. Doi K, Tsutsumi S. Pseudo-3D finite element analysis for pathogenesis and development of cervical spine deformities caused by malocclusion. Trans Int Congress on Dental Materials. 1989, pp. 229.
7. Tsutsumi S, Doi K. Pseudo 3D computer simulation for pathogenesis and rehabilitation of cervical spine deformity by malocclusion. Int J Indust Ergon. 1992; 9: 137-144.
8. Saito T, Yamamuro T, Shikata J, Oka M, Tsutsumi S. Analysis and prevention of spinal column deformity following cervical laminectomy, Part I, and Part II. Prevention of juvenile postlaminectomy deformity. Spine (in print), 1990.

Lifestyle and relationship with periodontal disease

3

**Gaitán Fonseca Cesar¹, Araujo Espino Roxana²,
Aguilera Galaviz Luis Alejandro¹, Trejo Ortiz Perla²,
Correa Alcalde Teresina¹, Frias Muñoz Maribel³**

¹ Docente-investigador, Maestría en Ciencias Biomédicas, Área Ciencias de la Salud, Universidad Autónoma de Zacatecas “Francisco García Salinas” (UAZ), Campus UAZ Siglo XXI, Carretera Zacatecas-Guadalajara Km 6 Ejido la Escondida, C.P. 98107, Zacatecas, México

² Docente-investigador, Unidad Académica de Enfermería, Área Ciencias de la Salud, Universidad Autónoma de Zacatecas “Francisco García Salinas” (UAZ), Campus UAZ siglo XXI, Carretera Zacatecas-Guadalajara Km 6 Ejido la Escondida, C.P. 98107, Zacatecas, México

³ Estudiante de la Maestría en Ciencias Biomédicas, Área Ciencias de la Salud, Universidad Autónoma de Zacatecas “Francisco García Salinas” (UAZ), Campus UAZ siglo XXI, Carretera Zacatecas-Guadalajara Km 6 Ejido la Escondida, C.P. 98107, Zacatecas, México

Copyright: © The Author(s) 2017. Licensee Joanna Bródka. This is an open access chapter licensed under the terms of the Creative Commons Attribution Non-Commercial 4.0 International License (<http://creativecommons.org/licenses/by-nc/4.0/>), which permits unrestricted, non-commercial use, distribution, and reproduction in any medium, provided the original work is properly cited.

ABSTRACT

Lifestyle is composed of behaviors and habits that refer to the customs of individuals, some behaviors may be protective factors for health, while others can be harmful facilitating the development of some disease such as periodontitis. A risk factor is defined as that circumstance that increases individual changes of contracting an illness or any health problem. The prevalence and severity of periodontal disease varies according to social, environmental, systemic and oral diseases, particularly the situation of individual oral hygiene. Among the determinants for the presence of this pathology in young people are age, gender, stress, socioeconomic level and academic instruction. The severity of the disease increases with age, there is a higher prevalence in women linked to hormonal changes in the

pubertal stage, stress period and has been associated with the low socioeconomic level characterized by poor hygienic and deficient dietary habits.

Keywords: Lifestyle; Periodontitis.

1. INTRODUCTION

Lifestyle and other factor can contribute in periodontal disease (PD). This is an endogenous microbial disease that damages the structure of the periodontium [1]. The disease derives from the cellular and humoral response of the host, altering the homeostasis of the periodontal tissues and causing inflammation and destruction by means of bacterial enzymes and virulence factors [2].

PD is divided in aggressive and localized Periodontitis. Aggressive periodontitis (AP) is a complex disease that promotes microbial alteration and cellular dysfunction in systemically healthy patients. It begins at any age and prevails in adolescents and young adults. It is characterized by rapid loss of adherence and bone destruction, inconsistent with the amount of microbial deposits present on dental surfaces in local or generalized form [3].

Localized Aggressive Periodontitis (LAP) begins at peri-pubertal age, with interproximal periodontal destruction in primary molar and in no more than two additional affected teeth [4]. The presence of dental calcifications on dental surfaces is not frequent; the tissues inflammation and bone-loss patterns are vertical and “U” in form [5]. Generalized Aggressive Periodontitis (GAP) affects more than three teeth in addition to the primary molars and incisors, and it presents loss of interproximal insertion in persons aged <30 years and episodic destruction of alveolar bone [6].

2. ETIOLOGY

This is a complex oral disease that possesses four principal risk factors: subgingival microbiota, individual genetic variations, lifestyle and systemic factors. All factors are play an important role in development of periodontitis.

2.1. Subgingival microbiota

The composition of the oral microbiota is influenced by factors how: temperature, pH, atmosphere, host defense and host genetics. Bacteria are responsible for stimulating the host response which defines tissue changes caused periodontal lesions. When bacteria work in association within a glycocalyx forming a biofilm, which allow microorganism to join and multiply on different surfaces. The biofilm protects microorganisms from toxic substances in the environment, it's also facilities the uptake of nutrients, the cross-feed, the elimination of metabolic products and the development of an appropriate environment with suitable physicochemical condition for their growth. In the periodontal surface it's not an exception because is associated with multiple oral microbiota in gingivitis and periodontitis phases. In periodontal disease in particular exist three bacteria with participation active in initiation and progression of this damage: *Aggregatibacter* (= *Actinobacillus*) *actinomycetemcomitans* (*Aa*) and *Porphyromonas gingivalis* (*Pg*) and *Tannerella forsythia* (*Tf*). These bacteria, due to the action of their virulence factors: immunosuppression factors (inhibit blastogenesis, antibody production and activate t-suppressor cells, lipopolysaccharides, antimicrobial resistance, leukotoxin, killed PMN and monocytes, resistant to complement-mediating killing, gingipain (collected nutrients for the *Pg* to survive), evasion of the host defenses and immune response, fimbriae, apoptosis-inducing activity, production of methylglyoxal and trypsin-lyke protease. These bacteria were called major pathogens or complex red in periodontal area [7].

2.2. Genetic variables

These are associated with biological or endophenotypic intermediaries, which have the potential to modify the host barrier function, inflammatory responses, and microbial colonization patterns. PD comprises a group of distinct conditions, with similar clinical and superimposed presentations in which each of these is influenced by human genetic variation. A non-protective inflammatory response presents that interacts with the biofilm of the dental surface, generating dysbiotic microbial changes and the establishment of the clinical disease [8].

Hereditary autosomal recessive mechanisms have been related to the appearance and progression of periodontal disease. In PD, there are interindividual differences in the degree of production of inflammatory cytokines, such as interleukin (IL)-1, tumor necrosis factor alpha (TNF- α), and prostaglandin E2 (PGE2), following a stimulation due to a leukocytic endotoxin. In addition to the presence of the genetic polymorphism associated with the

differences in the interindividual production of IL-1 and TNF- α , there are variants associated with AP, such as the *IL-4* gene [9]; this cytokine stimulates the production of B lymphocytes, Immunoglobulin G (IgG), and Immunoglobulin E (IgE) antibodies, and differentiation into T cells inhibits the inflammatory response of the macrophages and the production of IL-1. The polymorphism present in the receptor gene of vitamin D is related with bone density; thus, it is associated with LAP [10].

2.3. Immune response in periodontal disease

The physiopathology of PD is poorly understood, oral inflammation is relatively rare, usually is present in the tissue around the teeth, because of the supra and subgingival plaque stimulus; resident Dendritic Cells maintaining the immunological homeostasis instead bacterial presence. With the purpose to establish an immune response, a group of molecules called Toll-Like Receptor (TLR) which are transmembrane proteins expressed in macrophages and dendritic cells and also in mucosal cells; those receptors are associated to damage/danger molecular patterns, they recognize molecules in intra and extracellular pathogens. It was demonstrated that TLR2 is expressed in Periapical granulomas and Periapical cyst and TLR4 is overexpressed leads to NF- β expression and translocation, as consequence, inflammatory and adaptive immune response against oral microbial are induced [11].

On other hand, Langerhans cells (LC) in the mucosa, are considered the first cells to sample antigens (Ag) from the biofilm and elicit regulatory or proinflammatory response [12]. The continuous stimulation of plaque and Antigen presenting cells activation, promote the specific repertory of immune cells, in this way the role of CD4+ Th cells, Th1, Th2, Th17 or iTregs in soft tissue and bone destruction is should be related to cytokine expression as IL-10, IL-17, IFN γ and RANKL, that influence Th1 phenotype, osteoclast activation and damped iTregs [13]. Considering this cytokines network and the role of LC, *P. gingivalis* antigens recognized and processed by LC, it seems that polarized the immune response to Th17 influenced by LC [14]. Also the expression of IL-1 α and IL-1 β induced in gingival epithelial cells by *A. actinomycetemcomitans* extracts, triggers inflammatory mediators and expression of IL-18 [15]; Both cytokines IL-1 α and IL-18 improve the inflammations associated with the immunomodulatory effects of β -glucans and its antimicrobial activity of the immune cells and mediators [16, 17]. The expression of immunological receptors in gingival fibroblasts because

the interaction with bacterial components in the dental plaque, and the constant mechanical stimulation, maintains the secretion of IL-6, IL-8 and IL-1 producing the chronic inflammatory response [18].

In chronic periodontitis, some others factors related with the immune regulation are involved in periodontal disease, some of them is the stress hormone called cortisol, this hormone is important, because of the regulation through the hypothalamic pituitary adrenal axis, cortisol participate in the recruitment of immune cells, promotes the inflammatory response and induce an imbalance between Th1/Th2 with the subsequent polarizations to Th2 cells [19].

Besides the cell mediate immune response, higher levels of serum IgG to *P. gingivalis*, *A. actinomycetemcomitans* and *Prevotella intermedia*, favors an adequate immune response, in contrast to lower levels of IgG to *T. forsythia*, *Treponema denticola* and *Fusobacterium nucleatum*, indicating that these microorganism are poorly immunogenic, suggesting increased risk for periodontal disease progression as compared to the first group of periodontal pathogens [20]. Finally it will be considered, that antimicrobial peptides expressed in response to oral bacteria or bacterial components should be used as a biomarker for the diagnosis, progression and risk development of periodontal disease, matrix metalloproteases 8, 9 and 13, are related to gingival and alveolar bone degradation, receptor activator for nuclear factor κ B (RANKL) and decreased expression of osteoprotegerin induce osteoclastogenesis activation, IL-1 β , IL-6 and TNF α are considered in periodontitis, as a promoters of inflammatory, rather than bacterial presences, and should be determinant to periodontal destruction, in accordance with this findings, used as a tool, all of this biomarker it will help for the diagnosis and prognosis in periodontal diseased patient [21].

2.4. Lifestyle and periodontal disease

Life styles can be understood to be a sum of actions and behaviors that an individual develops towards a form of good health or bad health, including aspects relating to drug use, physical exercise, nutrition, sexuality, leisure activities and stress control [22]. Life styles are determined by the presence of risk factors and/or factors that protect and lead towards wellbeing. This is why they should be seen like a dynamic process that is not only formed by an individual's actions and behaviors because they are also actions based on a social nature. A

risk factor is defined as those circumstances that increase the individuals' possibility of obtaining a disease or any type of health issue [23].

Life style is not a vague concept that can be modified voluntarily it is closely interrelated with life conditions, therefore it is not just a simple decision of the individual. Since limits exist for open options for the individual because of environmental causes, social media and economic media, as well [24]. This is how some actions can be protection factors towards health, while others can be harmful facilitating the attainment of many diseases, like what could be of a dental type or specifically a periodontal disease [25].

The prevalence and severity of periodontal disease varies in function of the risk factors, where you can find actions, life styles, systemic, amicrobic, philological, psychosocial, family, sociodemographic and those related with the individuals' dental hygiene [26]. Among the predetermining factors that lead to the presence of this pathology specifically in young populations, are the modifiable and the non-modifiable [27]. The modifiable can be intervened with or controlled to reduce the risk of initiation or progression of the periodontal diseases. For example: the action factor and life styles that include tobacco alcohol or drug use, stress management, obesity, low social economic level, and the level of educational orientation [28].

On the other hand, the non-modifiable factors or are generally intrinsic to the individual, which is why there are non-controllable. For example: genetic characteristics, family aggregation, among others [28]. To that affect, it has been observed that the severity of the disease is increased with ageing, and in the case of gender there exists more prevalence in women related with hormone change in the puberty stage [29, 30]. It should be noted that each and every one of the factors included continuously was reviewed and analyzed thoroughly. Here provided below are some of the risk factors of actions and life styles:

2.4.1. Smoking

The use of tobacco is considered the principal risk factor for the affection of the prevalence and progression of periodontitis, in which the severity depends on the doses of consumption [31]. The effects that provoke tobacco use are represented by the formation of dental bacterial plaque and the inflammatory response of the diseases progress. The physical pathological effects are due to the harmful actions of the nicotine, the smoke and carbon monoxide that result from the incomplete combustions favor a serious of molecular events [32].

The number of cigarettes and years of use increase the severity of periodontitis, less response exists to periodontal therapeutic treatment and its use increases the loss of teeth settings and it promotes osteoporosis that of the alveolar crestal height supports [33]. There exists enough evidence that demonstrates the very close relationship that exists between tobacco use in periodontal disease [34]. Such is the case of authors Zini, Sgan and Marcenes [35] who found that smoking exerts a substantial destructive effect on periodontal tissue and increases the rate of progression of the periodontal disease. It has also been found that the hosts' response can be modified and provoke a proliferation of bacteria of the dental plaque [36].

Smokers with periodontal disease apparently seem to show less signs of clinical inflammation and gum bleeding in comparison with nonsmokers. This could be explained by the fact that nicotine exerts local constriction of blood vessels, reducing blood flow, the edema and clinical signals of inflammation. Nicotine acetylcholine receptor has been found to play an important role in the development of nicotine related periodontitis [37].

In Table 1 the signs symptoms and changes of the periodontal tissue attributed to tobacco use are summarized.

Table 1. Findings from smoker patients with periodontal disease

Parameter	Smoker patients
Gum bleeding	Less gum bleeding and higher amount of small blood vessels
Bone height	Greater bone lose
Level of Insertion (NI)	Greater lose of (NI)
Sondeable depth	Greater sondeable depth
Number of lost teeth	Number of lost teeth

Source: Adapted from Rivera-Hidalgo [38]

On the other hand, it has also been compared that when the smoking habit is suspended favorable changes can occur on the immune system against germ attack. It has been reported that when the habit is suspended it can halt the periodontitis progression and better the results of the treatment and the periodontal prognostic. The periodontal state of the patients that were smokers and that currently are not is intermediate among those that have never smoked and current active smokers; in other words adopting a healthy life style like leaving the smoking habit has shown to positively affect the periodontal state [39].

2.4.2. Alcohol

Alcoholism is related to the harmful effects over the hosts' response. The consumption of alcohol could have significant impact over hemostasis on the periodontal bacteria and the hosts' response [40]. Abusing the use of alcoholic beverages during a long period of time is related to the origin, severity and evolution of gum and periodontal disease with an even higher probability of attainment, in relation with non-alcoholic individuals. The production of periodontal pathologies in the alcoholic patient is based on criteria over the effect of alcohol on the tissue. For example, alcoholic patients show an altered immune response, alcohol has a toxic effect over the liver causing alterations of the coagulation mechanisms. Those individuals that are classified as conspicuous smokers' frequently present nutritional disorders, and with that resulting in protein and vitamin deficiencies [41].

Other risk factors for periodontitis pathologies in alcoholic patients is a deficiency in oral hygiene due to an overall lack of personal hygiene and from the low saliva flow or xerostomia as a consequence of the morphological and functional alteration of the glandules due to an ethanol effect. Alcohol produces epithelial atrophy in the oral mucosae, it increases permeability of mucosae increases the solubility of the toxic substances like those derived from smoking [42].

2.4.3. Drug-induced disorders

Another important factor in the appearance of periodontal diseases there are found disorders caused by the consumption of drugs which produce a decrease salivary flow among which antihypertensive, narcotic analgesics, some tranquilizers and sedatives, antihistamines, and antimetabolites [41]. Other drugs in particular those in liquid or chewable forms that contain added sugar. They alter the Ph. and the plaque composition. Also documented is that drugs such as anticonvulsants, calcium channel blocking agents, and cyclosporine may induce gingival overgrowth. It has been demonstrated that young patients have an excessive response to drugs due to the higher level of androgens in blood levels [43].

2.4.4. Stress

Regarding stress, it has been found that it is a risk indicator for the development of the periodontal disease; the effects to the response of the organism to anxiety, depression,

cognitive alteration and self-esteem alteration are what causes distortion in health conducts therefore the incorporation of negligent practices of oral hygiene and formation of bruxism. Also depression is a stress indicator and is related to tobacco use, alcohol and intake of an insufficient diet, hence forth provoking the increase in the susceptibility of the patient to infection due to bacterial development [44].

Patients with inadequate behavioral strategies on stress (defensive adaptation) are in greater risk of severe periodontal disease [45]. Stress is associated with an increased risk of glucocorticoid secretion that can depress immune function, increased insulin resistance and potentially, periodontitis. Studies have found some periodontal disease indicators such as tooth loss and gingival bleeding to be associated with work stress and financial strains [46].

2.4.5. Obesity

Obesity is multifactorial chronic disease considered the most commune nutritional disorder in America, therefore a risk factor for many systemic diseases. Chronic inflammation has a multidirectional relationship with obesity and chronic periodontitis, among other diseases. Furthermore several explanations for the association between obesity and periodontal disease in younger adults have been provided. Younger people may have different dietary patterns than older study participants [47].

Research in dietary trends in adolescent's ages from 11 to 18 reveals a significant decrease in raw fruit and non-potato vegetables, which are sources of vitamin C. In addition, adolescents have decreased their calcium intake and increased their intake of soft drinks and non-citrus juices. This is important to oral health because low dietary intake of calcium and vitamin C has been associated with periodontal disease. People who consume less than the recommended dietary allowance (RDA) for calcium and vitamin C have slightly higher rates of periodontal disease [48].

3. EPIDEMIOLOGY

There are reports in the literature that AP affects 47.2% of the U.S population; the prevalence of AP in adolescents has been estimated at between 0.1 and 2%. Other studies whose objective was to determine periodontal disease in young population found a prevalence in persons aged between 13 and 20 years of <1%, while in adolescents between the ages of

15 and 17 years, the prevalence was estimated at 0.2% for Caucasians and at 2.6% for Blacks. Similarly, greater prevalence was found in women than in men, and <1% of the population aged under the age of 30 years had AP [49].

The prevalence of LAP in European population varies among adolescents and young adults between 0.1 and 0.2% [50]. In industrialized countries, it was found that LAP affects primary dentition in children aged between 5 and 11 years, with a frequency ranging between 0.9 and 4.5% [51, 52].

4. DIAGNOSIS

Periodontal clinical parameters are as follows: Probing Depth (Pd); Level of Clinical Insertion (LCI), and Bleeding on Probing (BOP). Pd is the space than can measure between 1 and 3 mm in the absence of clinical inflammation; a periodontal pocket is defined as the pathological depth of the depth of the periodontal groove, rendered by bone loss and periodontal insertion. For practical clinical effects, a periodontal pocket represents one of the cardinal signs of periodontitis, given that it is produced by the loss of insertion, and can be considered as such from 4mm. The National Informatics Centre (NIC) makes reference to the fibers of the connective gingival tissue that are inserted into the radicular/root cement through the Sharpey fibers. In the clinical ambit, NIC is utilized to refer to the magnitude of support loss, but it depends on the particular radicular length of each tooth.

BOP is the main predictor of periodontal disease and is induced by penetration of the periodontal probe. It should be interpreted in a global manner, because its presence is not absolutely indicative of disease, while its absence is indeed a reliable indicator of periodontal health.

4.1. Radiographic bone loss

Radiographically, periodontal bone pathology presents loss in the continuity of bone and cortical crests, loss of bone height, formation of bone defects, and periodontal ligament enlargement and furcation. Bone loss severity is classified according to the distance from the Cemento-Enamel Junction (CEJ) to the tooth apex: cervical or mild; medium or moderate, or apical or severe.

4.2. Diagnostic alternatives

Different complementary diagnostic alternatives to the clinical diagnosis: the use of immunoproteomic approaches implied in the immune response. There is a wide variety of potential proteomic periodontal markers that are included within the immunoproteome: from immunoglobins to bone remodeling proteins. Immunoglobulin M (IgM) is a natural antibody that can bind specific antigens to those to which the host has never been exposed, and it presents traits that allow it to bind to antigens to the degree of invasion, resulting in the activation of the complement as a mechanism of first-line defense, participating in early recognition of bacteria in periodontal disease [53].

C-reactive protein (CRP) is a plasma protein that reflects a measurement of the acute-phase response to inflammation, and is one of the markers-of-choice in the follow-up of this response. It is a recognition molecule of patterns that bind specific molecules that are produced during cell death or that are found on the surfaces of diverse bacterial pathogens. The rapid increase of CRP synthesis during the first hours of the progression of an infection suggests its contribution to defense of the host as part of the innate immune response. CRP is produced in response to many types of distinct lesions of periodontitis, which is found regulated by diverse cytokines. The changes in the cellular and molecular compartments of peripheral blood can be found in patients with periodontitis due to inflammatory changes in the periodontal tissues [54].

5. TREATMENT

In PD, conventional mechanical therapy and oral hygiene is not sufficient to control the disease. The use of broad-spectrum antibiotics, such as amoxicillin/clavulanic acid, metronidazole, clindamycin, ciprofloxacin, tetracycline, and azithromycin are efficient in pharmacological treatment, in addition to treatments such as surgery, laser therapy, and photodynamic therapy [55].

Photodynamic Therapy (PDT) is a non-invasive tool that functions from the generation of free radicals (FR) and oxygen molecules through a photosensitizer placed in an inactive target tissue, inactivating microorganisms or molecules that react with the light activator. The cytoplasmic membrane of the bacterium is damaged, leading to the inactivation of the membrane transport system, inhibition of the plasma membrane, enzymatic activities,

and lipid peroxidation, [56] destruction of proteins and ion channels, elimination of critical metabolic enzymes, cell agglutination, and direct inhibition of exogenous virulence factors such as lipopolysaccharides, collagenase, and protease. PDT acts in microorganisms such as fungi, viruses, and protozoans, infections due to simple herpes virus, *P. gingivalis*, *P. intermedia*, and *A. actinomycetemcomitans*. In the other hand plants natural products (*Camellia sinesis*, *Quercus rubra*, *Caria illinoensis*, *Smilax glycyphylla*) and phytomedicine were proposed how new alternatives in treatment of periodontal disease, present inhibit of biofilm formation, antibacterial activity and inhibition of cariogenic potential [57].

ACKNOWLEDGEMENTS

Thanks to Maestría en Ciencias Biomedicas and Unidad Académica de Enfermería, Área Ciencias de la Salud, Universidad Autónoma de Zacatecas “Francisco García Salinas” (UAZ) for contribute in the elaboration of this chapter.

REFERENCES

1. Ocampo Yáñez BR, Marín González MG. Tratamiento de periodontitis agresiva localizada con plasma rico en plaquetas y aloinjerto óseo. Un caso clínico. Rev Odontol Mexic. 2015; 19: 106-114.
2. Paknejad M, Khorsand A, Yaghobee S, Motahhari P, Etebarian A, Bayani M, Mehrfard A. Cementogenesis in patients with localized aggressive periodontitis. J Dent. 2015; 12: 347-351.
3. Aristizábal JF, Martínez R. Tratamiento ortodóncico y periodontal combinado en pacientes con periodontitis agresiva tratada y controlada. Rev Facult Odontol Univ Antioquia. 2014; 26: 180-204.
4. Koss MA, Castro CE, Gramajo AM, López ME. sIgA, peroxidase and collagenase in saliva of smokers aggressive periodontal patients. J Oral Biol Craniofacial Res. 2016; 6: S24-S28.
5. Merchant SN, Vovk A, Kalash D, Hovencamp N, Aukhil. Localized aggressive periodontitis treatment response in primary and permanent dentitions. J Periodontol. 2014; 85: 1722-1729.
6. Lang N, Bartold PM, Cullinan M, Jeffcoat M, Mombelli A, Murakami S, Dyke TV. Consensus report: aggressive periodontitis. Ann Periodontol. 1999; 4: 53-53.

7. Ciriaco EV, Buendía MDCL. Tratamiento multidisciplinario en una paciente con periodontitis agresiva generalizada y diabetes mellitus tipo 1. *Rev Odontol Mexic.* 2014; 18: 32-37.
8. Offenbacher S, Divaris K, Barros SP, Moss KL, Marchesan JT, Morelli T, Laudes M. Genome-wide association study of biologically-informed periodontal complex traits offers novel insights into the genetic basis of periodontal disease. *Human Mol Gen.* 2016; 25: 2113-2129.
9. Gutiérrez RF. Polimorfismo y genética y su relación con la enfermedad periodontal. *Rev Kiru.* 2015; 5: 127-135.
10. Chatzopoulos GS, Doufexi AE, Kalogirou F. Association of susceptible genotypes to periodontal disease with the clinical outcome and tooth survival after non-surgical periodontal therapy: A systematic review and meta-analysis. *Med Oral Patol Oral Cirugía Bucal.* 2016; 21: e14-e29.
11. Leonardi R, Perrota RE, Loreto C, Musumeci G, Crimi S, Dos Santos JN, Rusu MC, Bufo P, Barbato E, Pannone G. Toll-Like Receptor 4 expression in the epithelium of inflammatory periapical lesions. An immunohistochemical study. *Eur J Histochem.* 2015; 58: 279-282.
12. Malisse B, Tamoutounour S, Henri S. The origins and functional of dendritic cells and macrophages in the skin. *Nature Rev Immunol.* 2014; 14: 417-428.
13. Arizon M, Nudel I, Segev H, Mizraji G, Elnekave M, Furmanov K, Eli Berchoe L, Clausen BE, Shapira L, Wilensky A and Hovav AH. Langerhans cells down regulated inflammation driven alveolar bone loss. *Proc Nat Acad Sci USA.* 2012; 109: 7043-7048.
14. Van der Aar AM, Picavet DI, Muller FJ, De Boer L, Van Capel TM, Zaat SA, Bos JD, Janssen H, George TC, Kapsenberg ML. Langerhans cells favor skin flora tolerance through limited presentation of bacterial antigens and induction of regulatory T cells. *J Invest Dermatol.* 2013; 133: 1240-1249.
15. Sfakianakis A, Barr CE, Kreutzer DL. *Actinobacillus actinomycetemcomitans* induced expression of IL-1 alpha and IL-1 beta in human gingival epithelial cells: role in IL-8 expression. *Eur J Oral Sci.* 2001; 109: 393-401.
16. Sonk E, Stuyven E, Goddeeris B, Cox E. The effect of beta glucanas on porcine leucocytes. *Vet Immunol Immunopathol.* 2010; 135: 199-207.
17. Oliveira Silva V, Jose Pereira L, Mendoca Murata R. Oral microbe host interactions; Influence of β -glucans on gene expression of inflammatory cytokines and metabolome profile. *BMC Microbiology.* 2017; 17: 1-9.

18. Moon Soo K, Jeong Won Y, Jin Ho P, Bong Wook P, Young Hoon K, Young Soo H, Sun Chul H, Dong Kyun W. Autophagy has a beneficial role in relieving cigarette smoke induced apoptotic death in human gingival fibroblast. *Int J Med Sci.* 2016; 13: 357-364.
19. Rohini G, Kalaivani S, Kumar V, Rajasekar SA, Tukaram J, Pandey V. Estimation and comparison of serum cortisol levels in periodontal diseased patient and periodontally healthy individuals: A clinical biochemical study. *J Pharm Bioall Sci.* 2015; 7: S457.S460.
20. Utton S, Hee Kyun O, Hyun Ju C, Young Joon K, Ok Su K, Hoi Jeong L, Min Ho S, Seok Woo L. Humoral immune response to periodontal pathogens in the elderly. *J Period Implant Sci.* 2015; 45: 178-183.
21. Güliz N, Dogukan Y, Eija K, Ulvi KG. Salivary antimicrobial peptides in early detection of periodontitis. *Front Cell Infect Microbiol.* 2015; 5: 1-6.
22. Gómez-Cabello A, Vicente-Rodríguez G, Pindado M, Vila S, Casajús JA, Pradas de la Fuente F. et al. Mayor riesgo de obesidad y obesidad central en mujeres post-menopáusicas sedentarias. *Nutrición Hospitalaria.* 2012; 27: 865-870
23. Juárez RP, Chahín JR, Vizcaya MM, Arduña EI. Salud oral en pacientes con diabetes tipo 2: caries dental, enfermedad periodontal y pérdida dentaria. *Odontol Sanmarquina.* 2014; 10: 10-13.
24. Guerrero Montoya LR, León Salazar AR. Estilo de vida y salud. *Educere.* 2010; 14: 13-19.
25. Román R, Zerón A. Factores de riesgo asociados a la enfermedad periodontal. *Rev Mexic Periodontol.* 2015; 6: 62-66.
26. Nunn ME. Understanding the etiology of periodontitis: an overview of periodontal risk factors. *Periodontology 2000.* 2003; 32: 11-23.
27. Genco RJ. Current view of risk factors for periodontal disease. *J Periodontol.* 1996; 67: 1041-1049.
28. Alvear FS, Vélez ME, Botero L. Factores de riesgo para las enfermedades periodontales. *Rev Facult Odontol Univ Antioquia.* 2010; 22: 109-116.
29. Bermeo Brunella Soriano K. Gingivitis relacionada con enfermedades sistémicas por mala nutrición en niños escolares. Tesis pregrado: Universidad de Guayaquil. 2014
30. Pazmino VF, Assem NZ, Pellizzer EP, De Almeida JM, Theodoro LH. Influencia del estrógeno en la enfermedad periodontal: revisión de literatura. *Avances Periodoncia.* 2015; 27: 75-78.
31. Hujoel PP, Del Aguila MA, De Rouen TA, Bergström J. A hidden periodontitis epidemic during the 20th century. *Commun Dent Oral Epidemiol.* 2003; 31: 1-6.

32. Treviño-Elizondo R, Quiroga-García MA, López-Martínez F, Cruz-Palma G. El tabaco como factor de riesgo en los tejidos periodontales. *Rev Mexic Estomatol.* 2015; 2: 7-8.
33. Traviesas-Herrera EM, Márquez-Arguellez D, Rodríguez-Llanes R, Rodríguez-Ortega J, Bordón- Barrios D. Necesidad del abandono del tabaquismo para la prevención de enfermedad periodontal y otras afecciones. *Rev Cubana Estomatol.* 2011; 48: 257-267.
34. Kubota M, Tanno-Nakanishi M, Yamada S, Okuda K, Ishihara K. Effect of smoking on subgingival microflora of patients with periodontitis in Japan. *BMC Oral Health.* 2011; 11: 1-6.
35. Un Zini, Sgan-Cohen HD, Marcenes W. Socio-economic position, smoking, and plaque: a pathway to severe chronic periodontitis. *J Clin Periodontol.* 2011; 38: 229-235.
36. Ozçaka O, Bicakci N, Pussinen P, Sorsa T, Köse T, Buduneli N. Smoking and matrix metalloproteinases, neutrophil elastase and myeloperoxidase in chronic periodontitis. *Oral Dis.* 2011; 17: 68-76.
37. Wang C, Cai Y, Duan, Wang X. Nicotinic acetylcholine receptor but not acetylcholinesterase plays an important role in nicotine-related periodontitis. *Med Hypotheses.* 2010; 74: 954955.
38. Rivera-Hidalgo F. Smoking and periodontal disease. *Periodontology 2000.* 2003; 32: 50-58.
39. Preshaw PM, heasman L, Stacey F, Steen N, McCracken GI, heasman PA. The effect of quitting smoking on chronic periodontitis. *J Clin Periodontol.* 2005; 32: 869-879.
40. Lauritano D, Pazzi D, Iapichino A, Gaudio RM, Di Muzio M, Lo RL. Evaluation of the efficacy of a new oral gel containing carvacrol and thymol for home oral care in the management of chronic periodontitis using pcr analysis: a microbiological pilot study. *J Biol Regul Homeostatic Agents.* 2016; 30: 129-134.
41. Ruiz-Candina H, Herrera-Batista A, Puldón Seguí G. Enfermedades médicas y estomatológicas provocadas por el alcoholismo en adultos y adolescentes. *Rev Cubana Investig Bioméd.* 2012; 31: 26-36.
42. Figueredo-Ruiz E, Carretero Peláez MA, Cerero La piedra R, Esparza Gómez G, Moreno López LA. Efectos del consumo de alcohol étílico en la cavidad oral: Relación con el cáncer oral. *Med Oral.* 2004; 9: 2-9.
43. AlJehani YA. Risk factors of periodontal disease: review of the literature. *Int J Dent.* 2014; 1-9.
44. Castellanos-González M, Cueto-Hernández M, Boch M, Méndez-Castellanos C, Méndez-Garrido L, Castillo Fernández C. Efectos fisiopatológicos del tabaquismo como factor de riesgo en la enfermedad periodontal. *Rev Finlay.* 2016; 6: 134-149.

45. Johannsen A, Rylander G, Söder B, Åsberg M. Dental plaque, gingival inflammation, and elevated levels of interleukin-6 and cortisol in gingival crevicular fluid from women with stress-related depression and exhaustion. *J Periodontol.* 2006; 77: 1403-1409.
46. Merchant AT, Pitiphat W, Ahmed B, Kawachi I, Joshipura K. A prospective study of social support, anger expression and risk of periodontitis in men. *J Am Dental Assoc.* 2003; 134: 1591-1596.
47. Shimazaki Y, Egami Y, Matsubara T, Koike G, Akifusa S, Jingu S, Yamashita Y. Relationship between obesity and physical fitness and periodontitis. *J Periodontol.* 2010; 81: 1124-1131.
48. Neiva RF, Steigenga J, Al-Shammari KF, Wang HL. Effects of specific nutrients on periodontal disease onset, progression and treatment. *J Clin Periodontol.* 2003; 30: 579-89.
49. Schenkein HA, Koertge TE, Sabatini R, Brooks CN, Gunsolley JC. Birth weight of infants of mothers with aggressive periodontitis. *J Periodontol.* 2012; 83: 279-286.
50. Renatus A, Trentzsch L, Schönfelder A, Schwarzenberger F, Jentsch H. Evaluation of an electronic periodontal probe versus a manual probe. *J Clin Diagn Res JCDR.* 2016; 10: ZH03-ZH07.
51. Garcia-Madueño N, Gutiérrez-Romero F, Bolaños-Palacios J. Eficacia de la terapia periodontal no quirúrgica en una periodontitis agresiva. *Duazary.* 2016; 13: 52-56.
52. Ardila-Medina CM, Botero-Zuluaga L, Guzmán-Zuluaga IC. Comparación de las características sociodemográficas, clínicas y microbiológicas de pacientes con periodontitis agresiva y crónica. *Rev Arch Med Camaguëy.* 2014; 18(5): 532-544.
53. LinHS, Talwar HS, Tarca AL, Ionan A, Chatterjee M, Ye B, Peshek B. Autoantibody approach for serum-based detection of head and neck cancer. *Cancer Epidemiol Biomarkers Prev.* 2007; 16: 2396-2405.
54. Podzimek S, Mysak J, Janatova T, Duskova J. C-reactive protein in peripheral blood of patients with chronic and aggressive periodontitis, gingivitis, and gingival recessions. *Mediators Inflamm.* 2015; 2015: 564858.
55. Ercan E, Uzun BC, Ustaoglu G. Effects of azithromycin versus metronidazole-amoxicillin combination as an adjunct to nonsurgical periodontal therapy of generalized aggressive periodontitis. *Nigerian J Clin Pract.* 2015; 18: 506-510.
56. Chatzopoulos G-S, Doufexi A-E. Photodynamic therapy in the treatment of aggressive periodontitis: A systematic review. *Med Oral Patol Oral Cirugía Bucal.* 2016; 21: e192-e200.

57. Cid F, Jara J, Huerta L, Oliva P. Eficacia de terapia fotodinámica como complemento de Terapia convencional periodontal versus terapia convencional en el tratamiento de pacientes adultos con periodontitis crónica: una revisión sistemática con meta análisis. *Int J Odontostomatol.* 2016; 10: 315-323.

Microbiology of dental plaque in periodontal health and disease

4

Shaila Kothiwale, Jyoti Ajbani

Department of Periodontics, K.L.E's V. K Institute of Dental Sciences, K.L.E University, Nehru Nagar,
Belgaum, Karnataka, 590010, India

Copyright: © The Author(s) 2017. Licensee Joanna Bródka. This is an open access chapter licensed under the terms of the Creative Commons Attribution Non-Commercial 4.0 International License (<http://creativecommons.org/licenses/by-nc/4.0/>), which permits unrestricted, non-commercial use, distribution, and reproduction in any medium, provided the original work is properly cited.

ABSTRACT

Dental plaque is highly variable structural entity formed by accumulation and growth of microorganisms on teeth. This chapter encompasses the composition and structure of dental plaque. It puts some light on formation of dental plaque and micro-organisms in it responsible for different periodontal diseases. It also discusses with various changing concepts put forward in plaque microbiology till date. It also enumerates various microorganisms in periodontal health and diseases.

Keywords: Dental plaque; Microbiology; Microorganisms.

1. INTRODUCTION

Dental plaque is complex microbial community which develops on tooth surface. Dental plaque has been defined as the diverse microbial community found on the tooth surface embedded in a matrix of polymers of bacterial and salivary origin [1]. Dental plaque appears as is sticky colorless deposit hard surfaces in the oral cavity at first. Dental plaque should be differentiated from materia alba which is a product of informal accumulation of living and dead bacteria, desquamated epithelial cells, disintegrating leucocytes, salivary

proteins and particles of food debris. Whereas dental plaque has a definite structure primarily consisting of various colonies of micro-organisms with intercellular substance bridging between them. When dental plaque mineralises it leads to formation of calcified mass known as dental calculus also referred to as tartar. Dental calculus is always covered by a layer of unmineralised dental plaque.

Plaque is naturally found on tooth surfaces in health as well as disease. When plaque accumulates beyond compatible levels it is accompanied by various changes in the microflora in it. This change in microflora predisposes to various plaque associated diseases namely dental caries and periodontal diseases. This chapter encompasses plaque microbiology associated with periodontal diseases.

2. PLAQUE AS A BIOFILM

The concept of biofilms is not novel. The first description dates back to the 17th century, when Anton Von Leeuwenhoek - the inventor of the microscope, saw microbial aggregates (now known to be Biofilms) on scrapings of plaque from his teeth. The term 'Biofilm' was coined by Bill Costerton in 1978.

Biofilms are a group of one or more types of microorganisms that can grow on different surfaces. Biofilms can form on any surface immersed in an aquatic environment. Biofilm formation starts when free-floating microorganisms such as bacteria come in contact with an appropriate surface. Dental plaque is basically a structurally and functionally organised biofilm.

A major advantage is the protection that biofilm provides to the colonizing species from competing micro-organisms, environmental factors such as host defense mechanisms and potentially toxic substances like lethal chemicals or antibiotics. Biofilms also facilitate processing and uptake of nutrients, cross feeding and removal of potentially harmful metabolic products through the voids or water channels between the micro-colonies, acting as a circulatory system [2].

Another characteristic of biofilm is that microorganisms can communicate with each other in a biofilm. This cell to cell communication is referred to as quorum sensing. The communication occurs via chemical signals or by transferring genetic material through conjugation mechanisms [3]. Quorum sensing may give biofilms their distinct properties, e.g. expression of genes for antibiotic resistance at high cell densities may provide protection. It

also has the potential to influence community structure by encouraging the growth of species beneficial to the biofilm and discouraging the growth of competitors.

3. COMPOSITION

Dental plaque is composed primarily of microorganisms. Cultivation studies, in which bacteria are isolated and characterized in the laboratory, indicate that more than 500 distinct microbial species are found in dental plaque. Nonbacterial microorganisms that are found in plaque include *Mycoplasma* species, yeasts, protozoa, and viruses [4].

The microorganisms exist within an intercellular matrix that also contains a few host cells such as epithelial cells, macrophages, and leukocytes. The intercellular matrix, estimated to account for 20% to 30% of the plaque mass consists of organic and inorganic materials derived from saliva, gingival crevicular fluid, and bacterial products. Organic components consist of variety of polysaccharides, glycoproteins, and lipid molecules. Polysaccharides and glycoproteins can be derived from gingival crevicular fluid or saliva. Lipids can be derived from membranes of bacterial and host cells. The inorganic component mainly include calcium, phosphorus and in small amounts sodium, potassium and fluoride. The inorganic is predominantly derived from saliva. The fluoride can be derived from toothpastes, rinses and water. The matrix is more than a mere scaffold for the biofilm. The matrix can bind and retain molecules, and various enzymes [5, 6].

4. STRUCTURE OF DENTAL PLAQUE

The discovery of electron microscope in dental research was a significant development for studies of dental plaque. Dental plaque can be broadly classified into two categories: supragingival plaque and sub-gingival plaque [4]. The different regions of the plaque are associated with different diseases of the teeth and peridontium. For example supra-gingival plaque can lead to gingivitis and dental caries whereas sub-gingival plaque can lead to periodontitis.

4.1. Supra-gingival plaque

It is found at or above the gingival margin. It is associated with calculus formation and

root caries (Fig. 1). Supra-gingival plaque can further be categorized into coronal plaque and marginal plaque [7].

(i) Coronal plaque - it is that plaque which is in contact with the tooth surface only.

(ii) Marginal plaque - it is associated with the tooth surface at the gingival margin. It is of prime importance in development of gingivitis.

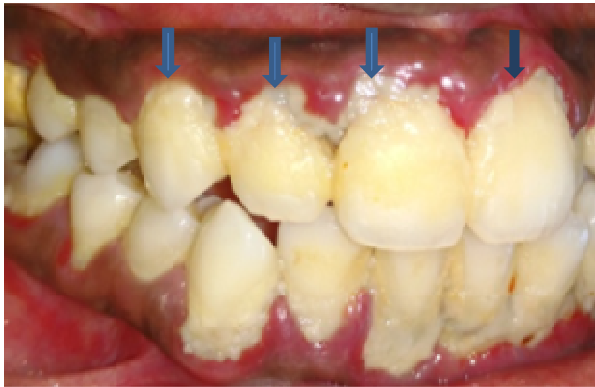

Fig. 1. Supragingival plaque

4.2. Sub-gingival plaque

It is found below the gingival margin between the tooth and the gingival sulcular tissue. It is usually thin and cannot be detected with direct vision. Its presence can be identified only by running the end of a probe around gingival margin. It can be further classified into - attached plaque and unattached plaque (Fig. 2).

(i) Attached plaque:

(a) Tooth associated sub gingival plaque: its structure similar to supra-gingival plaque. Flora is dominated by Gram-positive and some Gram-negative cocci and rods. It is associated with calculus formation root caries, root resorption.

(b) Epithelium associated sub-gingival plaque: it is loosely adherent because it lacks inter-bacterial matrix. It is directly associated with gingival epithelium and extends from gingival margin to the junctional epithelium. Predominantly Gram-negative rods and cocci as well as large number of flagellated bacterial and spirochetes are found in it.

(c) Connective tissue associated sub-gingival plaque: it can be demonstrated in acute necrotising ulcerative gingivitis and localized aggressive periodontitis patients. It is associated with soft tissue destruction that characterizes different forms of periodontitis.

(ii) Unattached plaque: it can be seen anywhere on the tooth surface and sub-gingivally. It is associated with rapid periodontal destruction [7].

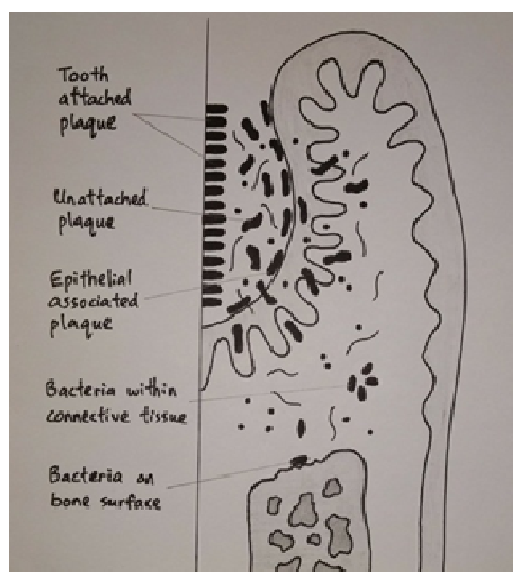


Fig. 2. Subgingival plaque

5. FORMATION OF DENTAL PLAQUE

The process of plaque formation can be divided into three phases:

1. Formation of the pellicle coating on the tooth surface,
2. Initial colonization by bacteria,
3. Secondary colonization and plaque maturation.

1. Formation of the pellicle coating on the tooth surface

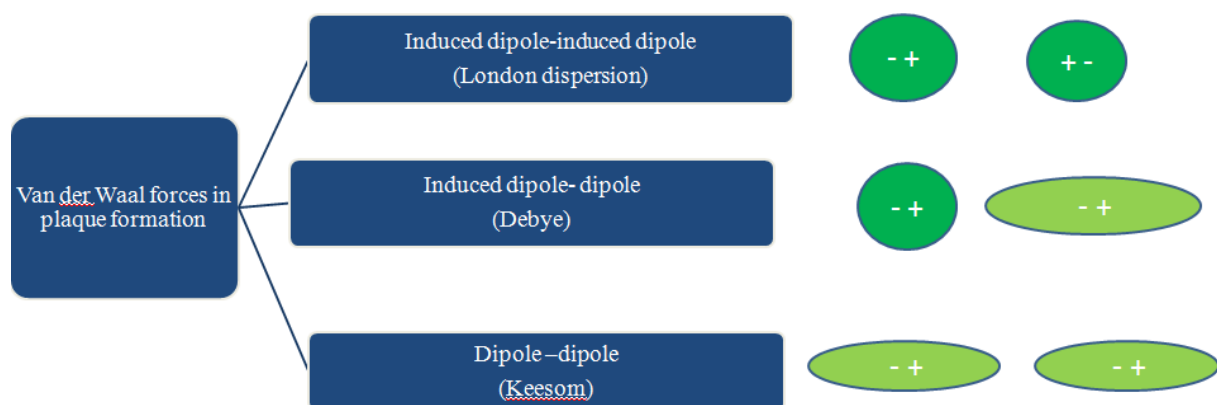
All the surfaces of oral cavity including the shedding surfaces (tissue) and non shedding surfaces (tooth, fixed and removable restorations) are coated with a glycoprotein pellicle. This pellicle is derived from saliva, crevicular fluid, bacterial and host tissue cell products and debris [8]. This is an amorphous layer of 0.1-1 mm thick. The pellicle formation starts within a few seconds after cleaning teeth. Whenever a clean enamel surface is exposed to oral environment, it gets coated with glycoproteins derived from saliva. The mechanisms involved in enamel pellicle formation include electrostatic, Van der Waals, and hydrophobic forces. The hydroxyapatite surface has a predominance of negatively charged phosphate

groups i.e. interacts directly or indirectly with positively charged component of salivary and cervicular fluid macromolecules. Pellicles function as a protective barrier, providing lubrication for the surfaces and preventing tissue desiccation, however they also provide a substrate to which bacteria in the environment attach.

2. Initial colonization by bacteria

Initially, transport of bacteria to the tooth surface takes place. This process occurs randomly through Brownian motion, sedimentation of microorganisms, through liquid flow or active bacterial movement. Initial adhesion of bacteria takes place through various long range and short range forces. Long range forces are forces by which bacterium interacts with a surface from a certain distance (50 nm). Various long range forces include Van der Waal forces and electrostatic forces. Short range forces on the other hand include hydrogen bonding, ion pair formation and steric interaction [8].

During plaque formation, bacteria can be considered as living colloidal particles and obeys laws of physical chemistry. However, they are very different from ideal colloidal particle, since the lack sharp surfaces and uniform composition. Three types of Van der Waal forces can be identified in plaque formation. Firstly, when 2 atoms approach each other, they get attracted by induction of dipoles [9]. This reaction is called London dispersion. Secondly, when a molecule reacts with an atom dipole - induced dipole reaction takes place which leads to Debye forces [9]. Thirdly, when 2 molecules approach each other dipole-dipole interaction takes place leading to formation of Keesom forces [9].



Charged particles on water are neutralized by a counter-charged layer that is distributed around. This is called as electrical double layer of stern. When the double layer of particle overlaps double layer of surface electrostatic interactions take place. If both surfaces have same charge, there will be repulsion and if they are dissimilar, it leads to attraction. After initial adhesion, a firm anchorage is established by specific interaction. This leads to

irreversible adhesion. The initial colonizers adhere to the pellicle through specific proteinaceous surface appendages which they possess known as a fimbriae. These fimbriae contain adhesins. For example, cells of the *Actinomyces viscosus* possess fibrous proteinaceous fimbriae which extend from the bacterial cell surface. Proteins on these bacterial cell surfaces interact with the proline rich proteins present in the dental pellicle. This results in firm attachment [8].

3. Secondary colonization and plaque maturation

These are microorganisms that do not adhere directly to the clean surface of the tooth itself but instead adhere to cells of bacteria already on the plaque mass i.e. are the initial colonizers. These microorganisms adhere to one another by a process known as coaggregation [8]. This process primarily occurs through the stereochemical interaction of protein and carbohydrate molecules located on the bacterial cell surface in addition to the less specific interactions resulting from hydrophobic, electrostatic and Van der Waals forces. Well characterized interactions of secondary colonizers with early colonizers include the coaggregation e.g. *Fusobacterium nucleatum* with *Streptococcus sanguis*, *Prevotella loescheii* with *A. viscosus* and *Capnocytophaga ochracea* with *A. viscosus*. Initially interactions are with Gram-positive organisms then with Gram-positive and Gram-negative organisms. In later stages of plaque formation, coaggregation between different Gram-negative species is likely to predominate. Some coaggregations have a specific morphological arrangement described as “corn-cob” formations often occur in dental plaque. It is characterized by a central core consisting of rod-shaped bacterial cells and peripheral cocci, e.g. coaggregation of *F. nucleatum* and cocci lead to formation of “corn-cob” (Fig. 3).

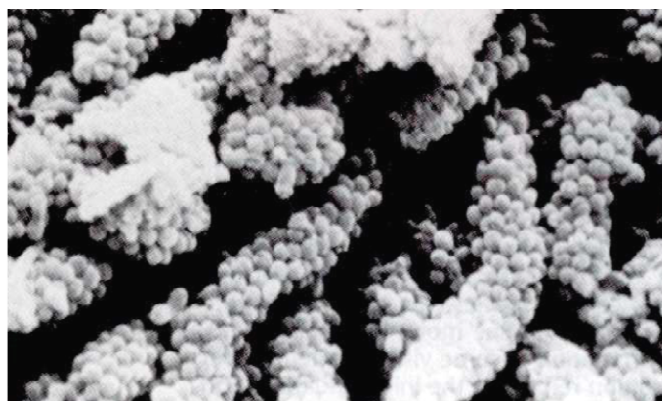


Fig. 3. Corn-cob formation [8].

6. PLAQUE HYPOTHESIS

The ideas about oral disease development have evolved overtime. In the nineteenth century, scientists could not identify bacteria related to disease due to the lack of technology. This led to proposal various hypotheses regarding plaque which include: non-specific plaque hypothesis, specific plaque hypothesis, unified theory, ecological plaque hypothesis, keystone-pathogen hypothesis, polymicrobial synergy and dysbiosis in inflammatory disease.

6.1. Non-specific plaque hypothesis

The non-specific plaque hypothesis was detracted in 1976 by Walter Loesche, a researcher at the University of Michigan. The non-specific plaque hypothesis maintains that periodontal disease results from the elaboration of noxious products by the entire plaque flora. According to this thinking when only small amounts of plaque are present, the noxious products are neutralized by the host. Similarly, large amount of plaque would produce large amounts of noxious products, which would essentially overwhelm the host defers. Inherent in the non-specific plaque hypothesis is the concept that control of periodontal disease depends on control of amount of plaque accumulation. Treatment of periodontitis by debridement and oral hygiene measures focuses on the removal of plaque and its products and is found in the non-specific plaque hypothesis [10]. Thus, although the non-specific plaque hypothesis has been discarded in favour of the specific plaque hypothesis, most of clinical treatment is still based on non-specific plaque hypothesis [8].

6.2. Specific plaque hypothesis

Specific plaque hypothesis was delineated in 1976 by Walter Loesche. The specific plaque hypothesis states that only certain plaque is pathogenic, and its pathogenicity depends on the presence of or increase in specific micro-organisms. This concept predicts that plaque harbouring specific bacterial pathogens results in periodontal disease, because these organisms produce substances that mediate the destruction of host tissues. Acceptance of the specific plaque hypothesis was spurred by the recognition of *Aggregatibacter actinomycetemcomitans* as a pathogen in localized juvenile periodontitis [10].

6.3. Unified theory

Socransky in 1979 abandoned the modern version of specific theory. He stated that periodontal diseases can be initiated by number of difference species rather than single periodontal pathogen. It was thus suggested that 6-12 bacterial species may be responsible for the majority of cases of destructive periodontitis. On the other hand non-specific theory supporters agree that some indigenous bacteria are commonly associated with disease than other. Theilade in 1986 suggested that both theories have very much common and unified theory is possible. He proposed that all bacterial plaque may contribute to the pathogenic potential of the sub-gingival flora to a greater or lesser degree by its ability to colonize and evade host defenses and provoke inflammation and tissue damage. Any composition of plaque in sufficient quantity in gingival crevice cause gingivitis but only in some cases does it lead to destructive periodontitis. Different indigenous bacteria predominate in difference stages of disease and in different persons and different sites within the same mouth. The increased virulence of sub-gingival flora seems to be due to the emergence of plaque ecology infavourable to the host, but favourable to growth of bacteria with pathogenic potential [11].

6.4. Ecological plaque hypothesis

In 1994 Philip D. Marsh proposed “Ecological plaque hypothesis”. According to this hypothesis changes in the environmental condition can lead to ecological shift. This ecological shift provides favourable environment for growth of pathogenic micro-organisms [12]. Marsh suggested that the changes in microbial composition are due to changes in ecological factors such as the presence of nutrients and essential cofactors, pH and redox potential. For example, frequent exposure to a low pH, for instance as the result of sugar fermentation, leads to a relative increase of acid-tolerant species [13].

Marsh also considered vice-versa i.e the bacteria in dental plaque change the environment. For instance, early colonizers of supragingival plaque are usually facultative anaerobic bacteria and use the oxygen, producing carbon dioxide and hydrogen. This in turn, lowers the redox potential giving strict anaerobes a chance to settle and multiply in the biofilm. Thus bacterial growth is dictated by the environment, which is influenced by bacterial metabolism, leading to mutual dependencies in health but also a chain of events that lead to diseases [14]. Thus inter-dependency of environment and micro-organisms on each other constitutes ecological plaque hypothesis.

6.5. Keystone pathogen hypothesis

The term keystone is also used to characterize a species which has a large effect on the ecosystem in spite of being in small number [15]. George Hajishengallis and colleagues applied this concept to (oral) microbiology by proposing “The keystone-pathogen hypothesis” (KPH) [16]. The KPH indicates that certain low-abundance microbial pathogens can cause inflammatory changes by increasing the quantity of the normal micro biota and also by changing its composition. For example, *Porphyromonas gingivalis* is shown to be able to manipulate the native immune system of the host [17]. Thus it was hypothesized that it does not only facilitate its own survival and multiplication, but that of the entire microbial community. In contrast to dominant species that can influence inflammation by their abundant presence, keystone pathogens can trigger inflammation when they are present in low numbers [16]. When disease develops and later stages are reached, the keystone pathogens are detected in higher numbers [18]. Importantly, even though their absolute number increases, keystone pathogens can decrease in levels compared to the total bacterial load which increases as plaque accumulates in periodontitis.

6.6. Polymicrobial synergy and dysbiosis in inflammatory disease

This was postulated by Lamont in 2015 [19]. When inflammation is uncontrolled of the periodontal area may arise when complex microbial communities transition from a commensal to a pathogenic entity. Communication among constituent species leads to polymicrobial synergy between metabolically compatible organisms that acquire functional specialization within the developing community. Keystone pathogens, even at little abundance, elevate community virulence, and the resulting dysbiotic community targets specific aspects of host immunity to further disable immune surveillance while promoting an overall inflammatory response. Inflammophilic organisms use the protein substrates derived from inflammatory tissue breakdown. Therefore Inflammation and dysbiosis reinforce each other, and increases the environmental changes further. The polymicrobial synergy and dysbiotic components of the process have been proposed as a new model for inflammatory diseases.

All presently available hypotheses are incapable of combining actual microbial and host behaviour that lead to maintenance of health or the shift to disease. An all-encompassing hypothesis is essential. But this can be only possible when substantial knowledge is obtained

between the complex relationships of the oral microbiome and the hosts' innate immune system. With the advancement of technology future studies will provide a more holistic view of the oral ecology and lead to a more clear view of mechanisms that govern change from health to disease [20].

7. ACQUISITION OF ORAL MICROFLORA

The mouth of newborn is usually lacks significant bacterial colonisation except that acquired from the mother's birth canal. Shortly after birth various bacteria are introduced in the oral cavity. The mouth is highly selective for micro-organisms even during the first few days of life. Only a few are able to colonize the mouth of the newborn. After the first feeding, microorganisms may transfer from maternal saliva or skin flora of mother and nursing staff. Microorganisms may also be transferred by various animate and inanimate objects the infant comes in contact with. By 24 hrs after birth, the first species have become established. At this stage, the most frequent colonizers of the oral cavity are Gram-positive cocci, including *Streptococcus* and *Staphylococcus* [21, 22]. The first species to colonise is called as pioneer species. These species grow until any resistance is encountered for instance nutritional restriction. After such a resistance a new community colonises. This concept is called microbial succession. Pioneer community progressively develops through several stages and when equilibrium is established it forms climax community. Climax community reinforces the importance of controlling pathogens but without deleterious effects in the remaining ecosystem.

The next major event occurs when hard non-shedding surfaces are available for microbial colonisation. After 1 year of age when teeth have erupted, *Streptococcus* spp., *Neisseria* spp., *Veillonella* spp. and *Staphylococcus* spp. are predominant. Less frequently isolated are *Lactobacillus*, *Actinomyces*, *Prevotella* and *Fusobacterium*. Tooth surfaces and gingival tissues provide new habitats for colonization, with resultant formation of dental plaque. In the later stages various appliances worn by an individual influences the oral flora. Orthodontic appliances harbour cariogenic species like *Streptococcus mutans* and *Streptococcus sobrinus* [23].

Hormonal changes in an individual can lead to changes in the oral flora as some hormones can serve as a source of nutrition to some gram negative anaerobic bacteria. Also, later age related changes, pregnancy and even psychological stress can influence the oral

microflora. In old age, if prosthetic appliances are worn, the colonization of *Candida albicans* in the oral cavity.

8. BACTERIAL COMPOSITION IN PERIODONTAL HEALTH

The bacteria cultivated from periodontally healthy sites consist of predominantly of Gram-positive facultative rods and cocci (approx. 75%). The recovery of this group of microorganisms decreased proportionally in gingivitis (44%) and periodontitis (10%) the decreases accompanied by increase on the proportion of Gram-negative rods. In periodontal health: Gram-positive species and members of genera *Streptococcus* and *Actinomyces* (e.g. *S. sanguis*, *S. mitis*, *A. viscosus* and *A. naeslundii*), small *P. intermedia*, *F. nucleatum* and *Capnocytophaga*, *Neisseria*, and *Veillonella* species. Certain bacterial species have been proposed to be beneficial to the host including *S. sanguis*, *Veillonella parvula*, *S. cochracea*. These species function in preventing the colonization and proliferation of other pathogenic micro-organism (e.g. is production of H₂O₂ by *S. sanguis*, H₂O₂ is to be lethal to cells of *Actinobacillus actinomycetemcomitans*) [18].

9. MICROBIAL COMPOSITION IN GINGIVITIS

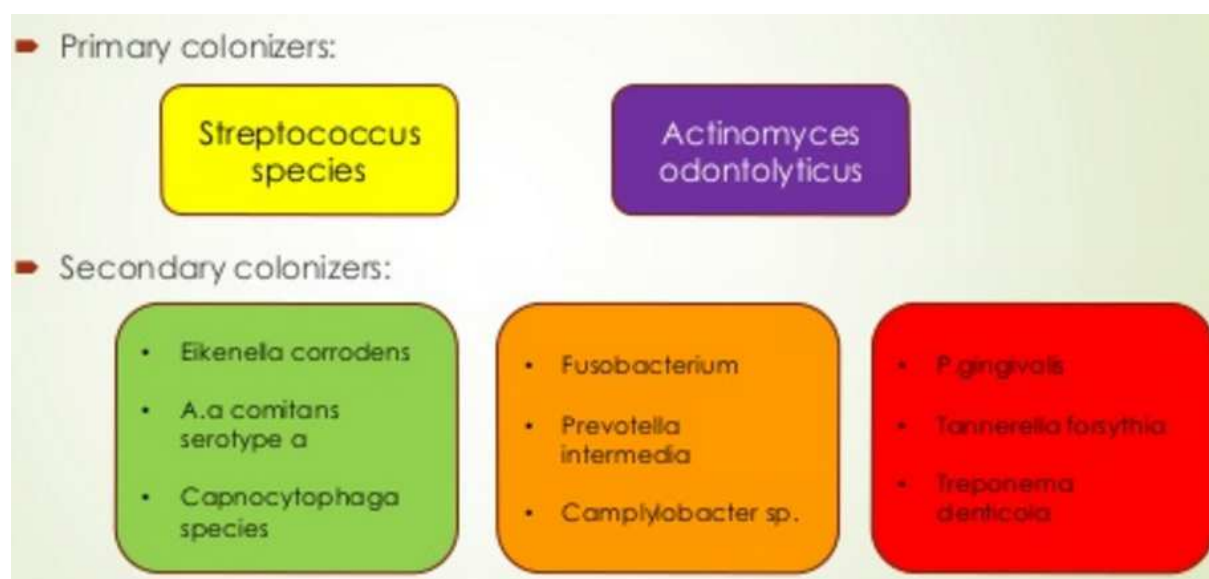
Gingivitis is non-specific inflammatory response of gingiva to dental plaque. It manifests as red and swollen gums often accompanied by pain and discomfort in gums. It usually results from non-specific proliferation of normal flora proliferation mainly due to improper oral hygiene. The transition from healthy gingiva to gingivitis is accompanied first by appearance of Gram-negative rods and filaments then by spirochetal and motile organism. The bacteria found in chronic gingivitis consist of roughly equal proportion of Gram-positive (56%) and Gram-negative (44%) species as well as facultative (59%) and anaerobic (41%) micro-organism [24]. Gram-positive species are *S. sanguis*, *S. mitis*, *A. viscosus*, *A. naeslundii*, *S. peptostreptococcus* and Gram-negative micro-organisms predominantly are: *F. nucleatum*, *P. intermedia*, *V. parvulla*, *Haemophilus* and *Campylobacter* species [25, 26].

10. MICROBIAL COMPOSITION OF PLAQUE IN CHRONIC PERIODONTITIS

Chronic periodontitis is inflammatory disease involving destruction of supporting tissues of teeth mainly alveolar bone and periodontal ligament. It is associated with varied micro-organisms. Chronic periodontitis is often preceded by gingivitis. However, not all gingivitis progresses to periodontitis. In some cases gingivitis exists for prolonged period. It manifests as gingival inflammation, bleeding from gingiva, tooth mobility, alveolar bone loss, malodour etc.

In a study by Socransky et al. in the year 1998 13,261 plaque samples from about 200 subjects were examined using whole genomic DNA probes and checkerboard analysis. 5 complexes were identified. The composition of the different complexes was based on the frequency with which different clusters of microorganisms were recovered [18].

Interestingly, the early colonizers are either independent of defined complexes (*Actinomyces naeslundii*, *A. viscosus*) or members of the yellow (*Streptococcus* spp.) or purple complexes (*Actinomyces odontolyticus*). The microorganisms primarily considered secondary colonizers fall into the green, orange, or red complexes. The green complex includes *Eikenella corrodens*, *Actinobacillus actinomycetemcomitans* serotype a, and *Campylobacter* species. The orange complex includes *Fusobacterium*, *Prevotella*, and *Campylobacter* species. The green and orange complexes include species recognized as pathogens in periodontal and non-periodontal infections. The red complex consists of *Porphyromonas gingivalis*, *Tannerella forsythia*, and *Treponema denticola* [18].



This complex is of particular importance as it is found in deeper periodontal pockets and also associated with bleeding on probing, which is an important clinical parameter of destructive periodontal diseases. Their presence is preceded by members of orange complex which are also found in deeper pockets. Thus chronic periodontitis is associated with a mixture of interacting bacteria.

Microbiological examinations of chronic periodontitis have been carried out in various cross sectional and longitudinal studies too. Microscopic examinations of plaque from sites with chronic periodontitis have consistently revealed elevated proportions of spirochetes [27]. Cultivation of plaque micro organism from sites reveals high percentages of anaerobic (90%), Gram-negative (75%) bacterial species [24].

In chronic periodontitis, the bacteria most often cultivated at high levels include *P. gingivalis*, *T. forsythia*, *P. intermedia*, *C. rectus*, *Eikenella corrodens*, *F. nucleatum*, *A. actinomycetemcomitans*, *P. micros*, *Treponema* and *Eubacterium* spp. [28-30]. When periodontally active sites (i.e., with recent attachment loss) were examined in comparison with inactive sites (i.e., with no recent attachment loss), *C. rectus*, *P. gingivalis*, *P. intermedia*, *E. nucleatum*, and *T. forsythia* were found to be elevated in the active sites. [31]. Furthermore, detectable levels of *P. gingivalis*, *P. intermedia*, *T. forsythia*, *C. rectus*, and *A. actinomycetemcomitans* are associated with disease progression [32] and elimination of specific bacterial pathogens with therapy is associated with an improved clinical response [33]. Both *P. gingivalis* and *A. actinomycetemcomitans* have been shown to invade host tissue cells, which may be significant in aggressive forms of adult periodontitis [34]. Recent studies have shown an association between chronic periodontitis and viral micro-organism of the herpes virus group, most notably Epstein-Barr virus 1 (EBV-1) and human cytomegalovirus (HCMV) [35]. Further, the presence of subgingival EBV-1 and HCMV are associated with high levels of putative bacterial pathogens such as *P. gingivalis*, *T. forsythia*, *P. intermedia* and *T. denticola*. This data is suggestive of viral infections may contribute to periodontal pathogenesis.

11. MICROBIAL COMPOSITION OF PLAQUE IN AGGRESSIVE PERIODONTITIS

Aggressive is a rare condition which usually occurs at a young age. Two forms of aggressive periodontitis have been described i.e. localised and generalised in localised forms

incisors and molars are particularly affected. In generalised forms many many teeth are severely affected. Usually there is little inflammation and individuals may not realize they have the disease. The amount of destruction does not correlate with the destruction that has occurred.

Microbiologic studies indicate that almost all disease sites harbor *Actinobacillus actinotryceterncomitans*, which may compose as much as 90% of the total cultivable microbiota. Other organisms, such as *Capnocytophaga* spp. and *Porphyromonas gingivalis*, may be synergistically associated with aggressive periodontitis [36].

12. CONCLUSION

Periodontal diseases are one of the most prevalent plaque associated diseases. Various changes occur in the microflora when the transition from health to disease occurs. Thus, it is imperative to know and understand the complex mechanisms involved in the shift from oral health to pathology which aids in establishing an accurate diagnosis and an efficient treatment plan for the periodontal diseases.

REFERENCES

1. Marsh PD, MV Martin. Oral microbiology. 3rd edn. Chapman and Hall, London, 1992.
2. Lang NP, Mombelli A, Attstrom R. Oral biofilms and calculus. In: Lindhe J, Lang NP, Karring T, editors. Clinical periodontology and implant dentistry. 5th edn. Oxford: Blackwell-Munksgaard; 2008, pp. 183-267.
3. Socransky SS, Haffajee AD. Biofilms dentales: objetivos terapéuticos difíciles. Periodontol 2000. 2003; 3: 12-55.
4. Lindhe J, Karring T, Lang NP. Clinical periodontology and implant dentistry. Blackwell Munksgaard Oxford, 5th edn., 2008.
5. Allison DG. The biofilm matrix. Biofouling. 2003; 19: 139-150.
6. Vu B, Chen M, Crawford RJ, et al. Bacterial extracellular polysaccharides involved in biofilm formation. Molecules. 2009; 14(7): 2535-2554.
7. Godoroja P, Dulghieru O. Propedeutics and preventive dentistry. Chisinau: CEP Medicina 2004: 99.
8. Newman MG, Takei HH, Klokkevold PR, Carranza FA. 10th edition. Carranza's clinical periodontology. Saunders Company, 2006.

9. Quirynen M, Bollen CM. The influence of surface roughness and surface-free energy on supra-and subgingival plaque formation in man. *Journal of Clinical Periodontology*. 1995; 22(1): 1-4.
10. Loesche WJ. Chemotherapy of dental plaque infections, *Oral Sci Rev*. 1976; 9: 65.
11. Theilade E. The non-specific theory in microbial etiology of inflammatory periodontal diseases. *J Clin Periodontol*. 1986; 13: 905-911.
12. Marsh PD. Microbial ecology of dental plaque and its significance in health and disease. *Adv Dental Res*. 1994; 8(2): 263-271.
13. Marsh PD. Dental plaque as a biofilm and a microbial community-implications for health and disease. *BMC Oral Health*. 2006; 6(1): S14.
14. Marsh PD. Microbiology of dental plaque biofilms and their role in oral health and caries. *Dental Clin North Am*. 2010; 54(3): 441-454.
15. Paine RT, Vadas RL. Calorific values of benthic marine algae and their postulated relation to invertebrate food preference. *Marine Biol*. 1969; 4(2): 79-86.
16. Hajishengallis G, Darveau RP, Curtis MA. The keystone-pathogen hypothesis. *Nature Rev Microbiol*. 2012; 10(10): 717-725.
17. Darveau RP. Periodontitis: a polymicrobial disruption of host homeostasis. *Nature Rev Microbiol*. 2010; 8(7): 481-490.
18. Socransky SS, Haffajee AD, Cugini MA, Smith C, Kent RL. Microbial complexes in subgingival plaque. *J Clin Periodontol*. 1998; 25(2): 134-144.
19. Lamont RJ, Hajishengallis G. Polymicrobial synergy and dysbiosis in inflammatory disease. *Trends Mol Med*. 2015; 21(3): 172-183.
20. Rosier BT, De Jager M, Zaura E, Krom BP. Historical and contemporary hypotheses on the development of oral diseases: are we there yet? *Frontiers Cell Infect Microbiol*. 2014; 4: 92.
21. Bagg J, MacFarlane T, Poxton L, Smith A. *Essentials of microbiology for dental students*. New York: Oxford University Press, 2006.
22. Hegde S, Munshi AK. Influence of the maternal vaginal microbiota on the oral microbiota of the newborn. *J Clin Pediatr Dent*. 1998; 22: 317-321.
23. Andrucioi MC, Nelson-Filho P, Matsumoto MA, Saraiva MC, Feres M, de Figueiredo LC, et al. Molecular detection of in-vivo microbial contamination of metallic orthodontic brackets by checkerboard DNA-DNA hybridization. *Am J Orthod Dentofacial Orthop*. 2012; 141: 24-29.
24. Slots J. Subgingival microflora and periodontal disease. *J Clin Periodontol*. 1979; 6: 351.

25. Mombelli A, Lang NP, Burgin WB, et al. Microbial changes associated with the development of puberty gingivitis. *J Periodontal Res.* 1990; 25: 331.
26. Moore WE, Moore IV. The bacteria of periodontal diseases. *Periodontol* 2000. 1994; 5: 66.
27. Listgarten MA, Hellden L. Relative distribution of bacteria at clinically healthy and periodontally diseased sites in humans. *J Clin Periodontol.* 1978; 5: 115.
28. Loesche WJ. Importance of nutrition in gingival crevice microbial ecology. *Periodontics.* 1968; 6: 245.
29. Socransky SS, Haffajee AD. Microbial mechanisms in the pathogenesis of destructive periodontal diseases: a critical assessment. *J Period Res.* 1991; 26: 195.
30. Kremer BH, Loos BG, van der Velden U, et al. *Peptostreptococcus micros* smooth and rough genotypes in periodontitis and gingivitis. *J Periodontol.* 2000; 71: 209.
31. Dzink JL, Socransky SS, Haffajee AD. The predominant cultivable microbiota of active and inactive lesions of destructive periodontal diseases. *J Clin Periodontol.* 1988; 15: 316.
32. Wennstrom JL, Dahlen G, Svensson J, et al. *Actinobacillus actinomycetemcomitans*, *Bacteroides gingivalis* and *Bacteroides intermedius*: predictors of attachment loss? *Oral Microbiol Immunol.* 1987; 2: 158.
33. Haffajee AD, Cugini MA, Dibart S, et al. Clinical and microbiological features of subjects with adult periodontitis who responded poorly to scaling and root planing. *J Clin Periodontol.* 1997; 24: 767.
34. Saglie FR, Marfany A, Camargo P. Intragingival occurrence of *Actinobacillus actinomycetemcomitans* and *Bacteroides gingivalis* in active destructive periodontal lesions. *J Periodontol.* 1988; 9: 259.
35. Contreras A, Slots J. Herpesviruses in human periodontal disease. *J Period Res.* 2000; 35: 3
36. Kornman KS, Robertson PB. Clinical and microbiological evaluation of therapy for juvenile periodontitis. *J Periodontol.* 1985; 56: 443.

Oral habits, malocclusion and postural changes in children

5

**Luciana R. P. Cruz¹, Luciana A. Bezerra²,
Dayvson S. Santos¹, Hilton J. da Silva²,
Genival de O. Ramos Júnior¹, Niedje S. de Lima¹,
Luciana B. C. Fontes¹**

¹ Federal University of Pernambuco, Department of Clinic and Preventive Dentistry , UFPE,
Av. da Engenharia, 14, Cidade Universitária, Zip Code 50670901, Recife, Brazil

² Federal University of Pernambuco, UFPE, Av. Moraes Rego, 1235, CDU, Zip Code 50670901,
Recife, Brazil

Copyright: © The Author(s) 2017. Licensee Joanna Bródka. This is an open access chapter licensed under the terms of the Creative Commons Attribution Non-Commercial 4.0 International License (<http://creativecommons.org/licenses/by-nc/4.0/>), which permits unrestricted, non-commercial use, distribution, and reproduction in any medium, provided the original work is properly cited.

ABSTRACT

In recent decades studies, it has been suggested that alterations in the Stomatognathic System as malocclusions can completely influence body posture. Postural alterations and body imbalance have been reported in oral breathing patients or those with malocclusions. However, there are some gaps in information about the possible relationship between these disorders, deleterious oral habits and malocclusions; this present study aimed. A cross-sectional pilot study was carried out between December 2015 and March 2016. In the statistical analysis the margin of error was 5%. The data collection was performed by anamnesis, physical examination and analysis of images obtained by computerized photogrammetry obtained from children between 10 and 12 years of age, in the mixed dentition phase, treated at a Dental Clinical School, in the Dentistry Department of a Public University in Recife. The variables investigated included age, gender, presence and type of deleterious oral habit, presence and classification of malocclusions and postural alteration. The sample was composed of 34 patients, 79.4% were 11 years-old and the others were 10.

Regarding gender criteria, 61.8% were male and 44.1% presented some type of deleterious oral habit, mainly digital suction. Malocclusions were present in 52.9% of the sample; Angle Class I was more frequent. Among the individuals evaluated, 64.7% had deviations in the head and shoulder positions. Angle class II malocclusion was significantly associated with the postural alteration characterized by anteriority of the head and the presence of deleterious oral habits.

Keywords: Malocclusion; Body posture.

1. INTRODUCTION

Habit is the custom or practice acquired by frequent repetition of the same act, at first consciously and subsequently, unconsciously. The deleterious oral or oral habits are highly related to the etiology of malocclusions and structural and functional alterations to the Stomatognathic System (SS), such as breathing, chewing, sucking, swallowing and phonoarticulation [1]. The degree of functional deviations provided by habits depends on the triad consisting of intensity, frequency and duration. These are added to the influence of individual predisposition, age, nutritional conditions and general health [2].

Psychosocial variables associated to the installation and/or change of these habits include the time spent by the mother to care for the child, the form of abandonment of the habit and access to guidance by health professionals, being very important the mother-son dyad. Socio-demographic and cultural diversities in the organization of the family environment are also related to the presence of deleterious oral habits, which justifies research in more vulnerable social groups or at risk populations [3].

Oral Breathing (OB) is a functional adaptation of the SS that leads to modifications in the organs, directly involved in the body dynamics as a whole; which allows its installation and continuity. This compromises the balance between the functions of this system.

A child who chronically breathes through the mouth, to breathe better, needs to adapt the posture of the head, preverting it so that the air arrives more quickly to the lungs. To compensate for this poor positioning, the spine and the rest of the body also change. As a result of the abnormal position of the head, an elevation of the scapula occurs and the chest region becomes depressed, making breathing quicker and shorter with a small action of the

diaphragm and leading to a projection of the child's abdomen. As an adaptive response to these muscular changes, the body tends to go forward and down, causing new compensations in the posture of arms and legs and so on [4]. Studies have evidenced the malfunctions of predominantly oral breathing in children and adolescents, including functional disorders and modifications in other organs and systems [5-7].

Similarly, deleterious habits related to masticatory muscles can also lead to postural changes and these would be responsible for changes in the posture of the head and shoulder, the hyoid bone and the lifting and lowering muscles of the mandible [8].

Swallowing is a coordinated activity with other oral functions and requires a close interaction between the muscles of the oral region and the tongue for the synchronization of movements. There are gaps in studies that evaluate head posture in children with atypical swallowing, a fact relevant for the diagnosis and treatment of this condition [9-11].

Another function of the SS, sucking, when performed for non-nutritive purposes, whether of fingers, pacifiers, tongue or others, is directly related to malocclusions. It is known that, in the same proportion as the shape of the dental arches is very influenced by the oral functions, occlusal and/or functional disturbances unbalance the muscular organization of the facial mime, the cervical region and the scapular girdle, with the feasibility of Orthostatic position of the head [12, 13]. However, there is a lack of studies that establish an association between these types of habits and body posture.

Scientific studies in the literature consulted showed that there are controversies and doubts about the interference of deleterious oral habits and body posture. Thus, the objective of this study was to verify the existence of an association between deleterious oral habits, malocclusion and postural changes in children without the diagnosis of oral breathing, with mixed dentures.

2. METHODS

The research project that underlies this chapter is linked to a broader research, approved by the Research Ethics Committee of the Federal University of Pernambuco (UFPE). There was respect for the Universal Declaration on Bioethics and Human Rights.

It represents a pilot study, transversal with the descriptive and inferential analysis of the data. The sample consisted of patients attended at the dental clinics of the UFPE Dentistry Course, in Recife, from the Pediatric Ambulatory of the Hospital das Clínicas of the same

Institution of Higher Education. Data collection occurred between December 2015 and March 2016.

As inclusion criteria in the sample we defined children between 10 and 12 years of age, of both genders, in the mixed dentition, without basic pathology or upper airway dysfunction, and also who were not yet in physiotherapeutic treatment and/or at the time of the evaluation. Exclusion criteria included the diagnosis of neurological impairment, congenital defects, diagnosis of oral breathing, use of orthodontic or functional orthopedic appliances of the jaws before the first evaluation or the need for other interventions in the dental clinic.

The Statcalc program of the Epi-Info software version 6.04 was used for the sample calculation, adopting a margin of error of 10% and a sampling power of 80%.

The list of variables included age, gender, presence and type of deleterious oral habit, presence and classification of malocclusion, and postural alteration between head and shoulder.

Data collection was performed through anamnesis, physical examination and analysis of images obtained by computerized photogrammetry; Is requested together with the orthodontic documentation, in a single Diagnostic Imaging Center. The information was recorded in standard form for the study and based on the parameters of the literature consulted [14-16].

The postural alteration was evaluated through the angles of the head and the shoulder [17]. The volunteers were photographed in frontal norm and in the left profile. They remained in the usual posture and with the eyes towards the horizon (towards the mirror), without occlusal contact of the teeth (keeping the functional space free) and with the arms along the body and the feet slightly apart. The angle between the head and the neck considered the mentum, the external acoustic meatus and the manubrium. For the shoulders the lower angle of the right and left scapula and the posterior angle of the right and left acromion, according to the adaptation of the parameters of Deda et al. in 2012 [17] and Neiva et al. in the year 2008 [18].

In the lateral view we observed a possible anterioration or retraction of the head in relation to the shoulders and a protrusion or retroversion of these. For this, an imaginary vertical line was drawn from the center of the shoulder joint to the earlobe. In the sequence the image data records for the postural analysis were captured by means of a digital camera on a tripod and the conversion of the images to posture data by the Biophotogrammetry software.




Fig. 1. Center of the shoulder joint and earlobe [17].

The occlusal evaluation was performed by students of the undergraduate course in dentistry, duly calibrated and under the supervision of two researchers. The examinations occurred with the child seated in the dental chair, under artificial light, with the use of Personal Protective Equipment (PPE) and wooden spatulas.

Changes in the occlusal normal pattern were considered in the anteroposterior direction. The occlusion of the children was evaluated in anteroposterior direction to allow classification of malocclusions as recommended by Angle (1989): Class I, Class II division 1, Class II division 2 and Class III [19].

Data were analyzed descriptively through absolute and percentage frequencies. To evaluate the hypothesis of a significant association between two variables the Pearson's Chi-square statistical test was applied. In the case where the Chi-square test condition was not checked, Fisher's Exact test was used. The margin of error used in the statistical test decisions was 5%. The data was entered in the EXCEL worksheet and the statistical program used to obtain the statistical calculations was the Statistical Package for the Social Sciences (SPSS) in version 23.

3. RESULTS

The sample of this research involved 34 patients (20% of the universe). The majority had: 11 years (79.4%) of age and the others were 10 years old and were male (61.8%). Table

1 shows the distribution of the children evaluated, according to the list of variables. Of the results contained therein a percentage greater than 50% corresponded to children who presented postural alteration and malocclusions; These being possible, for classification in the anteroposterior sense. In this table it is also possible to visualize the types of deleterious oral habits and malocclusions observed in the study patients. When the history of these habits arose, there were reports of two simultaneous habits by children with onicophagy: pacifier sucking (2) and bruxism (1).

Table 1. Distribution of children analyzed according to clinical variables. Recife - Pernambuco, 2016

Variable	n	%
TOTAL	34	100.0
• Postural alteration	22	64.7
Anteriorization of the head	11	32.3
Retraction of the head	4	11.8
Shoulder protrusion	7	20.6
Retroversion of the de shoulder	-	-
• Deleterious oral habits	15	44.1
Finger sucking	6	17.7
Pacifier sucking	4	11.8
Onicophagia	3	8.8
Bruxism	1	2.9
Atypical/Adapted swallowing	1	2.9
• Malocclusion	34	100.0
• Malocclusion classification according to Angle		
Class I	18	52.9
Class II (1 st division)	11	32.4
Class II (2 nd division)	5	14.7

All patients with a history of some type of deleterious oral habit had postural changes. The majority of children with Class II malocclusion had anterior head to shoulder, considering the sagittal plane. There was a significant difference when compared to the other standards established by Angle ($p < 0.001$), according to Table 2. This table also presents the study of the association between Angle malocclusion types, deleterious oral habits and

postural changes, where There was a significant association ($p < 0.001$). It was observed that: the presence of deleterious habits was lower among those classified in class I (11.1%) and ranged from 80.0% to 81.8% in the other two categories of class II.

Table 2. Malocclusion, anteriorization of the head and deleterious oral habits. Recife, Pernambuco, 2016

Variable	Angle Classification								P Value	
	Class I		Class II (1ª divisão)		Class II (2ª divisão)		Total			
	n	%	n	%	n	%	n	%		
TOTAL	18	100	11	100	5	100	34	100		
Anteriorization of head										
Yes	-	-	9	81.8	2	40	11	32.4	$p^{(1)} < 0.001^*$	
No	18	100	2	18.2	3	60	23	67.6		
• Deleterious habit										
Yes	2	11.1	9	81.8	4	80.0	15	44.1	$p^{(1)} < 0.001^*$	
No	16	88.9	2	18.2	1	20.0	19	55.9		

(*): Significant association at level 5.0%. (1): Fisher's Exact Test

4. DISCUSSION

This cross-sectional study describes a situation at an undefined moment, represented only by the presence or absence of a given aspect at the same moment or time interval analyzed, presenting as an instantaneous cut that is done in a population by Sample, examining in the members of the sample or sample the desired fact [20]. Thus, cross-sectional studies have the main advantage of being low-cost and almost no follow-up losses, except for those given by the exclusion criteria.

Likewise, factors such as sample size, for example, significantly interfere in the possibility of data inference as well as in the comparison of the results with the existing literature, the latter fact also given by differences in methodologies applied.

In the present sample, high percentages were found for the prevalence of malocclusions (52.9%) and deleterious oral habits (44.1%). Studies have recognized

deleterious oral habits as one of the risk factors for the development and complexity of malocclusions or malocclusions [1, 11, 17, 21].

The most frequent deleterious oral habit in the studied sample was digital suction (17.7%), followed by pacifier sucking (11.8%), onicofagia (8.8%), bruxism (2.9%) and atypical / adapted swallowing (2.9%). In contrast, another study [22] found pacifier suction as the most common habit in the investigated population (65.4%). This fact, however, is probably explained by the age of the children in the sample, who were between 3 and 5 years old, constituting a smaller age group.

The literature consulted also suggested the connection between malocclusion and postural alterations, especially between head and neck [22, 23] but it is necessary to explore and measure these variables more accurately, especially in the age groups characterized by periods of transitions and changes in the craniofacial complex. Neural connections exist between the cervical and trigeminal sensorimotor systems, showing that strong neuromusculoskeletal and neurophysiological connections are involved in the interrelationship between the orofacial and cervical regions. This reinforces the existence of simultaneous and coordinated activity between the neck and jaw muscles, however, this relationship has not yet been investigated in a more systematized manner [23].

In the present study, 64.7% of the children evaluated had head anterioration, 44.1% with a history of some deleterious oral habit, that is, in all patients with a history of deleterious oral habit, some postural alteration was observed. The majority of children with Class II malocclusion had anterior head to shoulder, considering the sagittal plane. There was a significant difference when compared to the other standards established by Angle ($p < 0.001$).

In this way, the knowledge of these factors and their detection by the dental surgeon is of immense importance for an early and effective intervention, in order to prevent the future consequences that these habits can bring, both aesthetic and functional and/or psychological [24, 25]. There is a need for a process of awareness of parents and caregivers regarding the implications of deleterious oral habits in children's lives, as well as guidelines on the non-traumatic withdrawal of these children. It also indicates the need for broader investigations, with similar methodologies to facilitate the comparison of results, in order to elucidate the gaps still present in the relationship between deleterious oral habits and postural changes clinically relevant to clinical practice.

5. CONCLUSION

Angle Class II malocclusion is significantly associated with the postural alteration characterized by anteriority of the head and the presence of deleterious oral habits.

REFERENCES

1. Jonanns CM, Silvério K, Furkim AM, Marchesan I. Is there a relation between harmful oral habits and facial typology and dental occlusion? *Revista CEFAC*. 2011; 13: 1095-1192.
2. Barbosa C, Vasquez S, Parada MA, Gonzalez JC, Jackson C, Yanez ND, et al. The relationship of bottle feeding and other sucking behaviors with speech disorder in Patagonian preschoolers. *BMC Pediatrics*. 2009; 9: 66.
3. Serra-Negra JMC, Vilela LC, Rosa AR, Andrade ELSP, Paiva SM, Pordeus IA. Deleterious oral habits: do children imitate their mothers when adopt these habits? *Rev Odonto Ciência*. 2006; 21: 146-152.
4. Machado PG, Mezzomo CL, Badaró AFV. Body posture and the stomatognathic functions in mouth breathing children: a literature review. *Rev CEFAC*. 2012; 14: 553-565.
5. Hitos SF, Arakaki R, Solé D, Weckx LLM. Oral breathing and speech disorders in children. *J Pediatría*. 2013; 89: 361-365.
6. Juliano ML, Machado MAC, Carvalho LBC, Santos GMS, Zacanella E, Prado LBF, et al. Obstructive sleep apnea prevents the expected difference in craniofacial growth of boys and girls. *Arquivos Neuropsiquiatria*. 2013; 71: 18-24.
7. Kuroishi RCS, Garcia RB, Valera FCP, Anselmo-Lima WT, Fukuda MTH. Deficits in working memory, Reading comprehension and arithmetic skills in children with mouth breathing syndrome: analytical cross-sectional study. *Sao Paulo Med J*. 2015; 133: 78-83.
8. Solovykh EA. Coordination of the stomatognathic and postural systems and their functional status. *Bull Exp Biol Med*. 2013; 155: 92-95.
9. Roggia B, Correa B, Pranke GI, Facco R, Rossi AG. Postural control of mouth breathing school aged children regarding gender. *Pró-Fono*. 2010; 22: 433-438.
10. Valera FC, Travitzki LV, Mattar SE, Matsumoto MA, Elias AM, Anselmo-Lima WT. Muscular, functional and orthodontic changes in preschool children with enlarged adenoids and tonsils. *Int J Pediatr Otorhinolaryngol*. 2003; 67: 761-770.
11. Machado Júnior AJ, Crespo NA. Postural evaluation in children with atypical swallowing: radiographic study. *J Sociad Brasil Fonoaudiol*. 2012; 24: 125-129.

12. Garbin CAS, Garbin AJI, Martins RJ, Souza NP, Moimaz SAS. Prevalence of non-nutritive sucking habits in preschoolers and parents' perception of its relationship with malocclusions. *Ciência Saúde Coletiva*. 2014; 19: 553-558.
13. Lopes JJM, Lucato A, Boeck EM, Kuramae M, Vedovello Filho M. Relationship between posterior crossbite and postural alterations in children. *Rev Gaúcha Odontol*. 2009; 57: 413-418.
14. Genaro KF, Berretin-Felix G, Rehder MIBC, Marchesan IQ. Orofacial myofunctional evaluation - MBGR Protocol. *Rev CEFAC*. 2009; 11: 237-255.
15. Drumond ALM, Marques Neto J, Monini AC, Nery CG, Lenza MA. Characteristics of the occlusion and prevalence of malocclusion in children treated at the Federal University of Goiás. *Rev Odontol Brasil Central*. 2011; 20: 36-40.
16. Dunbar AC, Bearn D, McIntyre G. The influence of using digital diagnostic information on orthodontic treatment planning - a pilot study. *J Healthcare Engin*. 2014; 5: 411-427.
17. Deda MRC, Melo-Filho FV, Xavier SP, Trawitzki LV. Head posture in the presence of class II and class III dentofacial deformities. *Rev CEFAC*. 2012; 14: 274-280.
18. Neiva PD, Kirkwood RN, Godinho R. Orientation and position of head posture, scapula and thoracic spine in mouth-breathing children. *Int J Pediatr Otorhinolaryngol*. 2009; 73(2): 227-326.
19. Bittencourt MAV, Machado AW. An overview of the prevalence of malocclusion in 6 to 10-year-old children in Brazil. *Dent Press J Orthod*. 2010; 15: 113-122.
20. Hochman B, Nahas FX, Oliveira Filho RS, Ferreira LM. Research designs. *Acta Cirúrgica Brasil*. 2005; 20: 2-9.
21. Bezerra PKM, Cavalcanti AL, Bezerra PM, Moura C. Malocclusion, breast feedint and deleterious buccal habits in preschool children - an association study. *Pesquisa Brasil Odontopediatria Clínica Integrada*. 2005; 5: 267-274.
22. Lippold C, Moiseenko T, Drerup B, Schilgen M, Végh A, Danesh G. Spine deviations and orthodontic treatment of asymmetric malocclusions in children. *BMC Musculoskel Disord*. 2012; 13: 151.
23. Siciauskiene M, Smailiene D, Lopatiene K, Cekanauskas E, Pribuisiene R, Sidlauskas M. Relationships between malocclusion, body posture, and nasopharyngeal pathology in pre-orthodontic children. *Med Sci Mon*. 2015; 21: 1765-1773.
24. Melo TMA, Carvalho CC, Cavalcanti AS, Dourado Filho MG, Pinheiro Junior PF, Silva HJ. Estudo das relações entre mastigação e postura de cabeça e pescoço - revisão sistemática. *Rev CEFAC*. 2011; 14: 327-332.

25. Vanegas GAM, Rubio AMG, Osorio LJP. Effects of unilateral mastication on the stomatognathic system and possible predisposing factors in schoolchildren from Medellin. *Rev Facultad Odontol Univ Antioquia*. 1996; 8: 41-52.

Saurabh Gupta

Facio-Maxillary Surgeon & Implantologist, Academic and Research Scientist, India

Mob: +91 9916203455; E-mail: saurabh.ravzz@gmail.com

Copyright: © The Author(s) 2017. Licensee Joanna Bródka. This is an open access chapter licensed under the terms of the Creative Commons Attribution Non-Commercial 4.0 International License (<http://creativecommons.org/licenses/by-nc/4.0/>), which permits unrestricted, non-commercial use, distribution, and reproduction in any medium, provided the original work is properly cited.

ABSTRACT

For many decades, dentistry has been uprising into a profession that is highly multi-faceted and varied to both facial and smile esthetics in its approach. The macro-esthetics (face), mini-esthetics (smile), and micro-esthetics (dental component) coordinate to offer a complete approach to esthetic treatment planning. The chapter presents a broad vision of aesthetic treatment designed to take readers to another stage of smile designing with dental implants that can increase patient results and outcomes.

Keywords: Esthetics; Smile; Implants.

1. INTRODUCTION

Implant dentistry is both an art and science. It is a challenging task that requires putting together anatomical, biochemical, biologic, gnathologic and esthetic knowledge in to a plan of treatment to provide the patients a satisfying and functional and long-term outcome [1].

It is essential to offer a lifelong guarantee for dental surgical work and long-term guarantee for prosthetic restoration, which exhibits the tendency of “material fatigue”. In everyday practice, as well as in teaching, there must be reliable clinical workflow and it

should include some predictable coordinates and parameters that are known to result in success. But every case encountered is unique. The challenge lies in being able to incorporate procedures and techniques in to treatment allowing predictability and effective, fast and minimally invasive procedures. The goal is to develop a treatment plan having benefits in the parameters of high-end esthetics and minimal invasiveness. Management of peri-implant tissues is concerned with providing natural outcome of a smile. By undergoing a specific protocol of treatment, satisfying results are achieved independent of the employed implant system [1, 2]. Such implant systems must have following common features:

- Self-cutting threads
- Platform switching design
- Insertion protocol using an undersized drill so as to obtain a good primary stability

2. PHILOSOPHY OF TREATMENT

Parameters for extraction of a periodontally compromised tooth

When a tooth gets so compromised periodontally that it must be extracted? When will be the periodontal treatments become a decision for inserting an implant? There are many articles reporting high success rates (having no radiographic changes) in case of immediate implant placement in fresh extraction socket of a periodontally compromised tooth [3-4].

Systemic and controversial antibiotics are used preoperatively, until the contrary trials have proved otherwise. Immediate implant placing and loading have shown to be clinically reliable having high rates of success.

Drawing from the current literature and on experience, it is reasonable to affirm that:

- rate of success in implant supported restoration in full-arch cases in the maxilla is 97% and for mandible at 98%.
- rate of pre-implants stands higher when prosthetic reconstruction includes the residual teeth having periodontal problems.

In case the periodontally treated tooth is mobile and is infected after one year of treatment, and height of residual bone is less than 10 mm, tooth must be extracted and implant placed. This is minimally invasive treatment, and prevents vertical grafting and gives the patient fixed construction [4-5]. The integration of tooth into implant construction is performed under these conditions, according to the recent studies, statistics and the experience

of the author, of the tooth has prognosis of 20 years, it can be integrated into implant construction [6-7].

In case, the tooth has prognosis of ten years and prosthetic reconstruction permits the tooth extraction, and it is possible to sustain prosthetic reconstruction with minor modifications, then the tooth can be taken for reconstruction [8]. If tooth has prognosis less than 5 years, it cannot be included in reconstruction.

Under the above-mentioned conditions, the prognosis for the restoration on the implants will be twenty years, of the patient has the occlusion and hygiene control and has a professional cleaning once every 4 months. Under these parameters, the individual diagnosis and planning are the next stage [8-9].

3. ESTHETIC ANALYSIS AND PLANNING

The esthetic analysis offers vertical dimension vs. crown height space (CHS). Planning of reconstruction in full-arch rehabilitation considers the vertical bone loss:

CHS: 8-12 mm: In this case, the immediate implant placing and loading are possible having high predictability of natural outcome of pink and white esthetics.

CHS 12-15 mm: The teeth would be more inclined in these cases. As part of restoration, pink component may be required. The technician has to work with appropriate inter-dental brush for allowing proper cleaning of the prosthesis that could be screw retained or cemented.

CHS >15 mm: In such cases, patient will be having significant pink component. Hence, the restoration has to be screw retained or be removable [9-12].

4. FUNCTIONAL ANALYSIS

A dysfunction of the cranio-mandibular and the muscular system can be diagnosed by the functional analysis, (either manual or instrumental). It is a well-known fact that the edentulous or partially edentulous patients could be having muscular dis-coordination, even if there are no symptoms observed. This discoordination could be drastic in case arch is restored on the implants, titanium or Zirconia abutments or e max crowns that do not exhibit resilience, tolerance or elasticity. The bite has to be balanced thoroughly. So, it is realized that occlusion should be perfect in habitual, centric and lateral movements [4-10].

5. RADIOLOGIC ANALYSIS

A 3-D (three dimensional) diagnosis is essential for precise work, more so while dealing with the bone defects. It is essential to understand the exact 3D shape and the architecture of the defect for knowing the design of the flap [3]. With advancements in digitization (3D printing) and cone beam computed tomography (CBCT) scan, it is now possible to perform truly guided surgery.

Guided implant surgery requires software as shown in the (Fig. 1). In this software program clinician and dental technician is able to virtually place the implant and run number of test for ensuring best location outcome [13-15].

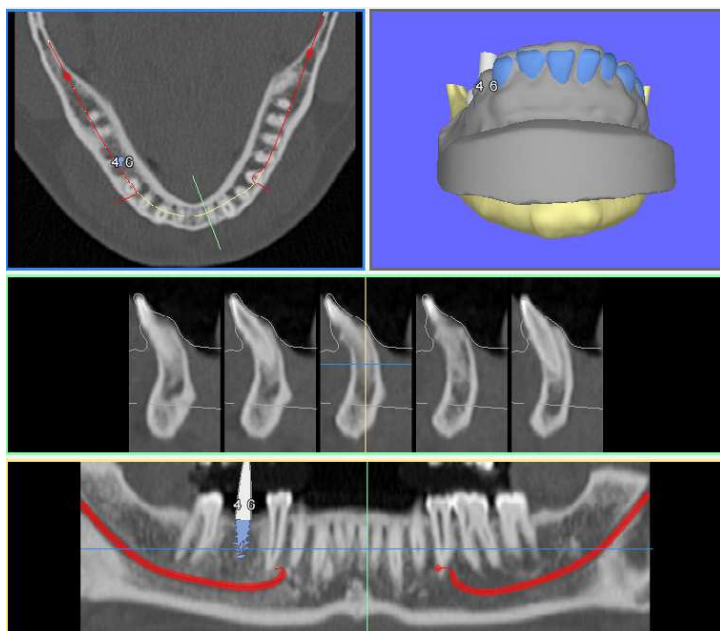


Fig. 1. Guided implant surgery planning software

6. PHOTOGRAPHIC AND VIDEO ANALYSIS

Communication with the patient has been made easier with the modern photo and video analysis by illustrating which of the parameters are necessary for harmonious integration of the teeth in orofacial system. The patient is also one of the 3D “parameters” whose character could be implemented and improved with the help of high quality support of

teeth [13-17]. Static records that are used to record the smile include radiographs, study models and film/digital photographs (Fig. 2).

The American Academy of Cosmetic Dentistry Photographic Accreditation Review of 1995 recommended that facio-maxillary photographs for aesthetic treatment planning should have full face smiling, full face showing lips relaxed, profile full smile, and left and right lateral views of full smile [17-20].

Digital videography is an additional tool for aesthetic smile evaluation. Videoclips recorded before, during, and after the treatment allows the dentist to check the dynamic display zone in the front view during facial animation; such videoclips can be utilise to comparison and assess the effects of aesthetic treatment and face change over time. In addition to this, the diagnostic information, which is acquired from dynamic visualization of the smiling face, video imaging has the potential to affect communication at staff meetings and consultations [21-26].

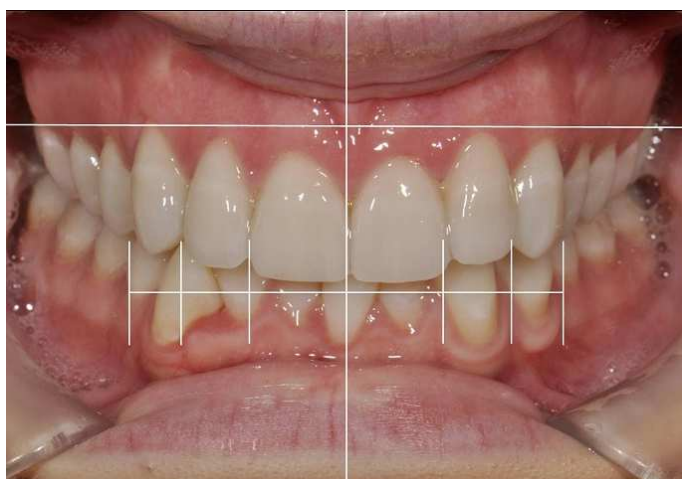


Fig. 2. Photographic analysis

7. PLANNING

The planning begins with creating digitally the “Golden ratio” of teeth, model transpositioning, and creating esthetic wax model or mock-up, which is sent for patient approval [30]. In case of full-arch rehabilitation, it is necessary to respect certain dimensions. As maxillary implants get inserted in palatal section of sockets, it is required for the technicians to measure inter-premolar distance to give the dimensions of initial dental crowns. The

overbite and overjet must be reduced to physiologic dimensions of 2 to 4 mm. larger modifications compared to initial dimensions can cause decreased space for tongue, cause phonetic problems, narrower jaw dimensions and enlarged black spaces compared to the pre-operative dimensions. Taking into consideration of all these parameters that ensure common workflow with the technician and common language, he or she will be ready to create a mock-up or wax-up of the ideal situation [31].

8. PRESURGICAL PROSTHETICS

If possible model of the mock-up will be prepared. In case of full arch rehabilitation, technician will make a provisional bridge beforehand by using the shell technique [13] (Fig. 3).

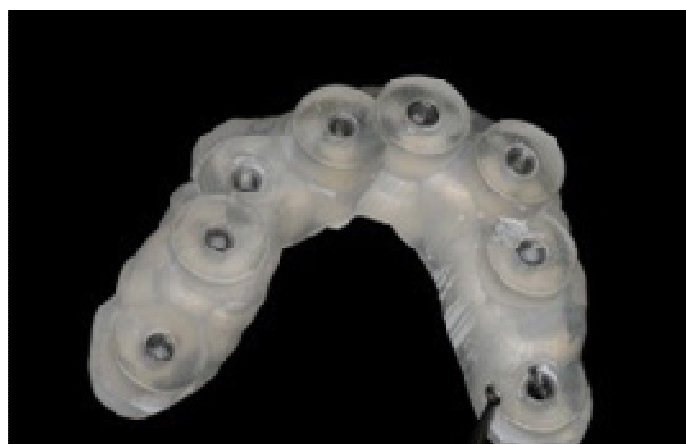

Fig. 3. Surgical guide

Premedication and general health of the patient is of paramount importance. In the bone graft procedure, an important parameter that needs to be controlled is the amount of Vitamin D. It is shown by histomorphometric analysis that bone-to-implant contact ratio (BIC) and bone volume surrounding the implant increased significantly in the group getting vitamin D supplement. The results show that supplementation of vitamin D is an effective approach for improving fixation of the titanium implants [5, 13].

9. IMPLANT PLACEMENT

The following positioning rules must be observed while performing implant placement

- 4 mm distant to buccal contour,
- 3 to 4 mm from free gingival margin must be achieved,
- 1 mm below bone level.

The sockets, which are intact, must be treated without raising flap. Gap is grafted with non-resorbable material. When socket is intact, thin tissue biotypes may also undergo connective tissue graft [5, 6, 29, 31]. In case of presence of buccal bone defect, the grafting of the socket can be done with nonresorbable material and is protected (by covering with collagen membrane Type III-IV with longer resorption time and a matrix that can implement tissue biotype same time, if possible).

10. IMPLANT DESIGN

When platform-switching design is employed, esthetic rehabilitation is more predictably achieved in implants having a polished collar and set below bone level. Platform switching has proved to prevent the bone loss on average by 0.6 mm instead of 1.4 mm. A concave contour of emergence profile better represents the peri implant tissue [6, 32, 33].

11. IMMEDIATE IMPLANT PLACEMENT, IMMEDIATE LOADING

Primary stability is the essential necessary condition for loading of an implant in the extraction socket: three fourth of surface of the implant must be covered by the bone and gap is grafted [7, 9].

12. IMPLANT SURGERY

In case of full arch reconstructions, there are similar rules, which are followed in case of single-tooth replacement. If the socket is intact, it is left intact. In case, the buccal plate is incomplete or found missing, after raising flap, the grafting should be performed by covering with a collagen membrane.

The implant placement should be driven by esthetic consideration. Grafting should be performed following rules of the defect architecture and host bone quality. Growth factors such as platelet rich fibrin can be added to bone material and one can use a fibrin membrane for covering the collagen membrane. This contributes to higher vascularization in the first two weeks of the healing by promotion of endothelial growth factor. After the required flap advancement, horizontal mattress suture, which is set at 1 cm off the line of incision, is to be placed to ensure tension free flap closure. The gingival portion will be attached and would heal properly with optimal vascularization [7, 33].

In order to encourage recovery of peri-implant structure, it is recommended to have prosthetic parts (healing abutments) to be concave. It should have 3 mm tissue height, 3 mm width of keratinized gingiva around implants and 3 mm thickness of gingival. These ensure long-term esthetic stability and bone stability [8, 30].

13. PROSTHETIC RECONSTRUCTION/PHILOSOPHY FOR MAXIMAL ESTHETIC OUTCOME

After healing, an impression must be taken to reconstruct the concave profile of the treated tissues, by use of provisional abutments as impression coping by the use of an impression cap. In esthetic zone, the individual abutments having slightly convex profile contribute to dynamic but of tender compression of papilla in inter-implant region. This will be of help to gain papilla length of approximately 0.5 mm. The construction of abutments must be done individually by using zirconia on the titanium base or e.max. The limit of preparation should be 0.5 mm below gingival margin of the future tooth [9, 12, 13, 29].

Then the next stage is the fabrication of crowns for imitation of natural dentition. The point of contact between the crowns is normally 42-43% of interdental space. By use of e.max ceramics it is possible to individually produce single crowns.

It is possible to perform cementation by using Variolink or Multilink for e.max ceramics. Before cementation cords must be inserted for preventing cement rests enter the sulcus that can cause peri-implantitis later. Patients should be given 20-year guarantee on the condition that they will maintain strict recall every four months for the hygiene control, occlusion control, remotivation and professional cleaning [10-11].

14. CERAMIC IMPLANTS - METAL FREE IMPLANTOLOGY - ESTHETICALLY DRIVEN

There is an increasingly prevalent idea that human bodies do not prefer to have any metal in them. In case multiple metals are there, a small voltage develops from a metal to metal and this is termed as galvanic reaction/corrosion. In case of ceramic materials, there is healthier tissue response and electric potential is absent [11, 12].

The ceramic/zirconia implants are being used for many years in dentistry. FDA gave the approval for the ceramic implants in 2007. There are many studies conducted that show that ceramic Implants show just the same over 95% success rate as with traditional titanium implants. Up to 2014, only one piece of ceramic implant and an abutment was used and this produced more of a possibility for movement and interference with the process of integration with the bone in the healing phase. Now, some companies have 2-piece zirconium implant and abutment.

Other advantages of ceramic are that Zirconia's white color removes the dark color, which can show during the tissue recession, less plaque buildup and healthier tissue response [12,13] (Fig. 4a, 4b).

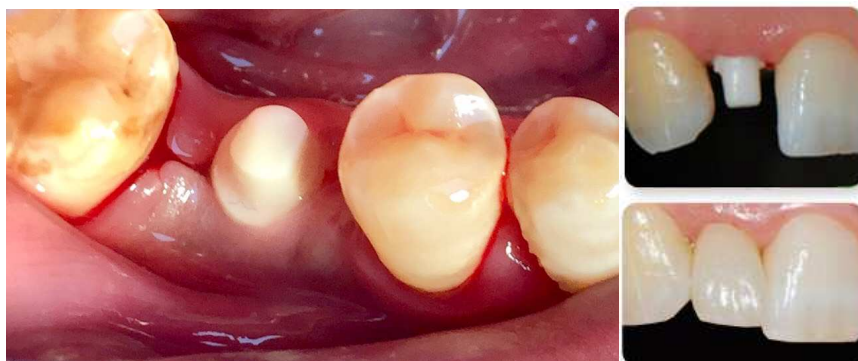

Fig. 4. a) Posterior ceramic implant, b) Anterior ceramic implant

15. CONCLUSION

Employing the rules of implant placement and well-known parameters leads to reproducible and predictable results. Esthetic planning needs good communication between the dental team and the patient, based on video and photographic documentation.

It is beneficial to be up to date with the latest materials, technologies and approaches for arriving at minimally invasive techniques, which at the same time provide maximum esthetic outcomes. Additionally, recently introduced and highly popular zirconia implants have proved to be promising in future. But, further in vitro and in vivo clinical studies are essential for making such recommendation.

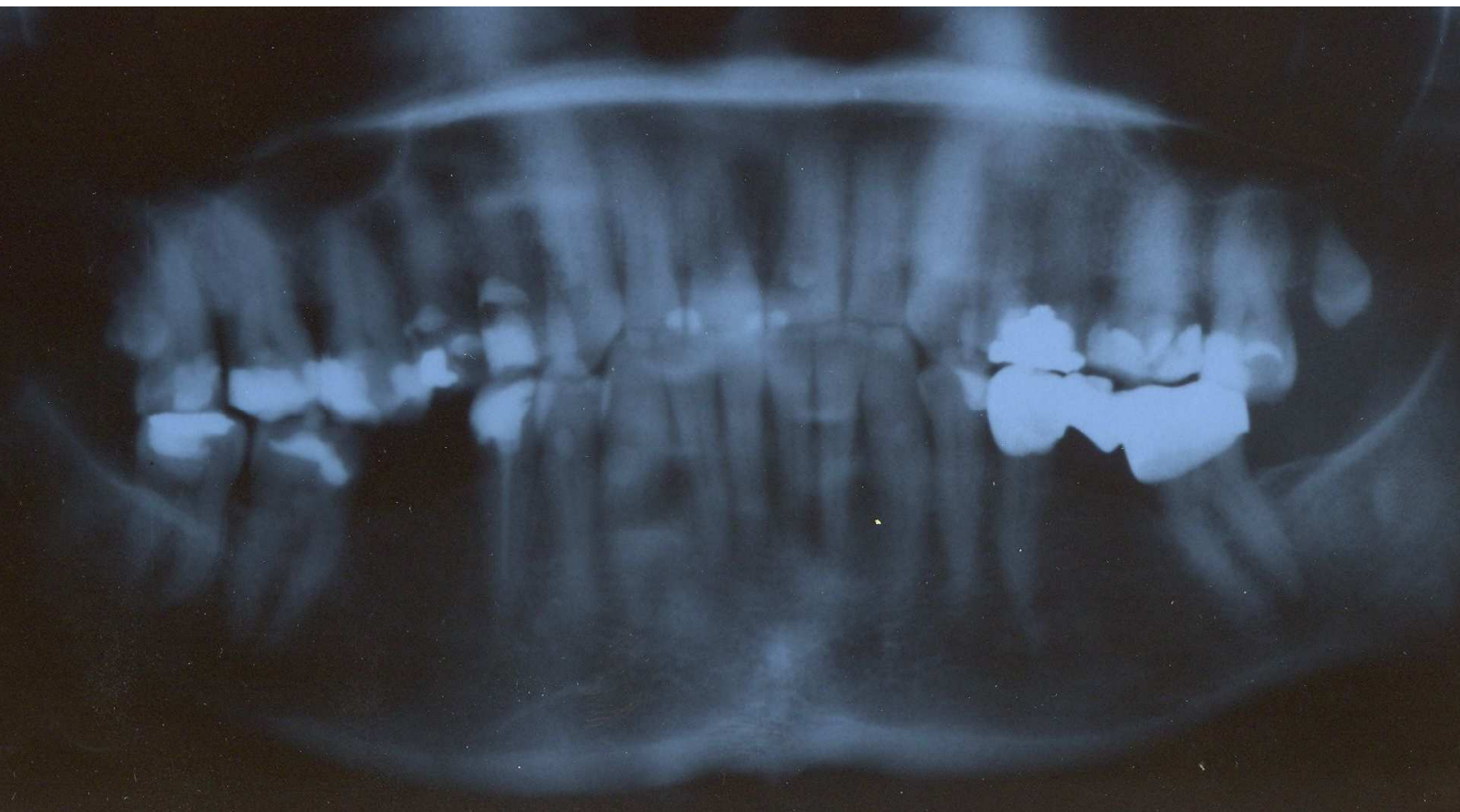
REFERENCES

1. Elamrousy WA, Nassar M, Ragheb AM, Alnomany FA, Marzok MA. Radiographic bone changes around immediately placed immediately restored dental implants in periodontally compromised sites. *Dentistry*. 2013; 3: 161.
2. Tripodakis AP, Nakou M. Microbiologic evaluation of compromised periodontal sites before and after immediate intrasocket implant placement. *Int J Period Restor Dent*. 2011; 31: 109-117.
3. Chen S, Buser D. Implants in post-extraction sites: a literature update. In: Buser D, Belser U, Wismeijer D, eds. *ITI Treatment Guide. Vol 3: Implants in extraction sockets*. Berlin: Quintessenz Verlag, 2008.
4. Quirynen M, Van Assche N, Botticelli D, Berglundh T. How does the timing of implant placement to extraction affect outcome? *Int J Oral Maxillofac Implants*. 2007; (Suppl 22): 203-223.
5. Sanavi F, Weisgold AS, Rose LF. Biologic width and its relation to periodontal biotypes. *J Esthet Dent*. 1998; 10: 157-163.
6. Chu SJ, Tarnow DP, Tan JHP, Stappert CFJ. Papilla proportions in the maxillary anterior dentition. *Int J Periodontics Restorative Dent*. 2009; 29: 385-393.
7. Linkevicius T, Puisys A, Vindasiute E, Linkeviciene L, Apse P. Does residual cement around implant-supported restorations cause peri-implant disease? A retrospective case analysis. *Clin Oral Implants Res*. 2013; 24: 1179-1184.
8. Misch CE. *Contemporary implant dentistry*. 3rd Edition. St Louis: Mosby, 2008.
9. Coachman C, Calamita MA. Digital Smile Design: a tool for treatment planning and communication in esthetic dentistry. *Quintessence of Dental Technology* 35. Chicago: Quintessence Publishing, 2012: 103.
10. Ghanaati S, Booms P, Orłowska A, et al. Advanced platelet-rich fibrin (A-PRF): A new concept for cell-based tissue engineering by means of inflammatory cells. *J Oral Implantol*. 2014; 40: 679-689.

11. Noubissi S. Ceramic dental implants. An alternative to titanium and titanium alloys. *Arch Cran Oro Fac Sci*. 2013; 1(3): 37-39.
12. Gupta. A recent updates on zirconia implants: a literature review. *Dent Implants Dentures*. 2016; 1: 1.
13. Gupta S. 3D Printing in dental implan- tology. *Dent Open J*. 2017; 4(1): e1-e3.
14. Schabel BJ, Baccetti T, Franchi L, McNamara JA. Clinical photography vs digital video clips for the assessment of smile esthetics. *Angle Orthod*. 2010; 80(4): 678-684.
15. Benrashid M, Moyers K, Mohty M, Savani BN. Vitamin D deficiency, autoimmunity, and graft-versus-host disease risk: implication for preventive therapy. *Exp Hematol*. 2012; 40: 263-267.
16. Spear FM. The maxillary central incisor edge: a key to esthetic and functional treatment planning. *Comp Contin Educ Dent*. 1999; 20(6): 512-516.
17. Kois JC. Diagnostically driven interdisciplinary treatment planning. *Seattle Study Club J*. 2002; 6(4): 28-34.
18. Paolucci B. Visagismo e Odontologia [Hair and makeup: and dentistry] [in Portuguese]. In: Hallawell P, ed. *Visagismo integrado: identidade, estilo, beleza [Hair and makeup: integrated: identity, style, beauty]*. São Paulo: Senac; 2009: 243-250.
19. Gürel G, Bichacho N. Permanent diagnostic provisional restorations for predictable re- sults when redesigning smiles. *Pract Proc Aesthet Dent*. 2006; 18(5): 281-286.
20. Paolucci B, Hallawell P, Sauer C, Coachman C, Ricci A, Calamita M, Yoshinaga LG, Gurel G. *Visagismo: a arte de personalizar o desenho do sorriso [Hair and makeup: the art of customizing the design of the smile] [in Portuguese]*. São Paulo: VM Cultural; 2011. Available from: http://www.neartdental.com.br/downloads/visagismo_braulio-paolucci.pdf
21. Morley J, Eubank J. Macroesthetic elements of smile design. *J Am Dent Assoc*. 2001; 132(1): 39-45.
22. Sarver DM. Soft-tissue-based diagnosis and treatment planning. *Clin Impress*. 2005; 14(1): 21-26.
23. Ackerman JL, Ackerman MB, Brensinger CM, Landis JR. A morphometric analysis of the posed smile. *Clin Orthod Res*. 1998; 1: 2-11.
24. Ackerman JL, Ackerman MB. Smile analysis and design in the digital era. *J Clin Orthod*. 2002; 36: 221-236.
25. Ackerman JL, Ackerman MB. Digital video as a clinical tool in orthodontics: dynamic smile analysis and design in diagnosis and treatment planning. In: McNamara JA Jr, ed. *Information Technology and Orthodontic Treatment*. Ann Arbor, Mich: Monograph 40,

- Craniofacial Growth Series, Department of Orthodontics and Pediatric Dentistry and Center for Human Growth and Development, The University of Michigan; 2003: 195-203.
26. Sarver DM. The face as the determinant of treatment choice. In: McNamara JA Jr, ed. *Frontiers of Dental and Facial Esthetics*. Ann Arbor, Mich: Monograph 38, Craniofacial Growth Series, Department of Orthodontics and Pediatric Dentistry and Center for Human Growth and Development, The University of Michigan; 2001: 19-54.
 27. Sarver DM, Ackerman MB. Dynamic smile visualization and quantification: Part 1. Evolution of the concept and dynamic records for smile capture. *Am J Orthod Dentofacial Orthop*. 2003; 124: 4-12.
 28. Janzen EK. A balanced smile - a most important treatment objective. *Am J Orthod*. 1977; 72: 359-372.
 29. Sarver DM. Videoimaging: the pros and cons. *Angle Orthod*. 1993; 63: 167-170.
 30. Tarantili VV, Halazonetis DJ, Spyropoulos MN. The spontaneous smile in dynamic motion. *Am J Orthod Dentofac Orthop*. 2005; 128: 8-15.
 31. Ackerman MB, Bresinger C, Landis JR. An evaluation of dynamic lip-tooth characteristics during speech and smile in adolescents. *Angle Orthod*. 2004; 74: 43-50.
 32. Dougherty HL. Clubs, quips, phrases, and hype: musing for the new millennium. *Am J Orthod Dentofac Orthop*. 2000; 117: 586-588.

JB BOOKS



ISBN 978-83-947078-1-1



9 788394 707811