



IntechOpen

Alopecia Management

An Update

*Edited by Trinidad Montero-Vilchez
and Salvador Arias-Santiago*



Alopecia Management - An Update

*Edited by Trinidad Montero-Vilchez
and Salvador Arias-Santiago*

Published in London, United Kingdom

Alopecia Management – An Update

<http://dx.doi.org/10.5772/intechopen.100976>

Edited by Trinidad Montero-Vilchez and Salvador Arias-Santiago

Contributors

Nuh Evin, Şeyda Guray Evin, María Librada Porriño-Bustamante, María Antonia Fernández-Pugnaire, Dogancan Sonmez, Cicek Hocaoglu, Nabeel K. Al Hamzawi, Mohammed S. Al Baaj, Trinidad Montero-Vilchez, Alberto Soto-Moreno, Clara Ureña-Paniego, Salvador Arias-Santiago

© The Editor(s) and the Author(s) 2023

The rights of the editor(s) and the author(s) have been asserted in accordance with the Copyright, Designs and Patents Act 1988. All rights to the book as a whole are reserved by INTECHOPEN LIMITED. The book as a whole (compilation) cannot be reproduced, distributed or used for commercial or non-commercial purposes without INTECHOPEN LIMITED's written permission. Enquiries concerning the use of the book should be directed to INTECHOPEN LIMITED rights and permissions department (permissions@intechopen.com).

Violations are liable to prosecution under the governing Copyright Law.



Individual chapters of this publication are distributed under the terms of the Creative Commons Attribution 3.0 Unported License which permits commercial use, distribution and reproduction of the individual chapters, provided the original author(s) and source publication are appropriately acknowledged. If so indicated, certain images may not be included under the Creative Commons license. In such cases users will need to obtain permission from the license holder to reproduce the material. More details and guidelines concerning content reuse and adaptation can be found at <http://www.intechopen.com/copyright-policy.html>.

Notice

Statements and opinions expressed in the chapters are those of the individual contributors and not necessarily those of the editors or publisher. No responsibility is accepted for the accuracy of information contained in the published chapters. The publisher assumes no responsibility for any damage or injury to persons or property arising out of the use of any materials, instructions, methods or ideas contained in the book.

First published in London, United Kingdom, 2023 by IntechOpen

IntechOpen is the global imprint of INTECHOPEN LIMITED, registered in England and Wales, registration number: 11086078, 5 Princes Gate Court, London, SW7 2QJ, United Kingdom

British Library Cataloguing-in-Publication Data

A catalogue record for this book is available from the British Library

Additional hard and PDF copies can be obtained from orders@intechopen.com

Alopecia Management – An Update

Edited by Trinidad Montero-Vilchez and Salvador Arias-Santiago

p. cm.

Print ISBN 978-1-80356-248-3

Online ISBN 978-1-80356-249-0

eBook (PDF) ISBN 978-1-80356-250-6

We are IntechOpen, the world's leading publisher of Open Access books Built by scientists, for scientists

6,500+

Open access books available

176,000+

International authors and editors

190M+

Downloads

156

Countries delivered to

Our authors are among the
Top 1%

most cited scientists

12.2%

Contributors from top 500 universities



WEB OF SCIENCE™

Selection of our books indexed in the Book Citation Index
in Web of Science™ Core Collection (BKCI)

Interested in publishing with us?
Contact book.department@intechopen.com

Numbers displayed above are based on latest data collected.
For more information visit www.intechopen.com




Meet the editors



Dr. Trinidad Montero-Vilchez is a dermatologist at the Virgen de las Nieves University Hospital (HUVN), Granada, Spain, and holds a Ph.D. with International Mention and Outstanding Cum Laude qualification from the University of Granada, Spain. She received the Sanitas MIR 2022 Award, which recognises the best internal medicine resident in Spain. She has also received multiple awards for his research, several of international scope.

Her fields of research focus on predictive and personalised medicine on how the non-invasive measurement of skin parameters could predict the response to different treatments. She participates as principal investigator and collaborator in several projects and has taken part as a speaker in several national and international congresses. She is a reviewer for several international journals and is editor of several special issues. She has more than seventy publications in high-impact scientific journals to her credit.



Dr. Salvador Arias-Santiago is a professor at the University of Granada, Spain, and head of the Dermatology Department, Virgen de las Nieves University Hospital (HUVN), recognised as the best dermatology department in Spain by the Best In Class awards. He is the director of the Cell Production and Tissue Engineering Unit (UPCIT), HUVN, and is the principal investigator of the Clinical and Translational Dermatology Group

TECe19 of the Biosanitary Institute of Granada. He holds a degree in Medicine and a Ph.D. from the University of Granada, Spain. He was awarded the extraordinary end-of-course prize and Sanitas prize for the best resident in Spain. He has published more than 300 articles. He is the principal investigator of six competitive projects and participates in more than twelve as a collaborating researcher. He is also a member of the board of directors of the Spanish Academy of Dermatology and Venereology (AEDV), a member of the Trichology and Psoriasis groups of the AEDV, and a former coordinator of the Epidemiology and Health Promotion group. He is the associate editor of *Actas Dermo-sifiliográficas* and was a member of the editorial team of the *Journal of the American Academy of Dermatology*. He has received more than thirty research awards. He has experience in the manufacture and clinical use of adipose tissue mesenchymal stem cells in various pathologies and his team has recently adapted an autologous human skin to a Good Manufacturing Practice (GMP) environment for clinical use in patients with severe burns, recognized with the Medalla de Andalucía 2018 awarded by the Junta de Andalucía. Dr. Arias-Santiago has supervised nine doctoral theses and more than twenty-five master's theses and tutored residents at the HUVN Dermatology Department. He enjoyed a Rio Hortega contract from the Instituto de Salud Carlos III and has experience as head of the Rio Hortega Contract Research Group.

Contents

Preface	XI
Section 1 Introduction	1
Chapter 1 Introductory Chapter: Alopecia Management – An Update <i>by Trinidad Montero-Vilchez, Alberto Soto-Moreno, Clara Ureña-Paniego and Salvador Arias-Santiago</i>	3
Section 2 Non-Cicatricial Alopecia	9
Chapter 2 An Updated in the Management of Alopecia Areata <i>by Alberto Soto-Moreno, Clara Ureña-Paniego, Trinidad Montero-Vilchez and Salvador Arias-Santiago</i>	11
Section 3 Cicatricial Alopecia	37
Chapter 3 Treatment of Frontal Fibrosing Alopecia and Lichen Planopilaris <i>by María Librada Porriño-Bustamante and María Antonia Fernández-Pugnaire</i>	39
Chapter 4 Surgical Management of Scarring Alopecia <i>by Nuh Evin and Seyda Guray Evin</i>	57
Section 4 Other Treatments	77
Chapter 5 Overview of the Role of 308 Monochromatic Excimer Phototherapy for the Treatment of Alopecia Areata <i>by Nabeel K. Al Hamzawi and Mohammed S. Al Baaj</i>	79

Section 5	
Psychological Management of Alopecia	95
Chapter 6	97
Psychological Aspect of Alopecia	
<i>by Dogancan Sonmez and Cicek Hocaoglu</i>	

Preface

Alopecia Management – An Update is a comprehensive edited book that brings together leading experts in the field to provide a timely and informative exploration of the latest advancements in alopecia management. This text serves as a valuable resource for health-care professionals seeking to enhance their understanding of and treatment approaches to different types of alopecia.

This collection of carefully curated chapters covers a wide range of topics related to alopecia. The chapters are presented in a cohesive and logical order, ensuring a smooth flow of information and insights.

Beginning with an overview of the different types and causes of alopecia, the volume delves into the emotional and psychological impact of the condition on individuals. It then progresses to discuss practical strategies for hair care, styling, and the selection of appropriate hair replacement options. Additionally, the book explores emerging therapies and technologies, offering readers a glimpse into the future of alopecia management.

We extend our heartfelt gratitude to the contributors of this volume, who have generously shared their expertise and experiences in the pursuit of improving alopecia management. Their dedication and commitment to advancing knowledge in this field are commendable.

We also express our sincere appreciation to everyone that has helped us, the academic editors, Dr. Trinidad Montero-Vilchez and Dr. Salvador Arias-Santiago, in our tireless efforts in shaping this volume. Their expertise and guidance have been instrumental in ensuring the quality and coherence of the content.

Lastly, we would like to acknowledge the invaluable support of our colleagues, assistants, and the publishing team at IntechOpen. Their professionalism and dedication have contributed to the successful completion of this project.

It is our hope that *Alopecia Management – An Update* will serve as a comprehensive and authoritative resource, enlightening readers and empowering them to navigate the challenges posed by alopecia. By providing a holistic view of the condition and presenting the latest advancements, we aspire to make a positive impact on the lives of those affected by alopecia and foster a greater understanding among the general readership.

Wishing you an enlightening and rewarding reading experience.

Trinidad Montero-Vilchez and Salvador Arias-Santiago
Dermatology Department,
Virgen de las Nieves University Hospital,
Granada, Spain

Section 1

Introduction

Chapter 1

Introductory Chapter: Alopecia Management – An Update

*Trinidad Montero-Vilchez, Alberto Soto-Moreno,
Clara Ureña-Paniego and Salvador Arias-Santiago*

1. Introduction

Alopecia involves a heterogeneous group of common skin disorders. This condition can be divided into non-cicatricial alopecia (a potentially reversible disease as the follicular epithelium is not replaced by connective tissue) and cicatricial alopecia (a permanent condition as the follicular epithelium is replaced by connective tissue causing injury of the follicular stem cell region [1, 2]).

The most common non-cicatricial alopecia are androgenic alopecia (AGA) and areata alopecia (AA). AGA is an androgen-dependent disorder, that happens in genetically susceptible patients, characterized by the change of scalp terminal hairs into miniaturized vellus hairs [3]. AGA is more frequent and more severe in older patients, with a prevalence of 80% among Caucasian men and 50% among women older than 70 years old [4, 5]. The male pattern hair loss is characterized by a progressive loss of hair in the frontal line, bitemporal line, and vertex while the female pattern hair loss is distinguished by a sparing frontal hairline with a crown diffuse central thinning. AA is an autoimmune disease caused in part by the loss of immune privilege in the hair follicle but its etiopathogenesis is not completely understood [6]. Patients with AA have a higher risk of developing other autoimmune disorders such as thyroid diseases, diabetes mellitus, and vitiligo [6]. The lifetime incidence of AA is approximately 2% worldwide [7]. Clinically, AA varies from the appearance of small, well-circumscribed patches of hair loss to a complete absence of body and scalp hair [8].

The most common cicatricial alopecia is frontal fibrosing alopecia (FFA). Genetic and hormonal factors, as well as, environmental variables may play a role in FFA [9]. The relation between this disease and sunscreen use is controversial in the literature [10]. FFA typically affects a postmenopausal woman. It is characterized by slow progression of hair loss in the frontal, temporal or frontotemporal scalp and eyebrows, with perifollicular erythema and scale around hair follicles [11]. A wide variety of other diseases can be also classified as cicatricial alopecia, such as lichen planus pilaris, chronic cutaneous lupus erythematosus, pseudopelade of Brocq or central centrifugal cicatricial alopecia.

2. Alopecia impacts on quality of life

Alopecia frequently affects visible areas, such as the scalp, and can lead to a significant impairment in the quality of life and social inhibition in patients. AGA

impairs quality-of-life (QoL) in both males and females, showed in lower rates in QoL scores, such as the Dermatology Life Quality Index (DLQI) [12], Hairdex scale [12], and Skindex-29 scale [13]. Moreover, AGA has a negative impact on sexual function in premenopausal women, reflected in a decreased FSFI compared to healthy females [14]. AA has also a great impact on patient's quality of life [15]. Impairments in DLQI as well as in alopecia-specific scores have been reported [16]. Role-emotional, mental health, and vitality domains seem to be the most affected [15]. Moreover, AA has a negative impact on anxiety, depression, and sleep quality both on patients and their cohabitants [17–19]. Sexual life is also impaired in patients with AA and their partners, showing that both males and females suffering from AA had decreased sexual quality of life with low Sexual Quality of Life for Females (SQOL-F) and Sexual Quality of Life for Males (SQOL-M) scores [19]. Furthermore, AA has been related to distressed personality (or Type D personality, TDp), a personality trait that has been associated with poor quality of life [17]. Although, few studies have evaluated the impact of FFA on QoL [20]. FFA is a cicatricial alopecia, typically appearing in postmenopausal women, one study found impairments in DLQI, anxiety and depression scores in patients with this disease [12]. Regarding other scarring alopecia there is scarce evidence regarding their comorbidities likely due to the low prevalence [20].

3. Alopecia treatments

There are scarce treatments approved for the treatment of this disease. In fact, topical minoxidil, oral finasteride, and low-level light therapy are the only Food and Drug Administration and European Medicines Agency-approved therapies to treat AGA. Nevertheless, there are many treatment options available used off-label for treating AGA, including other oral and topical modalities, hormonal therapies, nutraceuticals, PRP, exosome treatments, and hair transplantation [21]. There are different therapeutic options for AA, depending on the patient's age and AA severity. In patients with isolated patches of hair loss injections of potent corticosteroids are the best therapeutic options. In patients who refuse injections, potent topical corticosteroids could be considered the first-line therapy. If AA is extensive, systemic drugs are recommended. Systemic corticosteroids can be effective but long-term use is related to adverse events. Other systemic immunosuppressive agents that can be used in AA include methotrexate or azathioprine. JAK inhibitors, such as tofacitinib and baricitinib, are novel promising therapies for severe cases of AA [22, 23]. Topical corticosteroids, topical and oral minoxidil, 5-alpha reductase inhibitors, hydroxychloroquine, or isotretinoin can be used for AFF [24]. Topical corticoids are recommended, especially in the early inflammatory stage, but relapse occurs upon their discontinuation [21]. Potent topical steroids and calcineurin inhibitors reduce inflammation, but without any clear benefit in slowing the alopecia. Isotretinoin, acitretin, or finasteride could stop AFF [24]. Therapeutic options for other scarring alopecia will be directed toward the causative disease [2].

The number of patients consulting about alopecia and patients' and doctors' interest in this condition is rapidly increasing [25]. Moreover, treatments available for alopecia are also growing. In that way, this chapter will review the currently available treatment for AGA, FFA, and other scaling alopecia. Moreover, it will include a chapter about the psychological management of alopecia, due to the great psychologic impact this disease has, and a chapter about novel and less known treatments, such excimer phototherapy.

Author details

Trinidad Montero-Vilchez^{1,2*}, Alberto Soto-Moreno¹, Clara Ureña-Paniego^{1,2}
and Salvador Arias-Santiago^{1,2,3}


1 Dermatology Department, Virgen de las Nieves University Hospital, Granada, Spain

2 Instituto de Investigación Biosanitaria ibs.GRANADA, Granada, Spain

3 Dermatology Department, Faculty of Medicine, University of Granada, Granada, Spain

*Address all correspondence to: tmonterov@gmail.com

IntechOpen

© 2023 The Author(s). Licensee IntechOpen. This chapter is distributed under the terms of the Creative Commons Attribution License (<http://creativecommons.org/licenses/by/3.0>), which permits unrestricted use, distribution, and reproduction in any medium, provided the original work is properly cited. 

References

- [1] Hordinsky M. Scarring alopecia: Diagnosis and new treatment options. *Dermatologic Clinics*. 2021;**39**(3):383-388
- [2] Martinez-Lopez A, Montero-Vilchez T, Sierra-Sánchez Á, Molina-Leyva A, Arias-Santiago S. Advanced medical therapies in the management of non-scarring Alopecia: Areata and androgenic alopecia. *International Journal of Molecular Sciences*. 9 Nov 2020;**21**(21):8390. DOI: 10.3390/ijms21218390
- [3] Lolli F, Pallotti F, Rossi A, et al. Androgenetic alopecia: a review. *Endocrine*. 2017;**57**(1):9-17
- [4] Severi G, Sinclair R, Hopper JL, et al. Androgenetic alopecia in men aged 40-69 years: Prevalence and risk factors. *The British Journal of Dermatology*. 2003;**149**(6):1207-1213
- [5] Gan DC, Sinclair RD. Prevalence of male and female pattern hair loss in Maryborough. *The Journal of Investigative Dermatology. Symposium Proceedings*. 2005;**10**(3):184-189
- [6] Strazzulla LC, Wang EHC, Avila L, et al. Alopecia areata: Disease characteristics, clinical evaluation, and new perspectives on pathogenesis. *Journal of the American Academy of Dermatology*. 2018;**78**(1):1-12
- [7] Villasante Fricke AC, Miteva M. Epidemiology and burden of alopecia areata: A systematic review. *Clinical, Cosmetic and Investigational Dermatology*. 2015;**8**:397-403
- [8] Sterkens A, Lambert J, Bervoets A. Alopecia areata: A review on diagnosis, immunological etiopathogenesis and treatment options. *Clinical and Experimental Medicine*. 2021;**21**(2):215-230
- [9] Iorizzo M, Tosti A. Frontal Fibrosing alopecia: An update on pathogenesis, diagnosis, and treatment. *American Journal of Clinical Dermatology*. 2019;**20**(3):379-390
- [10] Porrino-Bustamante ML, Montero-Vilchez T, Pinedo-Moraleda FJ, Fernandez-Flores A, Fernandez-Pugnaire MA, Arias-Santiago S. Frontal Fibrosing alopecia and sunscreen use: A cross-sectional study of actinic damage. *Acta Dermato-Venereologica*. 2022;**102**:adv00757
- [11] Porriño-Bustamante ML, Pinedo-Moraleda FJ, Fernández-Flores Á, Montero-Vilchez T, Fernández-Pugnaire MA, Arias-Santiago S. Frontal Fibrosing alopecia: A histopathological comparison of the frontal hairline with normal-appearing scalp. *Journal of Clinical Medicine*. 15 Jul 2022;**11**(14):4121
- [12] Gonul M, Cemil BC, Ayvaz HH, Cankurtaran E, Ergin C, Gurel MS. Comparison of quality of life in patients with androgenetic alopecia and alopecia areata. *Anais Brasileiros de Dermatologia*. 2018;**93**(5):651-658
- [13] Gupta S, Goyal I, Mahendra A. Quality of life assessment in patients with androgenetic alopecia. *International Journal of Trichology*. 2019;**11**(4):147-152
- [14] Sancak EB, Oguz S, Akbulut T, et al. Female sexual dysfunction in androgenetic alopecia: Case-control study. *Canadian Urological Association Journal*. 2016;**10**(7-8):E251-E2E6

- [15] Velez-Muniz RDC, Peralta-Pedrero ML, Jurado-Santa Cruz F, Morales-Sanchez MA. Psychological profile and quality of life of patients with alopecia Areata. *Skin Appendage Disorders*. 2019;**5**(5):293-298
- [16] Huang KP, Mullangi S, Guo Y, Qureshi AA. Autoimmune, atopic, and mental health comorbid conditions associated with alopecia areata in the United States. *JAMA Dermatology*. 2013;**149**(7):789-794
- [17] Sánchez-Díaz M, Montero-Vílchez T, Cuenca-Barrales C, Molina-Leyva A, Arias-Santiago S. Prevalence and implications of type D personality in patients with alopecia areata: A marker of quality-of-life impairment and mood status disturbances, a comparative study. *Journal of the European Academy of Dermatology and Venereology*. 16 Nov 2022. DOI: 10.1111/jdv.18733 [Epub ahead of print]
- [18] Sánchez-Díaz M, Díaz-Calvillo P, Ureña-Paniego CA, Molina-Leyva A, Arias-Santiago S. Quality of life and mood status disturbances in cohabitants of patients with alopecia Areata: A cross-sectional study in a Spanish population. *International Journal of Environmental Research and Public Health*. 6 Dec 2022;**19**(23):16323
- [19] Li SJ, Huang KP, Joyce C, Mostaghimi A. The impact of alopecia Areata on sexual quality of life. *International Journal of Trichology*. 2018;**10**(6):271-274
- [20] Saceda-Corralo D, Pindado-Ortega C, Moreno-Arrones OM, et al. Health-related quality of life in patients with frontal Fibrosing alopecia. *JAMA Dermatology*. 2018;**154**(4):479-480
- [21] Nestor MS, Ablon G, Gade A, Han H, Fischer DL. Treatment options for androgenetic alopecia: Efficacy, side effects, compliance, financial considerations, and ethics. *Journal of Cosmetic Dermatology*. 2021;**20**(12):3759-3781
- [22] Rossi A, Muscianese M, Piraccini BM, et al. Italian guidelines in diagnosis and treatment of alopecia areata. *Giornale Italiano di Dermatologia e Venereologia*. 2019;**154**(6):609-623
- [23] Strazzulla LC, Wang EHC, Avila L, et al. Alopecia areata: An appraisal of new treatment approaches and overview of current therapies. *Journal of the American Academy of Dermatology*. 2018;**78**(1):15-24
- [24] Porriño-Bustamante ML, Fernández-Pugnaire MA, Arias-Santiago S. Frontal Fibrosing alopecia: A review. *Journal of Clinical Medicine*. 21 Apr 2021;**10**(9):1805. DOI: 10.3390/jcm10091805
- [25] Vano-Galvan S. Hair and scalp-related disorders are a trending topic in dermatology, with a significant increase in number of consultations in the last decade. *Journal of the European Academy of Dermatology and Venereology*. 2023;**37**(1):16-17

Section 2

Non-Cicatricial Alopecia

Chapter 2

An Updated in the Management of Alopecia Areata

Alberto Soto-Moreno, Clara Ureña-Paniego,

Trinidad Montero-Vilchez and Salvador Arias-Santiago

Abstract

Alopecia areata (AA) is the most frequent type of non-scarring alopecia after androgenetic alopecia. The lifetime risk of developing AA is approximately 1.7–2.1%, and its incidence is increasing over time. Clinically, it is characterized by circumscribed and smooth patches of alopecia with black dots. Several treatments have been used in AA including topical an oral minoxidil and corticosteroids. Although new treatment options are being developed and advances have been made in recent years, there is currently no preventive or curative treatment for AA and classical treatments produce variable results. The design of a treatment strategy for alopecia areata should be based on consensual decision-making with the patient, taking into account his or her preferences and the risk and benefit of each treatment. In this chapter, we review the treatment of AA.

Keywords: alopecia Areata, JAK-inhibitors, minoxidil, non-scarring alopecia, treatment

1. Introduction

Alopecia areata (AA) is the most frequent type of non-scarring alopecia after androgenetic alopecia. The lifetime risk of developing AA is approximately 1.7–2.1%, and its incidence is increasing over time [1, 2]. It is equally prevalent in males and females, but males tend to be diagnosed earlier and have a poorer prognosis [2–5]. AA affects adults and children but usually presents around 25–29 years [6]. AA has a worldwide distribution but regional and ethnic differences have been addressed, being Asians the most heavily affected (Harries). Additionally, AA has been associated with social deprivation and living in urban areas [6].

2. Pathogenesis

The main disorder underlying AA is the premature transition of hair follicles from anagen to catagen and telogen phase. Only anagen hair follicles are targeted by the aberrant immune response. This prompts dystrophy of the affected hair follicles, preventing them from successfully anchoring to the hair canal and leading

Follicle in Alopecia Areata

Anagen phase

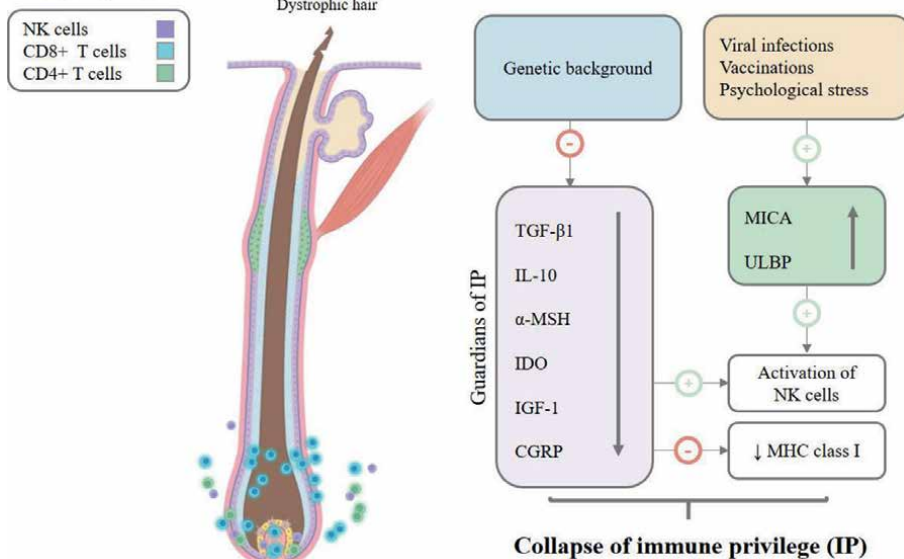


Figure 1.

Simplified pathogenesis of AA. A circled (+) implies the event the arrow is pointing to is encouraged while a (-) implies the opposite. The cornerstone of AA is the collapse of IP. Under normal circumstances, IP is preserved by the action of the IP guardians, which prevent antigen presentation through MHC class I and a down-regulation of NK cells via inhibition of MICA and ULBP. Certain insults combined with genetic predisposition lead to the weakening of these protective mechanisms and the development of AA. IP: Immune privilege; NK: Natural killer; MHC: Major histocompatibility complex; TGF-β1: Transforming growth factor-β1, IL: Interleukin; α-MSH: α-melanocyte stimulating hormone; IDO: Indoleamine-2,3 dioxygenase; IGF-1: Somatostatin, insulin-like growth factor; CGRP: Calcitonin gene-related peptide; MICA: MHC class I polypeptide-related sequence a; ULBP: UL16-binding protein.

to its shedding [7, 8]. Even when alopecia can prolong itself in time, the condition is reversible due to the fact that the bulge region of the hair follicle, that hosts stem cells, is spared from inflammation [9]. This phenomenon is induced by the complex interaction of immune-mediated mechanisms influenced by environmental triggers and genetic background (**Figure 1**).

Environmental triggers. Mental and biological stressors have been linked, albeit sometimes anecdotally to AA. Psychological stress directly affects the neuroendocrine-immune axis via corticotropin-releasing hormone (CRH), substance P and nerve growth factor, contributing to the development of AA [10–13]. Viral infections such as hepatitis B and C, swine flu, Epstein–Barr virus (EBV), and severe acute respiratory syndrome coronavirus 2 (SARS-CoV-2) have been hypothesized to induce AA [14–16]. Vaccination seems to exert a similar effect on the onset of AA [17, 18].

- **Immune factors.** Current evidence agrees that the main events leading to AA are the loss of immune privilege (IP) and a subsequent exacerbated inflammatory response revolving around the hair follicle. IP is an evolutionary adaptation in which certain key organs or structures are protected from harmful inflammatory immune response. Affected organs comprise the eyes, placenta, testes, central nervous system, and the proximal epithelium of the hair follicle [19]. In the case

of the hair follicle, IP is provided via physical and immune mechanisms. Physical mechanisms include a lack of lymphatic drainage and abundant extracellular matrix which hinder the invasion of immune cells [3, 13, 19]. Immune mechanisms consist of the protection of sequestered antigens from being presented and prevent the subsequent activation of natural killer (NK) cells. Antigens are secured from immune recognition by the downregulation of major histocompatibility complex (MHC) class I of IP guardians. These are transforming growth factor- β 1 (TGF- β 1), interleukin-10 (IL-10), α -melanocyte stimulating hormone (α -MSH), indole-amine-2,3 dioxygenase (IDO), somatostatin, insulin-like growth factor (IGF-1) and calcitonin gene-related peptide (CGRP) among others [20–23]. Even when preventing MHC class I antigen presentation contributes to IP, this also activates NK cells (“missing self”) [24]. Within the hair follicle, NK are thus held back by inhibiting its activating factors such as MHC class I polypeptide-related sequence A (MICA) and UL16-binding protein (ULBP). Under normal conditions, MICA and ULBP are downregulated in the hair follicle environment [3, 11, 25].

Failure of the security mechanisms outlined above leads to the collapse of IP. Oxidative stress and pro-inflammatory signals such as interferon- γ (IFN- γ), interleukin 15 (IL-15), and substance P can result in the attack of anagen hair follicles in predisposed individuals. In fact, both IL-15 and IFN- γ pathways operate through Janus kinase (JAK) signaling which explain the novel success of JAK inhibitors in the treatment of AA and that will be further reviewed in this chapter [26–28].

- Genetic predisposition. Like other immune-mediated conditions, a genetic component is present even when no monogenic cause has been identified [29]. First-degree relatives of patients have a risk of 5.7–7.8% of developing AA, while for monozygotic twins is of 42–55% [14, 30]. Observational association studies and genome-wide association studies have shown multiple genes related to AA including immune-related, human leukocyte antigen, and hair follicle-related genes [29, 31–34]. Treatment strategies reviewed in following sections will address the aforementioned targets involved in the pathogenesis of AA.

3. Diagnosis

3.1 Clinical features

AA presents as circumscribed and smooth patches of non-scarring alopecia. AA can affect any hair-bearing region, including not only the scalp but also eyebrows (**Figure 2a**), eyelashes, beard (**Figure 2b**), and any hair-bearing location. Even when patients are usually asymptomatic, some report a tingling or itchy sensation within the alopecia patches. Course of the disease is unpredictable, but spontaneous hair regrowth is observed in approximately 50% of patients with patchy AA within a year. In these cases, regrowth phase hair lacks pigmentation or is hypopigmented. Nevertheless, recurrence rate is high [3, 35–37]. In case pruritus, redness, scales, or scarring is present, it is primal to exclude tinea capitis.

The main AA subtypes are as follows:

- Patchy AA. Presence of single or multiple patches of alopecia affecting the scalp. Disease duration and treatment response need to be closely monitored, since

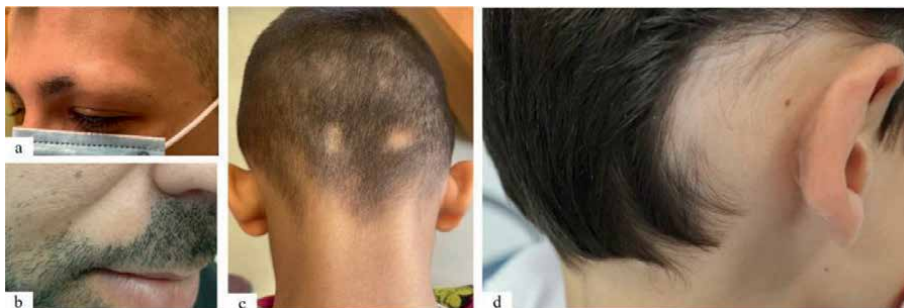

Figure 2.
Clinical manifestation of alopecia areata.

patients with persisting disease (beyond 1 year) can transition to AA totalis and universalis in a 30 and 15%, respectively [38] (**Figure 2c**).

- Ophiasis subtype. Alopecia patches converge along the occipital hairline toward the temples (**Figure 2d**). Sisaipho (ophiasis spelled backward) is another subtype in which alopecia follows an opposite pattern to the ophiasis subtype, sparing the periphery of the scalp and affecting the central scalp region.
- **AA totalis**. Complete scalp hair loss.
- **AA universalis**. Complete body hair loss.

AA incognito and diffuse AA. Both subtypes that have been recently described are not yet academically standardized [39]. They present as widespread hair loss without clear alopecic patches that can develop in a few weeks in AA incognito or over a more prolonged period of time, such as in diffuse AA. Even when trichoscopy can hint at the correct diagnosis, scalp biopsy is usually required to distinguish these conditions from telogen effluvium [28, 40].

Nails can also be affected, especially in the most severe forms of AA, such as AA universalis and AA totalis. Nail changes can present as pitting, trachyonychia, onychorrhexis, or non-specific nail dystrophy that may cause pain and cosmetic disfiguration. Findings can precede or be concurrent to the onset of AA.

Pull test, which consists on gently traction of hair at periphery of the alopecia patch, will be positive when disease is active, revealing dystrophic anagen and telogen hairs [41, 42].

The diagnosis of AA is clinical and can be made taking into consideration the aforementioned clinical features. Nevertheless, the role of trichoscopy has proven to be valuable when assessing AA, its activity state and to identify rare forms of AA [43]. Active patches of AA display yellow dots, exclamation mark hairs, and broken hairs as well as Pohl-Pinkus constrictions (**Figure 3**). Conversely, inactive patches can be identified by the presence of yellow dots and vellus hairs. Pigtail hairs and upright regrowing hairs can be spotted during remission [44–48].

3.2 Disease severity

Clinical classification of AA in subtypes provides the clinician with some insight of the severity of AA. Nevertheless, this classification system is insufficient for

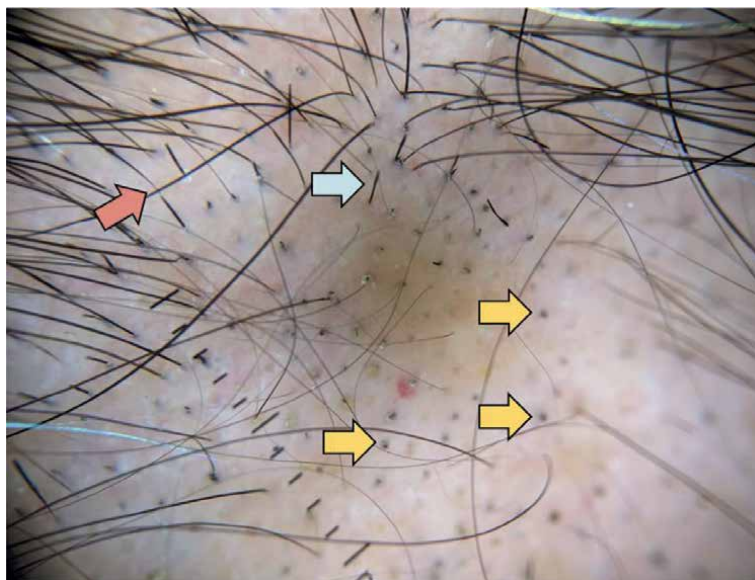


Figure 3. Trichoscopic image of active AA. Red arrows: Pohl-Pinkus constriction; yellow arrows: S black dots; white arrow: Exclamation mark hair. Image courtesy of Dr. Díaz-Calvillo.

describing the extent of the alopecia and does not allow for assessing response to treatment. The Severity Alopecia Tool (SALT) is a visual scoring system in which the scalp surface area is divided in four views and each view (back, sides, and top view) in quadrants. The clinician assesses and adds the areas affected by alopecia, and a final score is rendered. A scoring higher than 50% is considered severe (**Figure 4**) (Olsen). Other validated scoring systems with similar methodology have been conceived for accounting for eyelashes and eyebrows such as the Brigham Eyebrow Tool for Alopecia (BETA) and the Brigham Eyelash Tool for Alopecia (BELA), respectively [49, 50].

3.3 Prognosis

Early onset, family history of AA, severe forms such as AA totalis or universalis, ophiasis, nail disease, and atopic dermatitis are factors associated with a poor prognosis [4, 40, 51–53].

3.4 Histopathology

Scalp biopsies are occasionally required in cases in which diagnosis is uncertain as it remains the gold standard. Usually, a punch biopsy at the activity border of the lesion is taken. Histopathological findings depend on the duration of the AA episode. Overall, the main feature is the presence of peribulbar lymphocytic infiltrate [28, 40]. During episodes of active hair shedding, peribulbar lymphocytic infiltrates mainly composed of lymphocytes, Langerhans cells and to a lesser extent, plasma and mast cells as well as eosinophils. This arrangement receives the name of swarm of bees. In chronic phases, inflammatory infiltrates are still present, although less evident and there is an abundance of follicles in telogen and catagen stages [28, 40]. Syphilitic alopecia does not only resemble AA clinically but also histologically. A lack

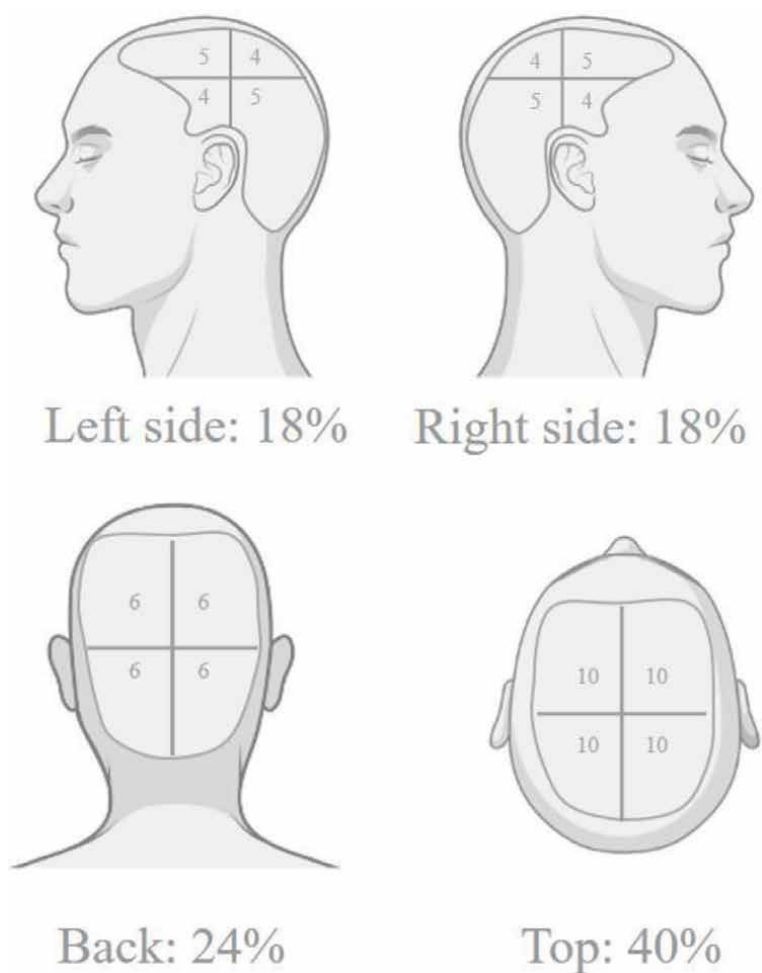


Figure 4. *The severity alopecia tool (SALT) visual aid allows the evaluator to estimate the percentage of alopecia surface via adding the values of the affected quadrants.*

of miniaturized follicles and eosinophils and the presence of spirochetes may aid the diagnosis of syphilitic alopecia [54–56].

3.5 High-frequency ultrasonography (HFUS)

Recently, HFUS has gained some attention on the diagnosis and follow-up of hair disorders. HFUS allows to visualize deep structures in the scalp skin such as subcutaneous tissue below hair follicles. Hair follicles present with lower echogenicity than the surrounding tissue in HFUS. A group of Polish researchers characterized the findings found in different stages of AA. Active stage of AA showed presence of distinct, drop-shaped follicular structures, while during inactive stages follicular structures are reduced and undefined [57, 58].

4. Associated diseases

Several medical conditions have been linked to AA. Skin disorders such as vitiligo, psoriasis, or atopic dermatitis (as well as atopic triad) were more commonly found in AA patients compared with healthy individuals. Furthermore, the association with thyroid disease and lupus erythematosus has been reported [59, 60]. This association is likely due to shared genetic loci and cytokine profiles [31, 32]. Patients with genetic conditions such as Down syndrome and polyglandular autoimmune syndrome type 1 show increased incidence of AA [61, 62]. Psychiatric comorbidities have also been reported in AA patients, but causality remains obscure since hair loss can increase anxiety and mood disorders [63, 64].

5. Treatment options and management of alopecia areata

Although new treatment options are being developed and advances have been made in recent years, there is currently no preventive or curative treatment for AA and classical treatments produce variable results [65]. The design of a treatment strategy for alopecia areata should be based on consensual decision-making with the patient, taking into account his or her preferences and the risk and benefit of each treatment [66] (**Figure 5**).

5.1 Psychosocial support and cosmetic options

The psychological impact of AA in children and adults may make the patient desire treatment regardless of clinical severity, and, on the other hand, makes psychosocial support by the physician part of the therapeutic arsenal in AA [67].

As a complement to medical treatment, or as the only measure in patients who refuse medical treatment, there is a wide range of cosmetic resources that the physician should be aware of: wigs, eyebrow tattooing, synthetic eyelashes, sprays, or lotions designed to make hair look fuller can be useful in AA [68].

5.2 Local treatment options

5.2.1 Topical and intralesional corticosteroids

5.2.1.1 Topical corticosteroids (Cs)

High-potency (class 3–4) topical Cs applied once daily to the lesion and 1 cm of healthy perilesional skin are the most frequent treatments for limited patches in adult patients who refuse intralesional therapy or in pediatric patients [69, 70]. The relapse rate of topical therapy varies from 37 to 63% [69]. A response evaluation should be performed after 3 months of treatment and discontinued if there has been no response after 6 months [70].

Possible adverse effects are folliculitis, atrophy, stretch marks, telangiectasias, and acneiform eruptions [69]. Medium potency Cs are recommended for use on face and beard areas [70].

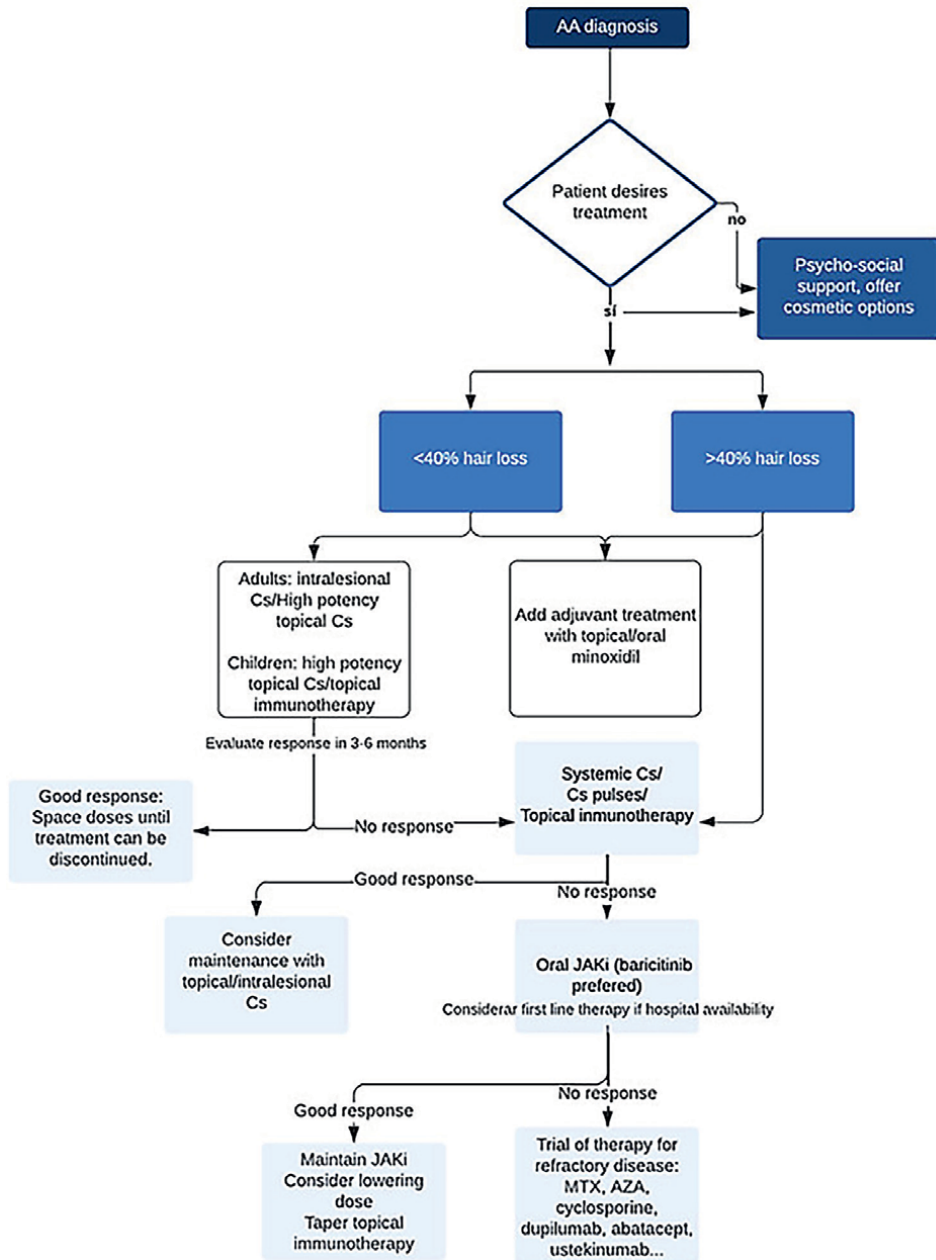


Figure 5. Treatment strategy for alopecia areata. AA: Alopecia areata. Cs: Corticosteroids. JAKi: JAK inhibitors. MTX: Methotrexate. AZA: Azathioprine.

5.2.1.2 Intralesional corticosteroids

Considered the first-line treatment for adult patients with one or two small patches, preferred in the active phase of AA, when a positive hair pull test and exclamation mark hairs are present [69, 70]. Small volumes (0.1 ml or less) are

injected into multiple sites 1 cm apart, and new growth is usually visible within 6 to 8 weeks [69, 70]. Treatment with intralesional Cs should be discontinued if there is no response at 6 months [70].

The most common adverse effect, local atrophy, can be minimized by limiting the volume injected, injecting not too superficially and using triamcinolone hexacetonide (class 2 glucocorticosteroid) [69].

5.2.2 Topical immunotherapy

Immunotherapy may be a good treatment option in patients with more than 50% of the scalp affected [71]. It is based on inducing a local allergic contact reaction [69]. The mechanism of action of topical immunotherapy is unknown, but it is believed to have an immunomodulatory effect on the inflammatory infiltrate surrounding the hair follicles [71].

Topical immunotherapy can be performed with diphenylcyclopropenone (DPCP), squaric acid dibutyl ester (SADBE), or dinitrochlorobenzene (DNCB) [71]. DPCP is often preferred over SADBE because it is less expensive, safer, and more stable in solution [69]. In the literature, success rates vary from 9 to 87%, but one systemic review described an average of 53.7% [69, 72].

Longer courses of DPCP therapy are required to consider therapeutic failure (6–12 months) [71]. The main side effects are cervical/occipital lymphadenopathy, disseminated eczema or generalized eczema, and hypo/hyperpigmentation [69]. Treatment is not recommended in pregnant women and patients with a history of atopic eczema [69].

5.2.3 Topical minoxidil

Although a meta-analysis confirmed the efficacy of topical minoxidil 5% in children and adults with patchy AA, topical minoxidil may be insufficient as monotherapy for extensive AA [73]. Controversy exists as to whether the combination of minoxidil with topical Cs is superior to monotherapy with topical Cs [74]. One milliliter of topical minoxidil solution should be applied once or twice daily, with the 5% solution being more effective than the 2% solution [70, 74]. Patients should be aware that therapy should be continued for at least 3 to 4 months to see any effect. Reversible hypertrichosis and allergic contact dermatitis are possible side effects [69].

5.2.4 Ultraviolet light therapy

An immunomodulatory effect is proposed in the mechanism of action of ultraviolet light-based therapies, which could be useful in AA [75, 76].

5.2.4.1 Ultraviolet B (UVB) laser excimer

The excimer laser emits monochromatic ultraviolet B (UVB) light at a wavelength of 308 nm. Its mechanism of action in alopecia areata is believed to involve T-cell apoptosis and the generation of mediators, such as IL-4, IL-10, prostaglandin E2, platelet-activating factor, histamine, and cis-urocanic acid with immunomodulatory effect [75, 76]. In some small studies and case reports, excimer laser treatment was associated with improvement in patchy alopecia areata of the scalp [75, 77]. Patients with limb lesions, alopecia totalis (AT), or alopecia universalis (AU) have not responded to treatment [75].

5.2.4.2 Psoralen plus ultraviolet a (PUVA) therapy

PUVA photochemotherapy involves topical or oral administration of a psoralen, a photosensitizing agent, followed by exposure to ultraviolet A (UVA) light [76]. A meta-analysis of 36 studies evaluating the efficacy of physical therapies in alopecia found that ultraviolet light in the AA group was superior to control, although with a high relapse rate [76]. In general, the efficacy of PUVA as monotherapy in AA is known, but the response is variable and poorly maintained over time [70]. It is not completely clear at what accumulative dose they appear, but the adverse effects reported in PUVA are skin photoaging, actinic keratosis, and non-melanoma skin cancer [76].

5.2.5 Platelet-rich plasma

Platelet-rich plasma (PRP) is an autologous plasma preparation with concentrated platelets containing various growth factors and cytokines useful for cell proliferation and differentiation and with anti-inflammatory properties [78].

In a randomized, double-blind, placebo-controlled trial, 45 participants with AA of at least 2 years duration were randomly assigned to intralesional injections of PRP, intralesional triamcinolone acetonide or placebo, and PRP was superior to triamcinolone acetonide in inducing hair growth and revealed significantly better dermoscopic results than intralesional triamcinolone [79]. In a randomized controlled study, a total of 90 patients with different types of AA were randomly assigned to three groups: the first group was treated with topical minoxidil 5% twice daily. The second was treated with three sessions of PRP treatment every 4 weeks. The third group received placebo. Significant hair growth was obtained in patchy AA (70%) and AU (30%) after three PRP sessions; however, AT did not respond to PRP [80].

Although PRP is relatively safe and potentially effective, further large-scale studies are needed to evaluate the efficacy of PRP as monotherapy or in association with other therapeutic modalities for AA [78].

5.2.6 Topical anthralin

Anthralin is a topical irritant agent, applied as a 0.5–1% cream daily on the affected areas for 20–30 minutes, with progressive increases in exposure time until reaching a mild dermatitis. The available evidence of its use is limited; efficacy has been demonstrated in children undergoing other topical treatment (Cs, minoxidil), although the irritation produced may compromise the adherence [81]. A systematic review found that topical anthralin monotherapy achieved a complete response rate of less than 50% (30–35%) in pediatric patients with AA [82]. The use of anthralin could achieve longer-lasting effects than laser therapy or topical immunotherapy, but less efficacy [82].

5.3 Systemic treatment options

5.3.1 Systemic corticosteroids

Systemic corticosteroids can be effective in extensive and rapidly progressive AA, often as a temporary measure or as bridge therapy to other therapies, considering that recurrence after discontinuation of therapy and systemic adverse effects in chronic therapy are common [69].

Daily oral therapy with an initial prednisolone dose of 1–0.5 mg/kg and a gradual reduction over 6 to 12 weeks is often used [70]. There is growing interest in the efficacy of intravenous or oral corticosteroid pulses [69, 70], since the toxicity and recurrence rate may be lower than with daily systemic corticosteroids. A systematic review on pulsed corticosteroid therapy included 41 articles, most of them using intravenous corticosteroid pulses, generally a treatment of 1 to 3 days per month. Very few cases of complete response were found, but in responders the risk of relapse was low (17%). Therefore, therapy may be useful in patients with good prognostic factors: multifocal AA, first episode of AA, and new-onset AA (less than 2 years) [83].

An observational study with a prospective cohort of 40 patients evaluated the efficacy and safety of treatment with dexamethasone minipulses in patients with AA, who did not improve with topical therapies. A significant and progressive overall decrease in SALT score was observed during treatment: at 9 months, a SALT-50 response was achieved in 51.8% of patients. Hypothyroidism and early age of onset were identified as factors for lack of response to treatment [84].

A high recurrence rate, following dose reduction or discontinuation, as well as adverse effects (e.g., pituitary–adrenal axis suppression, weight gain, ocular and skeletal changes, and aggravation of hypertension or diabetes) during long-term therapy have restricted the application of systemic corticosteroids as chronic AA therapy [70].

5.3.2 Oral minoxidil

A systemic review including 10 articles (19,218 patients) showed that oral administration of low-dose minoxidil (0.25 to 5 mg) twice daily improved 18 to 82.4% of patients (including severe and refractory AA) [85]. The dose of oral minoxidil ranged from 0.25 to 5 mg daily and twice daily. The most frequent adverse effects were generally mild and well tolerated (facial hypertrichosis and postural hypotension), which, together with the convenience of oral administration, may improve adherence to treatment with respect to topical minoxidil [85].

5.3.3 Classic immunosuppressants

Immunosuppressants used for refractory AA include methotrexate, azathioprine, cyclosporine, and sulfasalazine. The use of these drugs requires monitoring of their toxicity by periodic blood analysis, and there is limited evidence of their efficacy [69, 70].

5.3.3.1 Methotrexate (MTX)

A meta-analysis of 16 observational studies evaluated the efficacy of MTX in severe AA in monotherapy or combined with other therapies, as well as its safety and relapse rate [86]. Patients were generally treated with doses between 7.5 and 25 mg per week. MTX induced hair regrowth of more than 50% in 63.2% of patients with AA. Adults appeared to respond better to methotrexate treatment. MTX taken together with corticosteroids was found to be more effective than in monotherapy. Initial hair regrowth with MTX may be evident after approximately 3 months, and 6 to 12 months of therapy may be required for full regrowth. However, recurrence appears common with gradual tapering of MTX. MTX complication rates were acceptable and similar between adult and pediatric cases [87].

5.3.3.2 Azathioprine (AZA)

Oral AZA may be a therapeutic option for adult patients with severe recalcitrant AA. However, given the frequency of adverse effects, close follow-up with analytical controls is recommended [70]. In a prospective study of 14 adult patients with AU refractory to other treatments, hair regrowth of $\geq 75\%$ was achieved in six patients with AZA doses of 2.5 mg/kg/day adjusted for thiopurine methyltransferase levels [88]. Responses occurred 4 to 6 months after treatment initiation, and four of the six responders had a maintained response after discontinuing AZA. Adverse effects (diarrhea, hepatitis, pancreatitis, or myelosuppression) occurred in 35.71% of participants [88].

5.3.3.3 Cyclosporine

Cyclosporine may be a therapeutic option at doses up to 6 mg/kg/day for the treatment of AA totalis, AA universalis, or multifocal AA (sterkens). However, cyclosporine therapy is associated with the potential for serious adverse effects, including hypertension and nephrotoxicity, that make its use unsuitable as maintenance therapy [69, 70, 74]. A randomized, double-blind, placebo-controlled trial of 32 patients with moderate to severe AA evaluated the efficacy of cyclosporine at a dose of 4 mg/kg per day for 3 months. The treatment group achieved a $\geq 50\%$ reduction in SALT score compared to the placebo group, but the difference between the two groups was not statistically significant [89]. In a retrospective study of 25 patients with severe AA treated with cyclosporine at 2.5–6 mg/kg/day for 2–12 months, 10 achieved significant hair growth [90]. A better response was obtained in patients with AA of less than 4 years duration, so the duration of the disease could influence the efficacy of cyclosporine [90].

5.3.3.4 Sulfasalazine

It is a prodrug activated by bacteria in the colon to sulfapyridine and 5-aminosalicylic acid with immunosuppressive and immunoregulatory properties [69]. In an open-label, uncontrolled clinical trial, 26 patients with recalcitrant or severe AA on treatment with 3 g/day sulfasalazine for 6 months were followed for 3 years. Six patients showed complete regrowth, nine patients showed partial regrowth, and ten patients experienced complete or partial relapse [91]. In a prospective study of 39 patients with refractory AA, the response to 3 g/day sulfasalazine for 6 months was evaluated. Ten patients experienced 60–100% regrowth, and 17 patients experienced no response [92]. Side effects of sulfasalazine may include gastrointestinal distress, headache, fever, rash and, less commonly, hematologic disorders and hepatotoxicity [91–93]. Starting therapy at a low dose may decrease gastrointestinal symptoms [91–93]. Blood count and liver function should be monitored closely during the first 3 months of therapy and every 3 to 6 months thereafter [93].

5.3.4 Biological drugs and new molecules under investigation

5.3.4.1 Apremilast

It is a phosphodiesterase 4 (PDE4) inhibitor that reduces the production of pro-inflammatory cytokines [69, 94]. PDE4 is found to be upregulated in human scalp

lesions of patients with AA [69, 94]. In a double-blind, placebo-controlled study in 30 patients with moderate to severe AA, the efficacy of oral apremilast administered for 24 weeks was evaluated [94]. At 24 weeks, only 1 of 12 apremilast-treated subjects achieved SALT50, and similarly 1 of 8 placebo-treated subjects achieved SALT50. The difference between the mean percentage improvement in SALT score compared to baseline for the two study groups was not statistically significant [94]. Despite having demonstrated efficacy in animal models, results in humans are conflicting, with lack of efficacy of apremilast in some recent studies of severe AA, but also some case reports of positive effects [69, 74, 94].

5.3.4.2 Dupilumab

It is a human monoclonal antibody that acts as a dual inhibitor of IL-4 and IL-13, used in the treatment of atopic dermatitis [65, 95]. There have been case reports of patients with atopic dermatitis and AA on dupilumab treatment who have experienced improvement of AA [65, 95]. It is proposed that the efficacy observed in these cases is due to the pathophysiological characteristics shared between atopic dermatitis and AA, with an involvement of the Th2 immune pathway in the pathogenesis of AA [65, 95]. On the other hand, dupilumab has also been associated with AA in patients with preexisting AA and those without prior episodes of AA [96]. Theories for this adverse effect include the amplification of the Th1 pathway as a result of dupilumab-induced downregulation of Th2, which calls into question the involvement of the Th2 pathway in AA [95].

A Phase II, randomized, double-blind, placebo-controlled, pilot study (NCT03359356) investigating dupilumab (300 mg) treatment in AA patients without atopic dermatitis is currently underway [97]. The dupilumab-treated arm included 40 patients. At week 48, the dupilumab-treated group experienced improvement of SALT30/SALT50/SALT75 in 32.5, 22.5, and 15% of patients, respectively [97]. Moreover, patients with baseline IgE levels ≥ 200 IU/mL had even higher response rates, making baseline IgE postulated as a predictor of response to dupilumab in patients with AA [97].

The most common adverse events reported are injection site reactions, conjunctivitis, blepharitis, ocular pruritus, xerophthalmia, and symptomatic reactivations of herpes simplex virus [95].

5.3.4.3 Ustekinumab

It is a monoclonal antibody that blocks the p40 subunit of IL-12/IL-23 used for treating psoriasis and Crohn's disease [95]. Ustekinumab caused hair regeneration in three patients with moderate to severe AA [98]. Common adverse effects include injection site reactions, headache, and fatigue [95].

5.3.4.4 Abatacept

It is a selective modulator of T-cell co-stimulation, composed of cytotoxic T-lymphocyte-associated antigen 4 (CTLA-4) with an immunoglobulin (Ig)G1 moiety. It is currently approved for the treatment of rheumatoid arthritis and juvenile idiopathic arthritis [95]. An open-label, single-arm phase II clinical trial (NCT02018042) evaluated the efficacy of abatacept (125 mg daily subcutaneously for 24 weeks) in 15 patients with moderate-to-severe patchy-type AA, AA totalis, and AA

universalis [99]. Although most patients had a low or moderate response with abatacept, one patient achieved complete scalp hair growth at week 36. Three subjects did not respond to treatment [99]. Common adverse effects reported include headache, dizziness, nasopharyngitis, cough, back pain, and hypertension [95].

5.3.5 Janus kinase inhibitors (JAKi)

The JAK–STAT pathway is a signal transduction and intracellular transcription regulation pathway in which numerous pro-inflammatory pathways converge [65] (**Figure 6**). The pathway involves the JAK family of four kinases (JAK1, JAK2, JAK3, and tyrosine kinase 2 [TYK2]), which are located in the intracellular domains of type I and II cytokine receptors [65, 95]. Their activation when ligand binds to the receptor leads to binding and phosphorylation of the STAT family of proteins, which bind DNA and mediate processes of cell proliferation, differentiation, migration, and apoptosis [65]. Recently, the involvement of several JAK–STAT pathway-dependent cytokines in the pathogenesis of AA (IL-2, IL-7, IL-15, IL-21, and interferon-gamma) has been described [65]. Key genes in the JAK–STAT pathway related to hair growth include STAT5A/B, STAT3, JAK1, JAK3, and Socs2/3, highly expressed in the catagen and telogen phases but suppressed in the early anagen phase [95]. In AA, inhibition of JAK–STAT interferes with the positive feedback loop between follicular cell and cytotoxic CD8+ NKG2D+ CD8+ T cells in AA [95]. Given the involvement of this pathway and its dependent cytokines in the pathogenesis of AA, JAK–STAT has become a potential therapeutic target [65, 69, 70, 95].

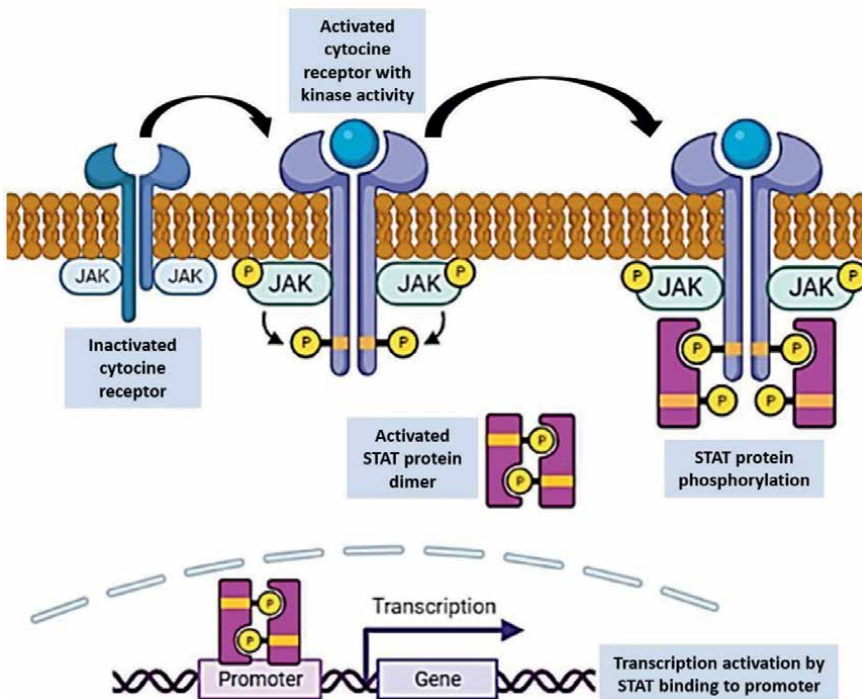


Figure 6. JAK–STAT pathway. This image was created using Biorender.com.

JAKi are oral drugs that have demonstrated effectiveness and safety for the treatment of diseases such as rheumatoid arthritis and psoriatic arthritis [95, 100]. JAKi are selective, but not specific for a single JAK and, therefore, can affect several immune pathways [95]. The FDA has issued warnings for oral JAKi due to concerns about an increased risk of serious infections, mortality, malignancy, major adverse cardiovascular events, and thrombosis [69, 70, 95].

5.3.5.1 Baricitinib

It is a selective and reversible JAK1 and JAK2 inhibitor, it has also been shown to indirectly inhibit IL-6, and IL-23 activity, and to a lesser extent inhibit JAK3 [95]. Baricitinib has demonstrated efficacy for severe alopecia areata [95, 100, 101]. In 2022, the FDA approved baricitinib for the treatment of adults with severe alopecia areata [65, 95]. In two randomized, placebo-controlled, phase 3 trials BRAVE-AA1 (n = 654) and BRAVE-AA2 (n = 546), adults with severe alopecia areata (SALT ≥ 50) were randomized to baricitinib 4 mg per day, baricitinib 2 mg per day, or placebo [101]. At week 36, the proportion of patients in the baricitinib 4 mg, baricitinib 2 mg, and placebo groups who achieved a SALT score of ≤ 20 in BRAVE-AA1 was 39, 23, and 6%. In BRAVE-AA2, 36, 19, and 3% of patients in the 4 mg, 2 mg, and placebo groups achieved this end point, respectively [101]. The dose of baricitinib is 2 mg once daily with an increase to 4 mg once daily if response is inadequate. Patients with near complete or total scalp hair loss may be treated initially with 4 mg once daily. The dose is reduced to 2 mg once daily upon adequate response [65, 95, 101]. The most common adverse effects encountered with baricitinib are acne, urinary tract infections, and elevated serum creatinine kinase and low-density lipoprotein (LDL) and high-density lipoprotein (HDL) [101].

5.3.5.2 Tofacitinib

It selectively inhibits JAK1 and JAK3 and blocks STAT phosphorylation induced by IFN- γ , IL-2, IL4, IL-7, IL-15, and IL-21 [65, 69, 95]. Treatment with oral tofacitinib has been shown to achieve hair regeneration in patients with AA in case series and retrospective studies, and patients are typically treated with 5 mg twice daily [65, 69]. In a retrospective study of 90 adult patients with severe AA (SALT > 40), including AA totalis or AA universalis, the efficacy of oral tofacitinib at doses of 5–10 mg/day for at least 4 months was demonstrated (77% clinical response in AA of less than 10 years duration). Duration longer than 10 years and having AA totalis or AA universalis were defined as predictors of low response to tofacitinib. The relapse rate 3 months after discontinuation of oral tofacitinib treatment is high [102]. Treatment with oral tofacitinib increases the risk of infections [102]. Cases of serious infections and malignancies have been reported in patients receiving tofacitinib treatment [69].

5.3.5.3 Ruxolitinib

It selectively inhibits JAK1 and JAK2 and, to some extent, TYK2 [95]. The utility of oral ruxolitinib in the management of AA has been reported in case reports, case series, and an open-label trial [65, 69, 95, 103]. In an open-label clinical trial of 12 patients with moderate to severe AA, the efficacy of oral ruxolitinib, 20 mg twice daily, was evaluated during 3–6 months of treatment, and 9 patients (75%) achieved at least 50% hair growth at the end of treatment [103].

5.3.5.4 Other oral Janus kinase inhibitors under investigation

It is a phase 2a randomized, placebo-controlled study to evaluate the efficacy and safety of the oral JAKi drugs ritlecitinib and brepocitinib in patients with severe AA (SALT >50%). The trial includes 47 patients in each study group [104]. Results at week 24 suggest efficacy of ritlecitinib and brepocitinib in AA, although two patients experienced a serious adverse event (rhabdomyolysis) in the brepocitinib group [104].

5.3.5.5 Topical Janus kinase inhibitors

The utility of topical JAKi is currently under investigation in patients with AA to minimize the risk of systemic side effects, especially for maintenance treatment [70]. Topical ruxolitinib and baricitinib creams in 1 and 2% formulations have been reported to produce hair regrowth in patients with AA [65, 105]. Topical tofacitinib has also achieved hair growth and prolongation of the anagen phase [65]. However, there are also case reports and clinical trials reporting inconsistent or no induction of hair growth with topical ruxolitinib or tofacitinib cream.

5.3.6 Proposed management strategy for alopecia areata

According to the literature reviewed, we propose this scheme depending on the age and extent of AA. Response to treatment should be re-evaluated every 3–6 months of initiation of new therapy.

Conflict of interest

The authors declare no conflict of interest.

Author details

Alberto Soto-Moreno¹, Clara Ureña-Paniego¹, Trinidad Montero-Vilchez^{1,2*}
and Salvador Arias-Santiago^{1,2,3}


1 Dermatology Department, Virgen de las Nieves University Hospital, Granada, Spain

2 Instituto de Investigación Biosanitaria ibs.GRANADA, Granada, Spain

3 Faculty of Medicine, Dermatology Department, University of Granada, Granada, Spain

*Address all correspondence to: tmonterov@gmail.com

IntechOpen

© 2023 The Author(s). Licensee IntechOpen. This chapter is distributed under the terms of the Creative Commons Attribution License (<http://creativecommons.org/licenses/by/3.0>), which permits unrestricted use, distribution, and reproduction in any medium, provided the original work is properly cited. 

References

- [1] Lee HH, Gwillim E, Patel KR, Hua T, Rastogi S, Ibler E, et al. Epidemiology of alopecia areata, ophiasis, totalis, and universalis: A systematic review and meta-analysis. *Journal of the American Academy of Dermatology*. 2020;**82**:675-682. DOI: 10.1016/j.jaad.2019.08.032
- [2] Mirzoyev SA, Schrum AG, Davis MDP, Torgerson RR. Lifetime incidence risk of alopecia Areata estimated at 2.1 percent by Rochester epidemiology project, 1990–2009. *The Journal of Investigative Dermatology*. 2014;**134**:1141-1142. DOI: 10.1038/jid.2013.464
- [3] Gilhar A. Collapse of immune privilege in alopecia areata: coincidental or substantial? *The Journal of Investigative Dermatology*. 2010;**130**:2535-2537. DOI: 10.1038/jid.2010.260
- [4] You HR, Kim S-J. Factors associated with severity of alopecia Areata. *Annals of Dermatology*. 2017;**29**:565-570. DOI: 10.5021/ad.2017.29.5.565
- [5] Xiao F-L, Yang S, Liu J-B, He P-P, Yang J, Cui Y, et al. The epidemiology of childhood alopecia areata in China: A study of 226 patients. *Pediatric Dermatology*. 2006;**23**:13-18. DOI: 10.1111/j.1525-1470.2006.00161.x
- [6] Harries M, Macbeth AE, Holmes S, Chiu WS, Gallardo WR, Nijher M, et al. The epidemiology of alopecia areata: A population-based cohort study in UK primary care*. *British Journal of Dermatology*. 2022;**186**:257-265. DOI: 10.1111/bjd.20628
- [7] Messenger AG, Slater DN, Bleehen SS. Alopecia areata: Alterations in the hair growth cycle and correlation with the follicular pathology. *British Journal of Dermatology*. 1986;**114**:337-347. DOI: 10.1111/j.1365-2133.1986.tb02825.x
- [8] Whiting DA. Histopathologic features of alopecia Areata: A new look. *Archives of Dermatology*. 2003;**139**:1555-1559. DOI: 10.1001/archderm.139.12.1555
- [9] Chen C-L, Huang W-Y, Wang EHC, Tai K-Y, Lin S-J. Functional complexity of hair follicle stem cell niche and therapeutic targeting of niche dysfunction for hair regeneration. *Journal of Biomedical Science*. 2020;**27**:43. DOI: 10.1186/s12929-020-0624-8
- [10] Peters EMJ, Liotiri S, Bodó E, Hagen E, Bíró T, Arck PC, et al. Probing the effects of stress mediators on the human hair follicle: Substance P holds central position. *The American Journal of Pathology*. 2007;**171**:1872-1886. DOI: 10.2353/ajpath.2007.061206
- [11] Rajabi F, Drake LA, Senna MM, Rezaei N. Alopecia areata: A review of disease pathogenesis. *British Journal of Dermatology*. 2018;**179**:1033-1048. DOI: 10.1111/bjd.16808
- [12] Fukuyama M, Ito T, Ohyama M. Alopecia areata: Current understanding of the pathophysiology and update on therapeutic approaches, featuring the Japanese dermatological association guidelines. *The Journal of Dermatology*. 2022;**49**:19-36. DOI: 10.1111/1346-8138.16207
- [13] Ito T, Ito N, Bettermann A, Tokura Y, Takigawa M, Paus R. Collapse and restoration of MHC class-I-dependent immune privilege: Exploiting the human hair follicle as a model. *The American Journal of Pathology*. 2004;**164**:623-634. DOI: 10.1016/S0002-9440(10)63151-3

- [14] Rodriguez TA, Duvic M, Registry NAA. Onset of alopecia areata after Epstein-Barr virus infectious mononucleosis. *Journal of the American Academy of Dermatology*. 2008;**59**:137-139. DOI: 10.1016/j.jaad.2008.02.005
- [15] Ito T, Ito N, Saatoff M, Hashizume H, Fukamizu H, Nickoloff BJ, et al. Maintenance of hair follicle immune privilege is linked to prevention of NK cell attack. *Journal of Investigative Dermatology*. 2008;**128**:1196-1206. DOI: 10.1038/sj.jid.5701183
- [16] Rossi A, Magri F, Michellini S, Sernicola A, Muscianese M, Caro G, et al. New onset of alopecia areata in a patient with SARS-CoV-2 infection: Possible pathogenetic correlations? *Journal of Cosmetic Dermatology*. 2021;**20**:2004-2005. DOI: 10.1111/jocd.14080
- [17] Chu C-H, Cheng Y-P, Chan J-YL. Alopecia Areata after vaccination: Recurrence with Rechallenge. *Pediatric Dermatology*. 2016;**33**:e218-e219. DOI: 10.1111/pde.12849
- [18] Ho JD, McNish A, McDonald L, Burrell C, Smith-Matthews S. Alopecia universalis with unusual histopathologic features after vaccination with ChAdOx1 nCoV-19 (AZD1222). *JAAD Case Rep*. 2022;**25**:4-8. DOI: 10.1016/j.jdcr.2022.05.002
- [19] Paus R, Bulfone-Paus S, Bertolini M. Hair follicle immune privilege revisited: The key to alopecia Areata management. *Journal of Investigative Dermatology Symposium Proceedings*. 2018;**19**:S12-S17. DOI: 10.1016/j.jisps.2017.10.014
- [20] Kinori M, Bertolini M, Funk W, Samuelov L, Meyer KC, Emelianov VU, et al. Calcitonin gene-related peptide (CGRP) may award relative protection from interferon- γ -induced collapse of human hair follicle immune privilege. *Experimental Dermatology*. 2012;**21**:223-226. DOI: 10.1111/j.1600-0625.2011.01432.x
- [21] Breitkopf T, Lo BKK, Leung G, Wang E, Yu M, Carr N, et al. Somatostatin expression in human hair follicles and its potential role in immune privilege. *The Journal of Investigative Dermatology*. 2013;**133**:1722-1730. DOI: 10.1038/jid.2013.53
- [22] Slominski A, Wortsman J, Tuckey RC, Paus R. Differential expression of HPA axis homolog in the skin. *Molecular and Cellular Endocrinology*. 2007;**265-266**:143-149. DOI: 10.1016/j.mce.2006.12.012
- [23] Kang H, Wu W-Y, Lo BKK, Yu M, Leung G, Shapiro J, et al. Hair follicles from alopecia areata patients exhibit alterations in immune privilege-associated gene expression in advance of hair loss. *The Journal of Investigative Dermatology*. 2010;**130**:2677-2680. DOI: 10.1038/jid.2010.180
- [24] Ljunggren HG, Kärre K. In search of the “missing self”: MHC molecules and NK cell recognition. *Immunology Today*. 1990;**11**:237-244. DOI: 10.1016/0167-5699(90)90097-s
- [25] Niederkorn JY. See no evil, hear no evil, do no evil: The lessons of immune privilege. *Nature Immunology*. 2006;**7**:354-359. DOI: 10.1038/ni1328
- [26] Xing L, Dai Z, Jabbari A, Cerise JE, Higgins CA, Gong W, et al. Alopecia areata is driven by cytotoxic T lymphocytes and is reversed by JAK inhibition. *Nature Medicine*. 2014;**20**:1043-1049. DOI: 10.1038/nm.3645
- [27] Roberts AI, Lee L, Schwarz E, Groh V, Spies T, Ebert EC, et al. NKG2D receptors induced by IL-15 costimulate

CD28-negative effector CTL in the tissue microenvironment. *Journal of Immunology*. 2001;**167**:5527-5530. DOI: 10.4049/jimmunol.167.10.5527

[28] Strazzulla LC, Wang EHC, Avila L, Sicco KL, Brinster N, Christiano AM, et al. Alopecia areata: Disease characteristics, clinical evaluation, and new perspectives on pathogenesis. *Journal of the American Academy of Dermatology*. 2018;**78**:1-12. DOI: 10.1016/j.jaad.2017.04.1141

[29] Petukhova L. An imperative need for further genetic studies of alopecia Areata. *The Journal of Investigative Dermatology. Symposium Proceedings*. 2020;**20**:S22-S27. DOI: 10.1016/j.jisp.2020.04.003

[30] Blaumeiser B, Goot I van der, Fimmers R, Hanneken S, Ritzmann S, Seymons K, et al. Familial aggregation of alopecia areata. *Journal of the American Academy of Dermatology* 2006;**54**:627-632. doi:10.1016/j.jaad.2005.12.007.

[31] Petukhova L, Duvic M, Hordinsky M, Norris D, Price V, Shimomura Y, et al. Genome-wide association study in alopecia areata implicates both innate and adaptive immunity. *Nature*. 2010;**466**:113-117. DOI: 10.1038/nature09114

[32] Betz RC, Petukhova L, Ripke S, Huang H, Menelaou A, Redler S, et al. Genome-wide meta-analysis in alopecia areata resolves HLA associations and reveals two new susceptibility loci. *Nature Communications*. 2015;**6**:5966. DOI: 10.1038/ncomms6966

[33] Jagielska D, Redler S, Brockschmidt FF, Herold C, Pasternack SM, Garcia Bartels N, et al. Follow-up study of the first genome-wide association scan in alopecia areata: IL13 and KIAA0350 as susceptibility

loci supported with genome-wide significance. *The Journal of Investigative Dermatology*. 2012;**132**:2192-2197. DOI: 10.1038/jid.2012.129

[34] Oka A, Takagi A, Komiyama E, Yoshihara N, Mano S, Hosomichi K, et al. Alopecia areata susceptibility variant in MHC region impacts expressions of genes contributing to hair keratinization and is involved in hair loss. *eBioMedicine*. 2020;**57**:102810. DOI: 10.1016/j.ebiom.2020.102810

[35] Alkhalifah A, Alsantali A, Wang E, McElwee KJ, Shapiro J. Alopecia areata update: Part I. clinical picture, histopathology, and pathogenesis. *Journal of the American Academy of Dermatology*. 2010;**62**:177-188, quiz 189-90. DOI: 10.1016/j.jaad.2009.10.032

[36] Shapiro J, Madani S. Alopecia areata: diagnosis and management. *International Journal of Dermatology*. 1999;**38**(Suppl. 1):19-24. DOI: 10.1046/j.1365-4362.1999.00004.x

[37] MacDonald Hull SP, Wood ML, Hutchinson PE, Sladden M, Messenger AG. British Association of Dermatologists. Guidelines for the management of alopecia areata. *The British Journal of Dermatology*. 2003;**149**:692-699. DOI: 10.1046/j.1365-2133.2003.05535.x

[38] Cranwell WC, Lai VW, Photiou L, Meah N, Wall D, Rathnayake D, et al. Treatment of alopecia areata: An Australian expert consensus statement. *The Australasian Journal of Dermatology*. 2019;**60**:163-170. DOI: 10.1111/ajd.12941

[39] Alessandrini A, Starace M, Bruni F, Brandi N, Baraldi C, Misciali C, et al. Alopecia Areata incognita and diffuse alopecia Areata: Clinical, Trichoscopic, histopathological, and therapeutic

- features of a 5-year study. *Dermatol Pract Concept*. 2019;**9**:272-277. DOI: 10.5826/dpc.0904a05
- [40] Tosti A, Whiting D, Iorizzo M, Pazzaglia M, Misciali C, Vincenzi C, et al. The role of scalp dermoscopy in the diagnosis of alopecia areata incognita. *Journal of the American Academy of Dermatology*. 2008;**59**:64-67. DOI: 10.1016/j.jaad.2008.03.031
- [41] Chartier MB, Hoss DM, Grant-Kels JM. Approach to the adult female patient with diffuse nonscarring alopecia. *Journal of the American Academy of Dermatology*. 2002;**47**:809-818; quiz 818-20. DOI: 10.1067/mjd.2002.128771
- [42] Madani S, Shapiro J. Alopecia areata update. *Journal of the American Academy of Dermatology*. 2000;**42**:549-566. DOI: 10.1067/mjd.2000.103909
- [43] Wałkiel A, Rakowska A, Sikora M, Olszewska M, Rudnicka L. Trichoscopy of alopecia areata: An update. *The Journal of Dermatology*. 2018;**45**:692-700. DOI: 10.1111/1346-8138.14283
- [44] Gómez-Quispe H, Muñoz Moreno-Arrones O, Hermosa-Gelbard Á, Vañó-Galván S, Saceda-Corralo D. Trichoscopy in alopecia Areata. *Actas Dermo-Sifiligráficas*. 2023;**114**:25-32. DOI: 10.1016/j.ad.2022.08.018
- [45] Wałkiel A, Rakowska A, Sikora M, Olszewska M, Rudnicka L. Trichoscopy of alopecia areata: An update. *The Journal of Dermatology*. 2018;**45**:692-700. DOI: 10.1111/1346-8138.14283
- [46] Kibar M, Aktan Ş, Lebe B, Bilgin M. Trichoscopic findings in alopecia areata and their relation to disease activity, severity and clinical subtype in Turkish patients. *Australasian Journal of Dermatology*. 2015;**56**:e1-e6. DOI: 10.1111/ajd.12102
- [47] Inui S, Nakajima T, Nakagawa K, Itami S. Clinical significance of dermoscopy in alopecia areata: Analysis of 300 cases. *International Journal of Dermatology*. 2008;**47**:688-693. DOI: 10.1111/j.1365-4632.2008.03692.x
- [48] Lobato-Berezo A, Olmos-Alpiste F, PujolRM, Saceda-CorraloD. Constricciones de Pohl-Pinkus en tricoscopia. ¿Qué indican? *Actas Dermo-Sifiligráficas*. 2019;**110**:315-316. DOI: 10.1016/j.ad.2018.02.030
- [49] Tkachenko E, Huang KP, Ko JM, Liu KJ, Scott DA, Senna MM, et al. Brigham eyebrow tool for alopecia: A reliable assessment of eyebrow alopecia Areata. *The Journal of Investigative Dermatology. Symposium Proceedings*. 2020;**20**:S41-S44. DOI: 10.1016/j.jisp.2020.06.001
- [50] Manjaly P, Li SJ, Tkachenko E, Ko JM, Liu KJ, Scott DA, et al. Development and validation of the Brigham eyelash tool for alopecia (BELA): A measure of eyelash alopecia areata. *Journal of the American Academy of Dermatology*. 2021;**85**:271-272. DOI: 10.1016/j.jaad.2020.06.1034
- [51] Waard-van D, der Spek FB, Oranje AP, De Raeymaecker DM, Peereboom-Wynia JD. Juvenile versus maturity-onset alopecia areata—A comparative retrospective clinical study. *Clinical and Experimental Dermatology*. 1989;**14**:429-433. DOI: 10.1111/j.1365-2230.1989.tb02604.x
- [52] Mohan GC, Silverberg JI. Association of Vitiligo and Alopecia Areata with Atopic Dermatitis: A systematic review and meta-analysis. *JAMA Dermatology*. 2015;**151**:522-528. DOI: 10.1001/jamadermatol.2014.3324
- [53] Goh C, Finkel M, Christos PJ, Sinha AA. Profile of 513 patients with alopecia areata: Associations of disease

- subtypes with atopy, autoimmune disease and positive family history. *Journal of the European Academy of Dermatology and Venereology*. 2006;**20**:1055-1060. DOI: 10.1111/j.1468-3083.2006.01676.x
- [54] Hernández-Bel P, Unamuno B, Sánchez-Carazo JL, Febrer I, Alegre V. Syphilitic alopecia: A report of 5 cases and a review of the literature. *Actas Dermo-Sifiligráficas (English Edition)*. 2013;**104**:512-517. DOI: 10.1016/j.adengl.2012.02.010
- [55] Friedli A, Chavaz P, Harms M. Alopecia syphilitica: Report of two cases in Geneva. *Dermatology*. 2001;**202**:376-377. DOI: 10.1159/000051688
- [56] Dy LC, Whiting DA. Histopathology of alopecia areata, acute and chronic: Why is it important to the clinician? *Dermatologic Therapy*. 2011;**24**:369-374. DOI: 10.1111/j.1529-8019.2011.01414.x
- [57] Mikiel D, Polańska A, Żaba R, Adamski Z, Dańczak-Pazdrowska A. Usefulness of high-frequency ultrasonography in the assessment of alopecia areata - comparison of ultrasound images with trichoscopic images. *Postepy Dermatol Alergol*. 2022;**39**:132-140. DOI: 10.5114/ada.2020.102641
- [58] Mikiel D, Polańska A, Żaba R, Adamski Z, Dańczak-Pazdrowska A. High-frequency ultrasonography of the scalp - comparison of ultrasound and trichoscopic images in healthy individuals. *Skin Research and Technology*. 2021;**27**:201-207. DOI: 10.1111/srt.12930
- [59] Barahmani N, Schabath MB, Duvic M, National Alopecia Areata Registry. History of atopy or autoimmunity increases risk of alopecia areata. *Journal of the American Academy of Dermatology*. 2009;**61**:581-591. DOI: 10.1016/j.jaad.2009.04.031
- [60] Ali NS, Tollefson MM, Lohse CM, Torgerson RR. Incidence and comorbidities of pediatric alopecia areata: A retrospective matched cohort study using the Rochester epidemiology project. *Journal of the American Academy of Dermatology*. 2022;**87**:427-429. DOI: 10.1016/j.jaad.2021.08.050
- [61] Daneshpazhooch M, Nazemi TM-J, Bigdeloo L, Yoosefi M. Mucocutaneous findings in 100 children with down syndrome. *Pediatric Dermatology*. 2007;**24**:317-320. DOI: 10.1111/j.1525-1470.2007.00412.x
- [62] Collins SM, Dominguez M, Ilmarinen T, Costigan C, Irvine AD. Dermatological manifestations of autoimmune polyendocrinopathy-candidiasis-ectodermal dystrophy syndrome. *The British Journal of Dermatology*. 2006;**154**:1088-1093. DOI: 10.1111/j.1365-2133.2006.07166.x
- [63] Ruiz-Doblado S, Carrizosa A, García-Hernández MJ. Alopecia areata: Psychiatric comorbidity and adjustment to illness. *International Journal of Dermatology*. 2003;**42**:434-437. DOI: 10.1046/j.1365-4362.2003.01340.x
- [64] Ghanizadeh A. Comorbidity of psychiatric disorders in children and adolescents with alopecia areata in a child and adolescent psychiatry clinical sample. *International Journal of Dermatology*. 2008;**47**:1118-1120. DOI: 10.1111/j.1365-4632.2008.03743.x
- [65] Zheng C, Tosti A. Alopecia Areata: New treatment options including Janus kinase inhibitors. *Dermatologic Clinics*. 2021;**39**:407-415. DOI: 10.1016/j.det.2021.03.005
- [66] Reyes-Hadsall S, Drake L, Han JJ, Lee KJ, Zhou G, Mostaghimi A, et al. Shared decision-making, therapeutic choice, and decisional regret in

patients with alopecia Areata. *JAMA Dermatology*. 2022;**158**:1187-1191.
DOI: 10.1001/jamadermatol.2022.3025

[67] Torales J, Castaldelli-Maia JM, Ventriglio A, Almirón-Santacruz J, Barrios I, O'Higgins M, et al. Alopecia areata: A psychodermatological perspective. *Journal of Cosmetic Dermatology*. 2022;**21**:2318-2323.
DOI: 10.1111/jocd.14416

[68] Banka N, Bunagan MJK, Dubrule Y, Shapiro J. Wigs and hairpieces: Evaluating dermatologic issues. *Dermatologic Therapy*. 2012;**25**:260-266.
DOI: 10.1111/j.1529-8019.2012.01506.x

[69] Sterkens A, Lambert J, Bervoets A. Alopecia areata: A review on diagnosis, immunological etiopathogenesis and treatment options. *Clinical and Experimental Medicine*. 2021;**21**:215-230.
DOI: 10.1007/s10238-020-00673-w

[70] Zhou C, Li X, Wang C, Zhang J. Alopecia Areata: An update on Etiopathogenesis, diagnosis, and management. *Clinical Reviews in Allergy and Immunology*. 2021;**61**:403-423.
DOI: 10.1007/s12016-021-08883-0

[71] Mahasaksiri T, Kositkuljorn C, Anuntrangsee T, Suchonwanit P. Application of topical immunotherapy in the treatment of alopecia Areata: A review and update. *Drug Design, Development and Therapy*. 2021;**15**:1285-1298. DOI: 10.2147/DDDT.S297858

[72] Jang YH, Jung HJ, Moon SY, Lee WJ, Lee S-J, Lee WK, et al. Systematic review and quality analysis of studies on the efficacy of topical diphenylcyclopropenone treatment for alopecia areata. *Journal of the American Academy of Dermatology*. 2017;**77**:170-172.e1. DOI: 10.1016/j.jaad.2017.03.015

[73] Freire PCB, Riera R, Martimbianco ALC, Petri V, Atallah AN.

Minoxidil for patchy alopecia areata: Systematic review and meta-analysis. *Journal of the European Academy of Dermatology and Venereology: JEADV*. 2019;**33**:1792-1799. DOI: 10.1111/jdv.15545

[74] Fukumoto T, Fukumoto R, Magno E, Oka M, Nishigori C, Horita N. Treatments for alopecia areata: A systematic review and network meta-analysis. *Dermatologic Therapy*. 2021;**34**:e14916.
DOI: 10.1111/dth.14916

[75] Mlacker S, Aldahan AS, Simmons BJ, Shah V, McNamara CA, Samarkandy S, et al. A review on laser and light-based therapies for alopecia areata. *Journal of Cosmetic and Laser Therapy: Official Publication of the European Society for Laser Dermatology*. 2017;**19**:93-99.
DOI: 10.1080/14764172.2016.1248440

[76] Zhang Y, Su J, Ma K, Fu X, Zhang C. Photobiomodulation therapy with different wavebands for hair loss: A systematic review and meta-analysis. *Dermatologic Surgery: Official Publication for American Society for Dermatologic Surgery*. 2022;**48**:737-740.
DOI: 10.1097/DSS.0000000000003472

[77] Arakawa Y, Nomiyama T, Katoh N. Three hundred and eight nanometer excimer light therapy for alopecia universalis that is resistant to other treatments: A clinical study of 11 patients. *The Journal of Dermatology*. 2016;**43**:1412-1416. DOI: 10.1111/1346-8138.13419

[78] Almohanna HM, Ahmed AA, Griggs JW, Tosti A. Platelet-rich plasma in the treatment of alopecia Areata: A review. *The Journal of Investigative Dermatology Symposium Proceedings*. 2020;**20**:S45-S49. DOI: 10.1016/j.jisp.2020.05.002

[79] Trink A, Sorbellini E, Bezzola P, Rodella L, Rezzani R, Ramot Y, et al.

A randomized, double-blind, placebo- and active-controlled, half-head study to evaluate the effects of platelet-rich plasma on alopecia areata. *The British Journal of Dermatology*. 2013;**169**:690-694. DOI: 10.1111/bjd.12397

[80] El Taieb MA, Ibrahim H, Nada EA, Seif Al-Din M. Platelets rich plasma versus minoxidil 5% in treatment of alopecia areata: A trichoscopic evaluation. *Dermatologic Therapy*. Jan 2017;**30**(1). DOI: 10.1111/dth.12437. Epub 2016 Oct 28. PMID: 27791311.

[81] Wu SZ, Wang S, Ratnaparkhi R, Bergfeld WF. Treatment of pediatric alopecia areata with anthralin: A retrospective study of 37 patients. *Pediatric Dermatology*. 2018;**35**:817-820. DOI: 10.1111/pde.13703

[82] Behrangi E, Roohaninasab M, Sadeghzadeh-Bazargan A, Najari Nobari N, Ghassemi M, Seirafianpour F, et al. A systematic review on the treatment of pediatric severe alopecia areata by topical immunotherapy or Anthralin (contact sensitization) or low-level light/laser therapy (LLLT): Focus on efficacy, safety, treatment duration, recurrence, and follow-up based on clinical studies. *Journal of Cosmetic Dermatology*. 2022;**21**:2727-2741. DOI: 10.1111/jocd.14480

[83] Shreberk-Hassidim R, Ramot Y, Gilula Z, Zlotogorski A. A systematic review of pulse steroid therapy for alopecia areata. *Journal of the American Academy of Dermatology*. 2016;**74**:372-375. DOI: 10.1016/j.jaad.2015.09.045

[84] Sánchez-Díaz M, Montero-Vilchez T, Bueno-Rodríguez A, Molina-Leyva A, Arias-Santiago S. Alopecia Areata and Dexamethasone Mini-Pulse Therapy, A prospective cohort: Real world evidence and factors related to successful response. *Journal of Clinical Medicine*.

18 Mar 2022;**11**(6):1694. DOI: 10.3390/jcm11061694. PMID: 35330017; PMCID: PMC8949115

[85] Sharma AN, Michelle L, Juhasz M, Muller Ramos P, Atanaskova MN. Low-dose oral minoxidil as treatment for non-scarring alopecia: A systematic review. *International Journal of Dermatology*. 2020;**59**:1013-1019. DOI: 10.1111/ijd.14933

[86] Choi CEE, Yee MYF, Tan LYL, Phan P. A qualitative study of dermatology patients and providers to understand discordant perceptions of symptom burden and disease severity. *Journal of Dermatological Treatment*. Jun 2022;**33**(4):2344-2351. DOI: 10.1080/09546634.2021.1961996. Epub 2021 Aug 9. PMID: 34314298

[87] Phan K, Ramachandran V, Sebaratnam DF. Methotrexate for alopecia areata: A systematic review and meta-analysis. *Journal of the American Academy of Dermatology*. 2019;**80**:120-127.e2. DOI: 10.1016/j.jaad.2018.06.064

[88] Vañó-Galván S, Hermosa-Gelbard Á, Sánchez-Neila N, Miguel-Gómez L, Saceda-Corralo D, Rodrigues-Barata R, et al. Treatment of recalcitrant adult alopecia areata universalis with oral azathioprine. *Journal of the American Academy of Dermatology*. 2016;**74**:1007-1008. DOI: 10.1016/j.jaad.2015.12.055

[89] Lai VWY, Chen G, Gin D, Sinclair R. Cyclosporine for moderate-to-severe alopecia areata: A double-blind, randomized, placebo-controlled clinical trial of efficacy and safety. *Journal of the American Academy of Dermatology*. 2019;**81**:694-701. DOI: 10.1016/j.jaad.2019.04.053

[90] Açıkgöz G, Çalışkan E, Tunca M, Yeniay Y, Akar A. The effect of oral cyclosporine in the treatment of severe

alopecia areata. *Cutaneous and Ocular Toxicology*. 2014;**33**:247-252. DOI: 10.3109/15569527.2013.839997

[91] Aghaei S. An uncontrolled, open label study of sulfasalazine in severe alopecia areata. *Indian Journal of Dermatology, Venereology and Leprology*. 2008;**74**:611-613. DOI: 10.4103/0378-6323.45103

[92] Rashidi T, Mahd AA. Treatment of persistent alopecia areata with sulfasalazine. *International Journal of Dermatology*. 2008;**47**:850-852. DOI: 10.1111/j.1365-4632.2008.03700.x

[93] Ellis CN, Brown MF, Voorhees JJ. Sulfasalazine for alopecia areata. *Journal of the American Academy of Dermatology*. 2002;**46**:541-544. DOI: 10.1067/mj.2002.119671

[94] Mikhaylov D, Pavel A, Yao C, Kimmel G, Nia J, Hashim P, et al. A randomized placebo-controlled single-center pilot study of the safety and efficacy of apremilast in subjects with moderate-to-severe alopecia areata. *Archives of Dermatological Research*. 2019;**311**:29-36. DOI: 10.1007/s00403-018-1876-y

[95] Pourang A, Mesinkovska NA. New and emerging therapies for alopecia areata. *Drugs*. 2020;**80**:635-646. DOI: 10.1007/s40265-020-01293-0

[96] Chung J, Slaughter CL, Simpson EL. Alopecia areata in 2 patients treated with dupilumab: New onset and worsening. *JAAD Case Reports*. 2019;**5**:643-645. DOI: 10.1016/j.jidcr.2019.03.019

[97] Guttman-Yassky E, Renert-Yuval Y, Bares J, Chima M, Hawkes JE, Gilleaudeau P, et al. Phase 2a randomized clinical trial of dupilumab (anti-IL-4R α) for alopecia areata patients. *Allergy*. 2022;**77**:897-906. DOI: 10.1111/all.15071

[98] Guttman-Yassky E, Ungar B, Noda S, Suprun M, Shroff A, Dutt R, et al. Extensive alopecia areata is reversed by IL-12/IL-23p40 cytokine antagonism. *The Journal of Allergy and Clinical Immunology*. 2016;**137**:301-304. DOI: 10.1016/j.jaci.2015.11.001

[99] Mackay-Wiggan J, Sallee BN, Wang EHC, Sansaricq F, Nguyen N, Kim C, et al. An open-label study evaluating the efficacy of abatacept in alopecia areata. *Journal of the American Academy of Dermatology*. 2021;**84**:841-844. DOI: 10.1016/j.jaad.2020.09.091

[100] Zheng H, Kong L, Chen L, Zhang H, Zheng W. Acute effects of alcohol on the human brain: A resting-state fMRI study. *Bio Med Research International*. 2015;**2015**:947529

[101] King B, Ohyama M, Kwon O, Zlotogorski A, Ko J, Mesinkovska NA, et al. Two phase 3 trials of Baricitinib for alopecia areata. *The New England Journal of Medicine*. 2022;**386**:1687-1699. DOI: 10.1056/NEJMoa2110343

[102] Liu LY, Craiglow BG, Dai F, King BA. Tofacitinib for the treatment of severe alopecia areata and variants: A study of 90 patients. *Journal of the American Academy of Dermatology*. 2017;**76**:22-28. DOI: 10.1016/j.jaad.2016.09.007

[103] Mackay-Wiggan J, Jabbari A, Nguyen N, Cerise JE, Clark C, Ulerio G, et al. Oral ruxolitinib induces hair regrowth in patients with moderate-to-severe alopecia areata. *JCI Insight*. 2016;**1**:e89790. DOI: 10.1172/jci.insight.89790

[104] King B, Guttman-Yassky E, Peeva E, Banerjee A, Sinclair R, Pavel AB, et al. A phase 2a randomized, placebo-controlled study to evaluate the efficacy and safety

of the oral Janus kinase inhibitors ritlecitinib and brepocitinib in alopecia areata: 24-week results. *Journal of the American Academy of Dermatology*. 2021;**85**:379-387. DOI: 10.1016/j.jaad.2021.03.050

[105] Bokhari L, Sinclair R. Treatment of alopecia universalis with topical Janus kinase inhibitors - a double blind, placebo, and active controlled pilot study. *International Journal of Dermatology*. 2018;**57**:1464-1470. DOI: 10.1111/ijd.14192

Section 3

Cicatricial Alopecia

Treatment of Frontal Fibrosing Alopecia and Lichen Planopilaris

*María Librada Porriño-Bustamante
and María Antonia Fernández-Pugnaire*

Abstract

The aim of the treatment in frontal fibrosing alopecia and lichen planopilaris is to alleviate symptoms and to arrest the progression of the hair loss, since hair regrowth is not possible once the destruction of hair follicle has happened. Topical corticosteroids and tacrolimus are used to reduce inflammation, but with no clear benefit in slowing the alopecia. Intralesional corticosteroids may obtain hair regrowth in some patients, and they are especially useful in the treatment of eyebrow alopecia in frontal fibrosing alopecia. Regarding systemic treatments, the use of 5-alpha reductase inhibitors has been shown to be the most effective one to get stabilization in frontal fibrosing alopecia and even regrowth in the hairline. Hydroxychloroquine and oral immunomodulators are especially helpful as oral treatment in lichen planopilaris. Low-dose oral isotretinoin is the preferred treatment for facial papules in frontal fibrosing alopecia. The combination of oral and topical treatments is the best therapeutic choice.

Keywords: frontal fibrosing alopecia, lichen planopilaris, scarring alopecia, cicatricial alopecia, treatment

1. Introduction

Frontal fibrosing alopecia (FFA) and lichen planopilaris (LPP) are currently the most common types of scarring alopecia, especially the first one [1]. LPP was first described in 1895 by Pringle [2], while FFA was described in 1994 by Kossard [3], although the latter has become the most prevalent.

Both belong to the lymphocytic cicatricial alopecia subtype and share the main histopathologic features, although there are some differences between them [4, 5]. They are mainly characterized by a lichenoid lymphocytic infiltrate around the upper follicle, that is isthmus and infundibulum, including the bulge area, where the stem cells are located, and concentric perifollicular lamellar fibrosis [6].

FFA is clinically characterized by frontal or temporoparietal hairline recession, leading to a cicatricial alopecic band without follicular openings. FFA is frequently associated with eyebrow alopecia, and sometimes eyelash alopecia or peripheral hair body loss (limbs, axillary, pubic) can be observed. Facial papules are another typical finding in FFA, which are normally distributed on the temples, but also on the cheeks or chin [7]. The classic LPP usually appears as multifocal scarring areas that may

coalesce in large alopecic areas, and which are more commonly located at the vertex and parietal scalp [5]. However, sometimes both conditions can present concomitantly, since up to 25% of patients with FFA may have also the classic form of LPP [7, 8]. Pruritus and trichodynia may be present in some patients. FFA and LPP also share some trichoscopic features, such as follicular hyperkeratosis and perifollicular erythema, which are usually more intense in LPP. The background of FFA is typically ivory-white, whereas in LPP is usually milky-red [9].

The aim of the treatment in both FFA and LPP is to alleviate symptoms – if they are present – and to stop or slow down the progression of the disease, since hair regrowth is not possible once the destruction of the hair follicle has happened. Photographic and trichoscopic control is really useful to assess the progression of the disease and the response to the treatment. Moreover, in FFA, the size of the alopecic band and the measurement from the frontal hairline to the glabella and from the temporal hairline to the eyebrows is highly advisable.

2. Frontal fibrosing alopecia management

The therapeutic management of FFA remains still challenging due to its unclear pathophysiology, the lack of double-blind prospective studies and the progressive and refractory nature of the disease. In fact, most of the studies about treatment in FFA are based on retrospective cohort studies and case reports. The best therapeutic option in FFA usually combines oral and topical or intralesional treatments. Topical and intralesional corticosteroids are first-line treatments due to their security profile, and 5-alpha reductase inhibitors are currently considered one of the most effective therapies in terms of disease stabilization [10, 11]. FFA is progressive and mostly irreversible, so an early diagnosis and treatment is mandatory to achieve the best results. However, in some cases, a poor outcome can be predicted despite the treatment, especially in patients with the diffuse form [12].

2.1 Topical and intralesional treatments

Potent topical corticosteroids are considered the first-line treatment and are recommended especially when inflammation signs are present. There is no clear benefit in slowing the progression of the alopecia, but their security profile and capacity to relieve symptoms support their use [13, 14]. Similar indication has the use of topical calcineurin inhibitors, either alone or associated with topical corticosteroids, although one report found a better outcome with them, in terms of stabilization, compared to a group of patients treated with corticosteroids [15, 16]. Topical calcineurin inhibitors are also useful to spare topical corticosteroids. However, topical treatments are not usually used in monotherapy, which makes it difficult for a proper assessment of their real efficacy.

Topical minoxidil has not shown clinical improvement in slowing down the alopecia, but it is useful when androgenetic alopecia is associated or to improve the remaining hair [13].

In the case of eyebrow and eyelash alopecia, the use of a prostaglandin analogue, such as bimatoprost 0.03% eye drops, applied twice daily, may be a therapeutic option [17].

Eyebrow alopecia in FFA usually does not improve with systemic treatment alone, so another associated therapy is recommended [18]. In that case, the use

of intralesional corticosteroids, 10 mg/ml of triamcinolone acetonide every three months, may obtain hair regrowth in some patients, especially when the hair loss is partial. A higher concentration of triamcinolone acetonide – 20 mg/ml - can be used in the hairline implantation, every 3 to 6 months, and it may obtain stabilization and even hair regrowth in a considerable number of patients [19].

There is only one study about platelet-rich plasma (PRP) in FFA. These authors reported one patient who had an improvement in the trichoscopic signs and a stoppage in the progression of the alopecia after five treatments, with a one-month interval of injections in the frontotemporal hairline and eyebrows [20].

2.2 Systemic treatments

Nowadays, oral 5-alpha reductase inhibitors are considered the most effective treatment for FFA. In a report about 102 patients with FFA treated with finasteride (2.5–5 mg/day), which inhibits the isoenzyme type II of 5-alpha reductase, 47% of them showed improvement and 53% of them showed stabilization of the alopecia [19]. Dutasteride is about three times as potent as finasteride at inhibiting type II 5-alpha reductase and more than 100 times as effective at inhibiting type I [21]. A recent study including 224 FFA patients found a significantly higher stabilization rate in those under treatment with dutasteride – around 64% - compared to other systemic treatments, such as finasteride, hydroxychloroquine, doxycycline and isotretinoin [11]. Moreover, the response was dose-dependent, and the most effective dose was five to seven capsules of dutasteride (0.5 mg) per week. Thus, 5-alpha reductase inhibitors are considered, by most authors, the first therapeutic option in patients with FFA, [22] while others considered them as a second-line therapy [23]. Due to its higher effectivity, dutasteride may be a suitable first option, except for childbearing age women, in which finasteride should be considered because of its shortest wash-out period [22].

Antimalarials, such as hydroxychloroquine, may improve symptoms and signs of FFA, with better results seen within the first six months of therapy, although they normally achieve partial responses [24]. Other reports have not found any consistent benefit with the use of hydroxychloroquine [14]. A recent systematic review found that hydroxychloroquine and 5-alpha reductase inhibitors resulted to be the most effective therapies in terms of disease stabilization [10].

Tetracyclines, such as doxycycline, have been used for their anti-inflammatory effects in patients with FFA, often after antimalarial failure, but the response rates are low and not consistent [24, 25].

Treatment with oral prednisone (0.5–1 mg/kg/day), for 3 to 18 months, has been shown to produce a stoppage of the progression of the alopecia in almost 43% of patients, but relapse occurs after its discontinuation [13]. Therefore, the worse security profile in long-lasting treatments, and the relapse when the treatment is stopped, move this therapeutic option from the first-line treatments.

Oral retinoids, isotretinoin (20 mg/day) and acitretin (20 mg/day) have been shown to produce a stoppage in the hairline recession in 76% and 73% of patients, respectively, in a retrospective analysis, in which they were even more effective than finasteride (5 mg/day) in stopping the progression of the alopecia [26]. Isotretinoin may be useful in patients with facial papules, which may improve in two to four months with low doses such as 10 mg/day or even less. The improvement of erythema and perifollicular hyperkeratosis has also been reported in patients under treatment with isotretinoin (10–20 mg/day) [27]. Regarding other oral retinoids, such as

alitretinoin, only one report of a woman has been published, in which she showed improvement after one month with 30 mg/day [28]. Facial papules improvement has also been noted with the use of oral prednisone and hydroxychloroquine, after at least 6 months of treatment [29, 30].

Other treatments, such as griseofulvin or azathioprine have shown inconsistent outcomes or no efficacy [3, 24, 31–33]. Partial responses have been described in around 60% of patients who were treated with mycophenolate mofetil [24]. Stabilization of a few patients who were under treatment with methotrexate has been observed [25, 34].

Low-dose oral minoxidil may improve the background hair thickness, although further studies about its use in FFA are needed [35]. Its addition to the treatment may be interesting to increase hair volume, especially when androgenetic alopecia is present [36]. In some patients with FFA and concomitant androgenetic alopecia, who were treated with oral minoxidil, partial or complete eyebrow regrowth was noted [37]. Therefore, low-dose oral minoxidil (0.25–2.5 mg/day) may be an interesting adjuvant therapy for the treatment of eyebrow alopecia in patients with FFA, particularly in early disease.

Regarding the use of the oral pioglitazone hydrochloride (15 mg/day), a peroxisome proliferator-activated receptor γ (PPAR- γ) agonist, inconsistent results have been found when using it in LPP, but no successful outcomes have been observed in FFA patients [25, 38, 39].

The pan-Janus Kinase (JAK) inhibitor, tofacitinib, 10–15 mg/day, was used in some patients with refractory LPP (8/10) and FFA (2/10), from two to nineteen months; 80% of patients showed a clinical response, including clinical improvement in both FFA patients [40]. Baricitinib, a JAK 1 and 2 inhibitor, was used in a woman with refractory subacute cutaneous lupus erythematosus and FFA and resulted in completed clearance of the former and no further progression of the latter [41]. JAK inhibitors might be used as a therapeutic option in the future. An isolated report about a woman with recalcitrant FFA and LPP, who improved after the treatment with tildrakizumab, an anti p19 interleukin 23 monoclonal antibodies, was also published; the dose the authors used was 100 mg subcutaneously at week zero, 4 and subsequently 12 weekly, for around 4 to 13 months [42].

2.3 Treatments based on light devices

Some authors found that the excimer laser may be useful in reducing inflammation and perifollicular hyperkeratosis in patients with active LPP and FFA [43]. Photobiomodulation therapy, also known as low-level laser (light) therapy (LLLT), using light-emitting diodes (LEDs), may be an adjuvant option to consider in patients with FFA or LPP. A report found that LEDs may produce an improvement in symptoms and perifollicular hyperkeratosis, because of their anti-inflammatory and immunomodulatory effects, and may even increase the number of thick hairs within the treated area [44]. Moreover, LEDs treatment can also improve eyebrow alopecia in FFA patients, as was found in a study carried out on 16 women, in which an increase in hair count and in the number of thick and mid-thick hairs were noted, especially in cases of partial eyebrow alopecia [45].

A study about Nd:YAG (1064) non-ablative laser, carried out on 5 FFA patients, found improvement in symptoms and in perifollicular hyperkeratosis and follicular erythema in some patients [46]. Moreover, facial papules, lichen planus pigmentosus and hair loss spreading, also improved in some patients.

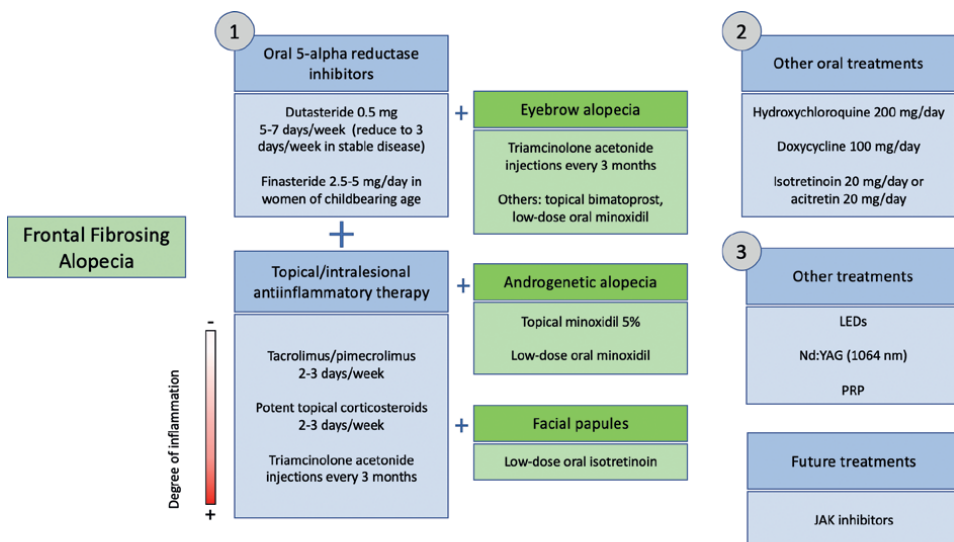
2.4 Hair transplant and covering options

Hair transplant may be considered in selected cases of FFA, but a minimum of one to five years without activity is recommended [47, 48]. However, patients with FFA should be warned about the hair graft survival rates, since a rate lower than 60% has been reported, independently of the period of time since clinical remission [49]. Therefore, hair transplant may be considered only in small areas of the scalp or in eyebrows, and always after discussing with the patient the long-term survival rates of the hair grafts [49, 50].

In advanced cases of FFA, wigs or hair systems could be interesting options to add to the medical therapy, as well as eyebrow micropigmentation in cases of eyebrow alopecia.

2.5 Therapeutic algorithm for FFA

A therapeutic algorithm for FFA is proposed in **Figure 1**, with different lines of treatment indicated with the circled numbers.



LEDs: light-emitting diodes; PRP: platelet-rich plasma; JAK: Janus Kinase.

Figure 1.
 Therapeutic algorithm for FFA.

3. Lichen planopilaris management

There is no curative therapy for LPP. Therefore, the main goal of the treatment is to reduce the inflammatory symptoms and to slow the progression of hair loss, since hair regrowth is not possible when scarring has happened.

No gold standard approach exists to the treatment of LPP. Moreover, the publications about the treatment of LPP are quite sparse and the therapies they are referred to have limited evidence. Only a few of them are controlled trials. Furthermore, the

evidence shows a varied response to therapy, with frequent reports showing poor outcomes [51–53]. There are some recommendations for the treatment of LPP, but no specific therapy guidelines. Hence, daily clinical practice often relies on disease activity, age, comorbidities, and the physician's personal experience [54]. Patients with LPP experience significantly impaired quality of life and mental health associated with disease activity, and the potentially permanent hair loss highlights the importance of early disease detection and treatment [55].

3.1 Topical and intralesional treatments

Topical steroids are often reported as a first-line treatment, especially the ultrapotent corticosteroid clobetasol propionate, for cases with a limited extent. They help to reduce inflammation and associated symptoms, including burning sensation and itchiness [12, 35]. A proposed protocol consists of using topical steroids twice daily for the first month, followed by an application once a day for 3 months, and then every other day for 3 more months [56].

Monthly intralesional high potency corticosteroids have similar outcomes to topical steroids regarding efficacy. Injections of triamcinolone acetonide at a concentration of 10 mg/mL –2 mL in total - every 4 to 6 weeks until disease stabilization, are recommended for the treatment of LPP by the researchers of the University of British Columbia [57]. They also suggest that if there is no improvement after three months of injections, other treatment options should be considered. There is no clear evidence about which delivery mode is better, although Lyakhovitsky et al. and Mehregan et al., propose that topical and intralesional corticosteroids can be used together to achieve a faster clinical response [58, 59].

Topical calcineurin inhibitors also reduce inflammation and help to induce the early anagen phase of the hair cycle. However, the largest study of topical calcineurin inhibitors, which included ten patients with LPP, reported inflammation improvement in only two patients (one on monotherapy and another one associated with hydroxychloroquine) [58].

Topical minoxidil improves the caliber and condition of the hairs of the background, but irritative and allergic contact dermatitis, in an already inflamed scalp, are common adverse effects [60]. A combination of topical tacrolimus 0.3%, clobetasol propionate 0.05%, and minoxidil 5%, can be applied twice daily as first-line therapy, along with intralesional triamcinolone acetonide. When the disease stabilizes, the clobetasol dose is the one to be decreased or discontinued first, followed by the tacrolimus dose [54].

The efficacy and safety of PRP in cicatricial alopecia, including LPP, remain unknown. In a recent case series of 10 patients with LPP and FFA, who received PRP mesotherapy, no koebnerization or development of new areas of involvement were noted, although the clinical improvement was unclear due to the multitherapy regimens done by the patients [61].

3.2 Systemic treatments

Oral treatments are indicated for patients with local treatment resistance, more extensive manifestations, scalp involvement $\geq 10\%$ and those with rapid progression.

Hydroxychloroquine is often preferred as the first-line systemic agent because of its relatively good side-effect profile. There are several case series regarding hydroxychloroquine as monotherapy or in combination with other agents, with

varied outcomes, and overall, treatment response was seen in approximately 50–60% of cases [58, 62, 63]. Conversely, other small case series or single case reports showed little or no response [64]. Action onset occurs after two to three weeks, and the peak of response is achieved after six months. Hydroxychloroquine may be initially administered at 200 mg, twice daily, with the goal to decrease to weight-based dosing of 5 mg/kg/day, for a 6 to 12-month period [54].

Immunomodulators are therapeutic alternatives for patients with difficult-to-control disease. Some options pointed out in the literature are methotrexate, cyclosporine and mycophenolate mofetil [65].

A randomized clinical trial comparing hydroxychloroquine (400 mg daily) and methotrexate (15 mg weekly), for a 6-month period in recalcitrant LPP, found a significant superiority of methotrexate over hydroxychloroquine. Moreover, patients in the hydroxychloroquine group showed only a significant improvement in erythema, while patients in the methotrexate group showed efficacy on pruritus as well as on all the objective variables assessed in the study (erythema, perifollicular erythema, perifollicular scaling, spreading, and follicular keratosis). The negative outcomes observed in the patients belonging to the hydroxychloroquine group could be due to the fact that the study was only focused on recalcitrant cases [66]. In a retrospective study, the response rates of cyclosporine and methotrexate were similar (100% and 85%, respectively), and those treated with cyclosporine achieved partial and complete remission faster than the methotrexate group patients. However, both treatments were less safe compared to mycophenolate mofetil [52].

On the other hand, a randomized controlled trial for evaluating the safety and efficacy of methotrexate (15 mg, oral, per week) versus cyclosporine (3–5 mg/kg/day), for six months, in patients with refractory LPP, found similar efficacy at the end of the study with both treatments. Nevertheless, the authors proposed methotrexate as the first choice over cyclosporine because of its easier administration, fewer tolerable side effects and lower recurrence rates [67]. Other studies regarding cyclosporine in LPP also revealed considerable outcomes, although high relapse rates are common after its discontinuation [53, 56, 68].

Mycophenolate mofetil may be another potential treatment for patients with severe or recalcitrant LPP who have failed hydroxychloroquine and other immunomodulators [69, 70]. Six studies were included in a recent systematic review and meta-analysis, including 94 patients, in which 69.2% of patients had a good response (partial or complete), with dosages ranging from 1 to 6 g daily, and treatment duration ranging from 2 to 12 months [71].

Limited evidence supports the therapeutic potential of JAK inhibitors for the treatment of recalcitrant LPP, and in most published reports the patients were treated with other concomitant therapies [40]. A report which investigated the usefulness of topical and oral tofacitinib as an adjuvant treatment in 9 patients with recalcitrant LPP, found that both formulations were effective in achieving a positive clinical response. The median time to see any treatment response was 3 months. Authors concluded that although oral tofacitinib led to a more pronounced and sustained improvement, topical therapy may be considered a feasible alternative in some patients [72]. A report about the use of baricitinib in patients with refractory LPP (7/12) and FFA (5/12) (median dose of 3.4 mg and concomitant treatments in all of the patients), showed that 46.5% and 83.8% of patients, respectively, demonstrated an initial reduction in the median Lichen Planopilaris Activity Index (LPPAI) score. However, the response was maintained in only 3 out of 7 LPP patients and in 2 out

of 5 FFA patients, after a median duration of 6 months. Furthermore, 4 patients had previously had a failure with oral tofacitinib treatment, which may predict a possible absence of response to another JAK inhibitor [73].

Oral glucocorticoids should be reserved for very symptomatic patients and those with rapid progression, due to their potential adverse effects and the very high degree of relapse (around 80% of patients) after treatment discontinuation [54, 74]. Some authors utilize short courses in rapidly progressive cases, usually prescribed at 40 mg daily for 1 week, then tapered by 5 mg weekly for 8 weeks, acting as a bridge to the effect of longer-lasting drugs, such as methotrexate [75].

The first study describing the use of low-dose of oral minoxidil (LDM) in LPP showed that LDM (median dosage 1 mg/day), with a mean duration of therapy of 21 months, can help to maintain or increase hair thickness in the majority of patients with LPP, in unaffected and potentially affected areas, with an acceptable safety profile. Better results were reported in patients presenting diffuse LPP and with the higher doses of LDM used in male patients [35].

Regarding low dose naltrexone for the treatment of LPP, only one case series including four patients has been published, which showed some therapeutic benefits, including a decrease in inflammation and in the presence of inflammatory symptoms, along with slowing in the disease progression [76].

Other systemic treatment options, such as doxycycline (100 mg twice daily), have shown limited outcomes [58, 60, 77].

3.3 Treatments based on light devices

LLLT is an emerging light therapy that has shown effectiveness in treating several inflammatory skin disorders, such as lichen planus. Nevertheless, the reports about its use are limited [78], and there are just two studies about LLLT for the treatment of LPP. The first study, which included a total of 8 patients, showed a global reduction of symptoms, erythema, and perifollicular hyperkeratosis in all patients after 6 months of intervention [79]. Another report showed consistent improvement with reduction of inflammation, the disappearance of symptoms, and evident hair regrowth after 3 and 6 months, in a total of 4 patients whose disease had remained active despite topical and/or systemic treatments [80]. Limitations of this treatment could be the daily regimen and the lack of clear treatment protocol and parameters.

3.4 Hair transplant

The outcomes of transplantation in patients with LPP vary because of the autoimmune nature, so surgical procedures may trigger the Köebner phenomenon and induce new lesions in recipient and donor areas [47]. Hence, most of the authors believe that transplantation can be considered in patients with clinical remission of at least two years in order to keep the final outcome of transplantation and induce hair regrowth. Regarding the technique, FUE (follicular unit extraction) is preferred due to the following advantages: the absence of suture wounds and linear scars, less bleeding and less postoperative discomfort. Furthermore, these patients require close postoperative follow and long-term observation to determine the final outcomes of the treatment. If perifollicular keratosis or erythema is noted, medical modalities such as topical/intralesional steroid injections and/or oral medications should be given to prevent further hair loss [81, 82].

3.5 Therapeutic algorithm for LPP

A therapeutic algorithm for LPP is proposed in **Figure 2**, with different lines of treatment indicated with the circled numbers.

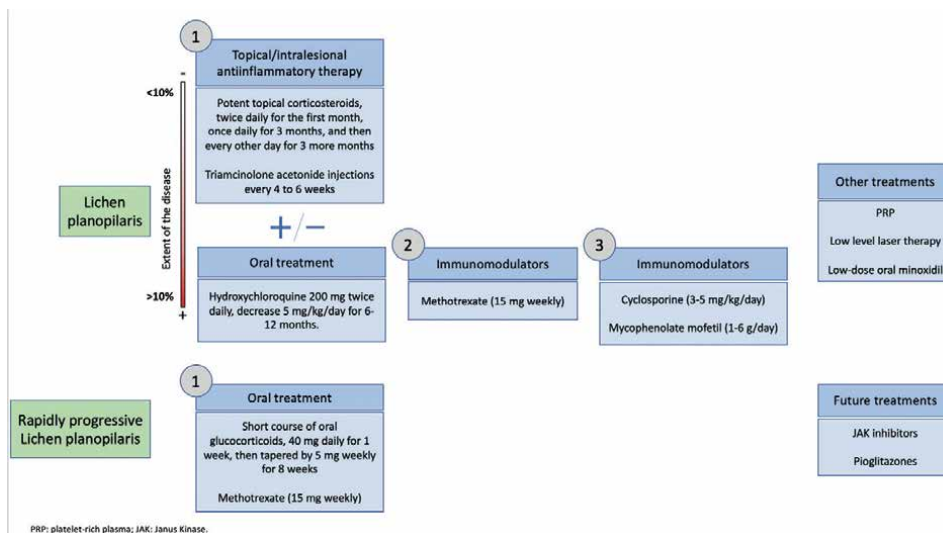


Figure 2.
 Therapeutic algorithm for LPP.

4. Conclusions

The best therapeutic option in FFA should include both topical and oral treatments. Five-alpha reductase inhibitors, especially dutasteride, have shown to be one of the most effective treatments in stopping hairline recession, and they should be used as first-line therapy in FFA patients. A topical anti-inflammatory drug should be added with a maintenance frequency regimen, that is, topical calcineurin inhibitors or topical corticosteroids, or even intralesional corticosteroids, depending on the degree of inflammation. When androgenetic alopecia is associated, adding topical or oral minoxidil may achieve better outcomes. In the case of eyebrow alopecia, especially in early stages, intralesional corticosteroids are recommended, although the use of oral minoxidil may also be helpful. In patients with facial papules, low-dose oral isotretinoin should be added to the treatment.

Regarding LPP, treatment commonly involves the use of high potency topical and/or intralesional corticosteroids in cases with limited involvement and orally administered hydroxychloroquine in cases of progressive course or extensive cases. When therapy with hydroxychloroquine fails, methotrexate could be used as a second-line therapy, while mycophenolate mofetil and cyclosporine could be considered as third-line therapies. A short course of systemic steroids should be considered only in rapidly progressive and severe cases, acting as a bridge to the effect of longer-lasting drugs, such as methotrexate. Pioglitazone could be a promising and effective therapeutic option, although more evidence is needed to confirm its precise role in LPP management.

Conflict of interest

The authors declare no conflict of interest.

Author details

María Librada Porriño-Bustamante^{1,2*} and María Antonia Fernández-Pugnaire³


1 Dermatology Department, University Hospital La Zarzuela, Madrid, Spain

2 Trichology Unit, Pedro Jaén Group, Madrid, Spain

3 Dermatology Department, University Hospital San Cecilio, Granada, Spain

*Address all correspondence to: mporrinobustamante@gmail.com

IntechOpen

© 2022 The Author(s). Licensee IntechOpen. This chapter is distributed under the terms of the Creative Commons Attribution License (<http://creativecommons.org/licenses/by/3.0>), which permits unrestricted use, distribution, and reproduction in any medium, provided the original work is properly cited. 

References

- [1] Vañó-Galván S, Saceda-Corralo D, Blume-Peytavi U, et al. Frequency of the types of alopecia at twenty-two specialist hair clinics: A multicenter study. *Skin Appendage Disorders*. 2019;**5**(5):309-315. DOI: 10.1159/000496708
- [2] Pringle JJ. Cited by Adamson HG. Lichen pilaris spinulosus. *British Journal of Dermatology*. 1905;**17**:78-79
- [3] Kossard S. Postmenopausal frontal fibrosing alopecia. Scarring alopecia in a pattern distribution. *Archives of Dermatology*. 1994;**130**(6):770-774
- [4] Gálvez-Canseco A, Sperling L. Lichen planopilaris and frontal fibrosing alopecia cannot be differentiated by histopathology. *Journal of Cutaneous Pathology*. 2018;**45**(5):313-317. DOI: 10.1111/cup.13112
- [5] Poblet E, Jiménez F, Pascual A, Piqué E. Frontal fibrosing alopecia versus lichen planopilaris: A clinicopathological study. *International Journal of Dermatology*. 2006;**45**(4):375-380. DOI: 10.1111/j.1365-4632.2006.02507.x
- [6] Mirmirani P, Willey A, Headington JT, Stenn K, McCalmont TH, Price VH. Primary cicatricial alopecia: Histopathologic findings do not distinguish clinical variants. *Journal of the American Academy of Dermatology*. 2005;**52**(4):637-643. DOI: 10.1016/j.jaad.2004.07.069
- [7] Porriño-Bustamante ML, Fernández-Pugnaire MA, Arias-Santiago S. Frontal Fibrosing alopecia: A review. *Journal of Clinical Medicine*. 2021;**10**(9):1805. DOI: 10.3390/jcm10091805
- [8] Mervis JS, Borda LJ, Miteva M. Facial and Extrafacial lesions in an ethnically diverse series of 91 patients with frontal Fibrosing alopecia followed at a single center. *Dermatology*. 2019;**235**(2):112-119. DOI: 10.1159/000494603
- [9] Rudnicka L, Olszewska M, Rakowska A, Slowinska M. Trichoscopy update 2011. *Journal of Dermatology Case Reports*. 2011;**5**(4):82-88. DOI: 10.3315/jdc.2011.1083
- [10] Dina Y, Aguh C. Algorithmic approach to the treatment of frontal Fibrosing alopecia-a systematic review. *Journal of the American Academy of Dermatology*. 2021;**85**(2):508-510. DOI: 10.1016/j.jaad.2018.10.043
- [11] Pindado-Ortega C, Saceda-Corralo D, Moreno-Arrones OM, et al. Effectiveness of dutasteride in a large series of patients with frontal fibrosing alopecia in real clinical practice. *Journal of the American Academy of Dermatology*. 2021;**84**(5):1285-1294. DOI: 10.1016/j.jaad.2020.09.093
- [12] Moreno-Arrones OM, Saceda-Corralo D, Fonda-Pascual P, et al. Frontal fibrosing alopecia: clinical and prognostic classification. *Journal of the European Academy of Dermatology and Venereology*. 2017;**31**(10):1739-1745. DOI: 10.1111/jdv.14287
- [13] Moreno-Ramírez D, Ferrándiz L, Camacho FM. Diagnostic and therapeutic assessment of frontal fibrosing alopecia. *Actas Dermo-Sifiliográficas*. 2007;**98**(9):594-602
- [14] MacDonald A, Clark HS. Frontal fibrosing alopecia: A review of 60 cases. *Journal of the American Academy of Dermatology*. 2012;**67**(5):955-961. DOI: 10.1016/j.jaad.2011.12.038
- [15] Heppt MV, Letulé V, Laniauskaite I, et al. Frontal Fibrosing alopecia: A

retrospective analysis of 72 patients from a German academic center. *Facial Plastic Surgery*. 2018;**34**(1):88-94. DOI: 10.1055/s-0037-1615281

[16] Strazzulla LC, Avila L, Li X, Lo Siccò K, Shapiro J. Prognosis, treatment, and disease outcomes in frontal fibrosing alopecia: A retrospective review of 92 cases. *Journal of the American Academy of Dermatology*. 2018;**78**(1):203-205. DOI: 10.1016/j.jaad.2017.07.035

[17] Murad A, Bergfeld W. Prostaglandin analogue for treatment of eyebrow loss in frontal fibrosing alopecia: Three cases with different outcomes. *Journal of the European Academy of Dermatology and Venereology*. 2021;**35**(2):e138-e140. DOI: 10.1111/jdv.16870

[18] Donovan JC, Samrao A, Ruben BS, Price VH. Eyebrow regrowth in patients with frontal fibrosing alopecia treated with intralesional triamcinolone acetonide. *The British Journal of Dermatology*. 2010;**163**(5):1142-1144. DOI: 10.1111/j.1365-2133.2010.09994.x

[19] Vañó-Galván S, Molina-Ruiz AM, Serrano-Falcón C, et al. Frontal fibrosing alopecia: A multicenter review of 355 patients. *Journal of the American Academy of Dermatology*. 2014;**70**(4):670-678. DOI: 10.1016/j.jaad.2013.12.003

[20] Özcan D, Tunçer Vural A, Özen Ö. Platelet-rich plasma for treatment resistant frontal fibrosing alopecia: A case report. *Dermatologic Therapy*. 2019;**32**(5):e13072. DOI: 10.1111/dth.13072

[21] Georgala S, Katoulis AC, Befon A, Danopoulou I, Georgala C. Treatment of postmenopausal frontal fibrosing alopecia with oral dutasteride. *Journal of the American Academy of Dermatology*.

2009;**61**(1):157-158. DOI: 10.1016/j.jaad.2008.12.026

[22] Pindado-Ortega C, Saceda-Corralo D, Moreno-Arrones Ó, et al. Response to “reply to effectiveness of dutasteride in a large series of patients with FFA in real clinical practice”. *Journal of the American Academy of Dermatology*. 2021;**85**(2):e95-e96. DOI: 10.1016/j.jaad.2021.03.084

[23] Murad A, Bergfeld WF. Reply to effectiveness of dutasteride in a large series of patients with frontal fibrosing alopecia in real clinical practice. *Journal of the American Academy of Dermatology*. 2021;**85**(2):e93. DOI: 10.1016/j.jaad.2021.02.089

[24] Samrao A, Chew AL, Price V. Frontal fibrosing alopecia: A clinical review of 36 patients. *The British Journal of Dermatology*. 2010;**163**(6):1296-1300. DOI: 10.1111/j.1365-2133.2010.09965.x

[25] Ladizinski B, Bazakas A, Selim MA, Olsen EA. Frontal fibrosing alopecia: A retrospective review of 19 patients seen at Duke University. *Journal of the American Academy of Dermatology*. 2013;**68**(5):749-755. DOI: 10.1016/j.jaad.2012.09.043

[26] Rakowska A, Gradzinska A, Olszewska M, Rudnicka L. Efficacy of isotretinoin and Acitretin in treatment of frontal Fibrosing alopecia: Retrospective analysis of 54 cases. *Journal of Drugs in Dermatology*. 2017;**16**(10):988-992

[27] Mahmoudi H, Rostami A, Tavakolpour S, et al. Oral isotretinoin combined with topical clobetasol 0.05% and tacrolimus 0.1% for the treatment of frontal fibrosing alopecia: A randomized controlled trial. *The Journal of Dermatological Treatment*. 2022;**33**(1):284-290. DOI: 10.1080/09546634.2020.1750553

- [28] Lee JY, Hong JS, Lee SH, Lee A. Successful treatment of frontal fibrosing alopecia with alitretinoin. *Dermatologic Therapy*. 2019;**32**(5):e13037. DOI: 10.1111/dth.13037
- [29] Pedrosa AF, Duarte AF, Haneke E, Correia O. Yellow facial papules associated with frontal fibrosing alopecia: A distinct histologic pattern and response to isotretinoin. *Journal of the American Academy of Dermatology*. 2017;**77**(4):764-766. DOI: 10.1016/j.jaad.2017.04.1118
- [30] Donati A, Molina L, Doche I, Valente NS, Romiti R. Facial papules in frontal fibrosing alopecia: Evidence of vellus follicle involvement. *Archives of Dermatology*. 2011;**147**(12):1424-1427. DOI: 10.1001/archdermatol.2011.321
- [31] Kossard S, Lee MS, Wilkinson B. Postmenopausal frontal fibrosing alopecia: A frontal variant of lichen planopilaris. *Journal of the American Academy of Dermatology*. 1997;**36**(1):59-66. DOI: 10.1016/s0190-9622(97)70326-8
- [32] Tosti A, Piraccini BM, Iorizzo M, Misciali C. Frontal fibrosing alopecia in postmenopausal women. *Journal of the American Academy of Dermatology*. 2005;**52**(1):55-60. DOI: 10.1016/j.jaad.2004.05.014
- [33] Faulkner CF, Wilson NJ, Jones SK. Frontal fibrosing alopecia associated with cutaneous lichen planus in a premenopausal woman. *The Australasian Journal of Dermatology*. 2002;**43**(1):65-67. DOI: 10.1046/j.1440-0960.2002.00558.x
- [34] Morandi Stumpf MA, do Rocio Valenga Baroni E, Schafranski MD. Frontal Fibrosing alopecia: Successfully treated with methotrexate or just the natural disease progression? *Acta Dermatovenerologica Croatica*. 2020;**28**(3):188-189
- [35] Vano-Galvan S, Trindade de Carvalho L, Saceda-Corralo D, et al. Oral minoxidil improves background hair thickness in lichen planopilaris. *Journal of the American Academy of Dermatology*. 2021;**84**(6):1684-1686. DOI: 10.1016/j.jaad.2020.04.026
- [36] Sinclair RD. Female pattern hair loss: A pilot study investigating combination therapy with low-dose oral minoxidil and spironolactone. *International Journal of Dermatology*. 2018;**57**(1):104-109. DOI: 10.1111/ijd.13838
- [37] Pirmez R, Spagnol AL. Eyebrow regrowth in patients with frontal Fibrosing alopecia treated with low-dose Oral Minoxidil. *Skin Appendage Disorders*. 2021;**7**(2):112-114. DOI: 10.1159/000511744
- [38] Mirmirani P, Karnik P. Lichen planopilaris treated with a peroxisome proliferator-activated receptor gamma agonist. *Archives of Dermatology*. 2009;**145**(12):1363-1366. DOI: 10.1001/archdermatol.2009.283
- [39] Spring P, Spanou Z, de Viragh PA. Lichen planopilaris treated by the peroxisome proliferator activated receptor- γ agonist pioglitazone: Lack of lasting improvement or cure in the majority of patients. *Journal of the American Academy of Dermatology*. 2013;**69**(5):830-832. DOI: 10.1016/j.jaad.2013.04.066
- [40] Yang CC, Khanna T, Salle B, Christiano AM, Bordone LA. Tofacitinib for the treatment of lichen planopilaris: A case series. *Dermatologic Therapy*. 2018;**31**(6):e12656. DOI: 10.1111/dth.12656
- [41] Kreuter A, Licciardi-Fernandez MJ, Burmann SN, Paschos A,

Michalowicz AL. Baricitinib for recalcitrant subacute cutaneous lupus erythematosus with concomitant frontal fibrosing alopecia. *Clinical and Experimental Dermatology*. 2022;**47**(4):787-788. DOI: 10.1111/ced.15044

[42] Trindade de Carvalho L, Meah N, Wall D, Sinclair R. Recalcitrant lichen planopilaris and frontal fibrosing alopecia responding to tildrakizumab. *Dermatologic Therapy*. 2020;**33**(4):e13694. DOI: 10.1111/dth.13694

[43] Navarini AA, Kolios AG, Prinz-Vavricka BM, Haug S, Trüeb RM. Low-dose excimer 308-nm laser for treatment of lichen planopilaris. *Archives of Dermatology*. 2011;**147**(11):1325-1326. DOI: 10.1001/archdermatol.2011.335

[44] Gerkowicz A, Bartosinska J, Wolska-Gawron K, Michalska-Jakubus M, Kwasny M, Krasowska D. Application of superluminescent diodes (sLED) in the treatment of scarring alopecia - a pilot study. *Photodiagnosis and Photodynamic Therapy*. 2019;**28**:195-200. DOI: 10.1016/j.pdpdt.2019.09.006

[45] Gerkowicz A, Bartosinska J, Raczkiwicz D, Kwasny M, Krasowska D. Novel application of light-emitting diode therapy in the treatment of eyebrow loss in frontal Fibrosing alopecia. *Sensors (Basel)*. 2021;**21**(17):5981. DOI: 10.3390/s21175981

[46] Subash J, Eginli A, Bomar L, McMichael A. Frontal fibrosing alopecia treatment with Nd:YAG (1064 nm) nonablative laser. *International Journal of Women's Dermatology*. 2021;**7**(3):355-356. DOI: 10.1016/j.ijwd.2020.10.007

[47] Unger W, Unger R, Wesley C. The surgical treatment of cicatricial alopecia. *Dermatologic Therapy*.

2008;**21**(4):295-311. DOI: 10.1111/j.1529-8019.2008.00211.x

[48] Nusbaum BP, Nusbaum AG. Frontal fibrosing alopecia in a man: Results of follicular unit test grafting. *Dermatologic Surgery*. 2010;**36**(6):959-962. DOI: 10.1111/j.1524-4725.2010.01580.x

[49] Vañó-Galván S, Villodres E, Pigem R, et al. Hair transplant in frontal fibrosing alopecia: A multicenter review of 51 patients. *Journal of the American Academy of Dermatology*. 2019;**81**(3):865-866. DOI: 10.1016/j.jaad.2019.05.031

[50] Audickaite A, Alam M, Jimenez F. Eyebrow hair transplantation in frontal Fibrosing alopecia: Pitfalls of short- and long-term results. *Dermatologic Surgery*. 2020;**46**(7):922-925. DOI: 10.1097/DSS.0000000000002207

[51] Harries MJ, Messenger A. Treatment of frontal fibrosing alopecia and lichen planopilaris. *Journal of the European Academy of Dermatology*. 2014;**28**(10):1404-1405. DOI: 10.1111/jdv.12362

[52] Babahosseini H, Tavakolpur S, Mahmoudi H, et al. Lichen planopilaris: Retrospective study on the characteristics and treatment of 291 patients. *Journal of Dermatological Treatment*. 2019;**30**(6):598-604. DOI: 10.1080/09546634.2018.1542480

[53] Errichetti E, Figini M, Croatto M, Stinco G. Therapeutic management of classic lichen planopilaris: A systematic review. *Clinical, Cosmetic and Investigational Dermatology*. 2018;**11**:91-102. DOI: 10.2147/CCID.S137870

[54] Svigos K, Yin L, Fried L, Lo Sicco K, Shapiro J. A practical approach to the diagnosis and management of classic lichen Planopilaris. *American Journal of*

Clinical Dermatology. 2021;**22**(5):681-692. DOI: 10.1007/s40257-021-00630-7

[55] Nasimi M, Ahangari N, Lajevardi V, Mahmoudi H, Ghodsi SZ, Etesami I. Quality of life and mental health status in patients with lichen planopilaris based on dermatology life quality index and general health Questionnaire-28 questionnaires. *International Journal of Womens Dermatology*. 2020;**6**(5):399-403. DOI: 10.1016/j.ijwd.2020.09.005

[56] Assouly P, Reigagne P. Lichen planopilaris: Update on diagnosis and treatment. *Seminars in Cutaneous Medicine and Surgery*. 2009;**28**(1):3-10. DOI: 10.1016/j.sder.2008.12.006

[57] Tan E, Martinka M, Ball B, Shapiro J. Primary cicatricial alopecias: Clinicopathology of 112 cases. *Journal of the American Academy of Dermatology*. 2004;**50**:25-32. DOI: 10.1016/j.jaad.2003.04.001

[58] Lyakhovitsky A, Amichai B, Sizopoulou C, Barzilai A. A case series of 46 patients with lichen planopilaris: Demographics, clinical evaluation, and treatment experience. *The Journal of Dermatological Treatment*. 2015;**26**:275-279. DOI: 10.3109/09546634.2014.933165

[59] Mehregand DA, Hale HM, Muller SA. Lichen planopilaris: Clinical and pathologic study of forty-five patients. *Journal of the American Academy of Dermatology*. 1992;**27**:935-942. DOI: 10.1016/0190-9622(92)70290-v

[60] Therianou A, Vincenzi C, Tosti A. How safe is prescribing oral minoxidil in patients allergic to topical minoxidil? *Journal of the American Academy of Dermatology*. 2022;**86**(2):429-431. DOI: 10.1016/j.jaad.2020.04.027

[61] Svigos K, Yin L, Shaw K, et al. Use of platelet-rich plasma in lichen planopilaris

and its variants: A retrospective case series demonstrating treatment tolerability without koebnerization. *Journal of the American Academy of Dermatology*. 2020;**83**(5):1506-1509. DOI: 10.1016/j.jaad.2020.06.026

[62] Dhonncha NE, Foley CC, Markham T. The role of hydroxychloroquine in the treatment of lichen planopilaris: A retrospective case series and review. *Dermatologic Therapy*. 2017;**30**(3). DOI: 10.1111/dth.12463

[63] Chiang C, Sah D, Cho BK, Ochoa BE, Price VH. Hydroxychloroquine and lichen planopilaris: Efficacy and introduction of lichen Planopilaris activity index scoring system. *Journal of the American Academy of Dermatology*. 2010;**62**(3):387-392. DOI: 10.1016/j.jaad.2009.08.054

[64] Donati A, Assouly P, Matard B, Jouanique C, Reygagne P. Clinical and photographic assessment of lichen planopilaris treatment efficacy. *Journal of the American Academy of Dermatology*. 2011;**64**(3):597-598. DOI: 10.1016/j.jaad.2010.04.045

[65] Fachine COC, Valente NYS, Romiti R. Lichen planopilaris and frontal fibrosing alopecia: Review and update of diagnostic and therapeutic features. *Anais Brasileiros de Dermatologia* 2022;S0365-0596(22)00046-0. DOI: 10.1016/j.abd.2021.08.008

[66] Naeini FF, Sabe M, Asilian A, Hosseini SM. Clinical efficacy and safety of methotrexate versus hydroxychloroquine in preventing lichen planopilaris progress: A randomized clinical trial. *International Journal of Preventive Medicine*. 2017;**8**:37. DOI: 10.4103/ijpvm.IJPVM_156_17

[67] Naeini FF, Mohaghegh F, Jelvan M, Asilian A, Saber M. Cyclosporine or

methotrexate, which one is more promising in the treatment of lichen planopilaris?; A comparative clinical trial. *International Immunopharmacology*. 2020;**86**:106765. DOI: 10.1016/j.intimp.2020.106765

[68] Mirmirani P, Willey A, Price VH. Short course of oral cyclosporine in lichen planopilaris. *Journal of the American Academy of Dermatology*. 2003;**49**(4):667-671. DOI: 10.1067/s0190-9622(03)00873-9

[69] Tursen U, Api H, Kaya T, Ikizoglu G. Treatment of lichen planopilaris with mycophenolate mofetil. *Dermatology Online Journal*. 2004;**10**(1):24

[70] Cho BK, Sah D, Chwalek J, et al. Efficacy and safety of mycophenolate mofetil for lichen planopilaris. *Journal of the American Academy of Dermatology*. 2010;**62**(3):393-397. DOI: 10.1016/j.jaad.2009.05.018

[71] Mostafa N, Phan K, Smith S. Mycophenolate mofetil and lichen planopilaris: Systematic review and meta-analysis. *Journal of Dermatological Treatment*. 2022;**33**(1):369-372. DOI: 10.1080/09546634.2020.1755416

[72] Plante J, Eason C, Snyder A, Elston D. Tofacitinib in the treatment of lichen planopilaris: A retrospective review. *Journal of the American Academy of Dermatology*. 2020;**83**(5):1487-1489. DOI: 10.1016/j.jaad.2020.05.104

[73] Moussa A, Bhojru B, Asfour L, Kazmi A, Eisman S, Sinclair RD. Treatment of lichen planopilaris with baricitinib: A retrospective study. *Journal of the American Academy of Dermatology*. 2022;**S0190-9622**(22):00338-00333. DOI: 10.1016/j.jaad.2022.02.027

[74] Kang H, Alzolibani AA, Otberg N, Shapiro J. Lichen planopilaris.

Dermatologic Therapy. 2008;**21**:249-256. DOI: 10.1111/j.1529-8019.2008.00206.x

[75] Manousaridis I, Manousaridis K, Peitsch WK, Schneider SW. Individualizing treatment and choice of medication in lichen planus: A step by step approach. *Journal der Deutschen Dermatologischen Gesellschaft*. 2013;**11**(10):981-991. DOI: 10.1111/ddg.12141

[76] Strazzulla LC, Avila L, Lo Sicco K, Shapiro J. Novel treatment using low-dose naltrexone for lichen planopilaris. *Journal of Drugs in Dermatology*. 2017;**16**(11):1140-1142

[77] Spencer LA, Hawryluk EB, English JC. Lichen planopilaris: Retrospective study and stepwise therapeutic approach. *Archives of Dermatology*. 2009;**145**:333-334. DOI: 10.1001/archdermatol.2008.590

[78] Al-Maweri SA, Kalakonda B, Al-Soneidar WA, Al-Shamiri HM, Alakhali MS, Alaizari N. Efficacy of low-level laser therapy in management of symptomatic oral lichen planus: A systematic review. *Lasers in Medical Science*. 2017;**32**(6):1429-1437. DOI: 10.1007/s10103-017-2233-7

[79] Fonda-Pascual P, Moreno-Arrones OM, Saceda-Corralo D, et al. Effectiveness of low-level laser therapy in lichen planopilaris. *Journal of the American Academy of Dermatology*. 2018;**78**(5):1020-1023. DOI: 10.1016/j.jaad.2017.11.040

[80] Randolph MJ, Al Salhi WA, Tosti A. Lichen Planopilaris and low-level light therapy: Four case reports and review of the literature about low-level light therapy and lichenoid dermatosis. *Dermatology Therapy (Heidelberg)*. 2020;**10**:311-319. DOI: 10.1007/s13555-020-00359-x

[81] Cevalco NC, Bergfeld WF, Remzi BK, de Knott HR. A case-series of 29 patients with lichen planopilaris: The Cleveland Clinic Foundation experience on evaluation, diagnosis, and treatment. *Journal of American Academic Dermatology*. 2007;57:47-53. DOI: 10.1016/j.jaad.2007.01.011

[82] Liu Y-CS, Jee S-H, Chan J-YL. Hair transplantation for the treatment of lichen planopilaris and frontal fibrosing alopecia: A report of two cases. *The Australasian Journal of Dermatology*. 2018;59(2):e118-e122. DOI: 10.1111/ajd.12682

Surgical Management of Scarring Alopecia

Nuh Evin and Seyda Guray Evin

Abstract

Cicatricial alopecia presents a heterogeneous group of disorders, which are characterized by the destruction of hair follicles, and resulting in scarring and irreversible hair loss. Cicatricial alopecia is classified into two categories depending on the target pathological process. In primary cicatricial alopecia (PCA), the hair follicle is the sole target of a progressive inflammatory process in various skin or systemic diseases. In secondary cicatricial alopecia (SCA), non-specific and generalized disruption of the skin and skin appendages results in fibrotic scarring of the skin and permanent loss of hair follicles due to underlying disease or an external agent. The aim of the treatment of PCA is to reduce inflammation and prevent progression to irreversible alopecia by using immunosuppressive and antimicrobial agents at the earliest phase of the disease. When permanent hair loss occurs in PCA and SCA, scar tissue should be removed or camouflaged by surgical treatment. However, it is difficult to remove the existing scar and treat alopecia. Follicular unit extraction technique hair transplantation is a minimally invasive and alternative treatment with a high success and satisfaction rate in the treatment of cicatricial alopecia.

Keywords: cicatricial alopecia, follicular unit extraction, hair follicle unit, hair transplantation, scarring alopecia

1. Introduction

Head and neck, and body have important hair-bearing aesthetic subunits; scalp, eyebrow, eyelash, mustache, beard, axilla, pubis and other body hairs. They are a fundamental component of facial expression, individual's images, religious beliefs, social and psychological health, personality and sexuality [1–3].

Alopecia is a clinical condition characterized by hair loss of hair-bearing aesthetic subunits and is divided into two main categories; scarring (also described as cicatricial) and non-scarring alopecia (**Table 1**) [3–6]. In non-scarring alopecia, the hair follicles remain intact and their regrowth abilities are preserved [3–6]. However, permanent hair loss may occur in the late stages of non-scarring alopecia, called “biphasic alopecia” [7]. Androgenic alopecia is the most common type of non-scarring hair loss that affects nearly half of men. It is characterized by temporal recession and vertex balding in men, diffuse hair thinning and intact frontal hairline in women [4–6, 8].

Alopecia		Scarring alopecia		Non-scarring alopecia	
Primary cicatricial alopecia [North American Hair Research Society (NAHRS) classification]					
Lymphocytic	Neutrophilic	Mixed	Non-specific	Secondary cicatricial alopecia	
<ol style="list-style-type: none"> Lichen plano pilaris (LLP) and variants; <ul style="list-style-type: none"> Classic lichen planopilaris (LPP) Frontal fibrosing alopecia Graham–Little syndrome Chronic cutaneous lupus erythematosus Pseudopelade of Brocq Central centrifugal cicatricial alopecia Alopecia mucinosa Keratosis follicularis spinulosa decalvan 	<ol style="list-style-type: none"> Folliculitis decalvans Dissecting cellulitis 	<ol style="list-style-type: none"> Folliculitis acne keloidalis Folliculitis acne necrotica 3- Erosive pustular dermatosis 	<ol style="list-style-type: none"> End stage of scarring 	<ol style="list-style-type: none"> Granulomatous; <ul style="list-style-type: none"> Sarcoidosis Necrobiosis lipoidica Inflammatory; <ul style="list-style-type: none"> Psoriasis Autoimmune; <ul style="list-style-type: none"> Scleroderma Lichen sclerosus Infections; <ul style="list-style-type: none"> Bacterial Viral Fungal Neoplastic; <ul style="list-style-type: none"> Primary Metastasis Physical agents; <ul style="list-style-type: none"> Trauma Ionising radiation Burn Surgeries Genodermatoses; <ul style="list-style-type: none"> Aplasia cutis congenita Ectodermal dysplasia Epidermolysis bullosa Connective tissue disease; <ul style="list-style-type: none"> Morphea Metabolic; <ul style="list-style-type: none"> Amyloidosis Mucinosis 	<ol style="list-style-type: none"> Androgenic alopecia Telogen effluvium Alopecia areata Trichotillomania Traction alopecia Tinea capitis

Table 1.
The classification of alopecia subgroups.

Cicatricial alopecia presents a heterogeneous group of disorders, which are characterized by destruction and fibrous tissue replacing of the hair follicles, resulting in scarring and permanent hair loss. Cicatricial alopecia is classified into two categories depending on the target of the pathological process; primary cicatricial alopecia (PCA) and secondary cicatricial alopecia (SCA) (**Table 1**). In PCA, the hair follicle is the primary and sole target of a progressive inflammatory process in various skin or systemic diseases [4, 6, 7, 9, 10]. In SCA, non-specific and generalized disruption of the skin and skin appendages results in fibrotic scarring of the skin and permanent loss of hair follicles due to underlying disease or an external agent [3, 6, 7, 10, 11]. If scarring alopecia is small, it is not a significant cosmetic problem; however, if it is large, it negatively affects the quality of life, body image, self-image and self-esteem; causes depression, anxiety, psychological burden, social embarrassment, marital and career-related problems [1–3, 7, 11–19].

2. Epidemiology

The cicatricial alopecia constitutes 3.2–7.3% of the hair loss [7, 10, 20]. The majority of cicatricial alopecia is PCA, and lymphocyte-predominant diseases are the most common subgroup of PCA, and female patients are more affected than men [20]. The most common subtypes of lymphocytic pre-dominant PCA are pseudopelade of Brocq, LPP, discoid lupus erythematosus (DLE) [10, 20]. Although it is mostly seen on the scalp, it can involve other facial and body areas [5].

3. Primary cicatricial alopecia

PCA is characterized by increased inflammation around the ‘bulge’ area of the hair follicle and causes irreversible damage to the epithelial stem cells of the hair follicle. It destroys the remodeling, cycling and regenerative capacity of the hair follicle, and finally causes irreversible hair loss [7, 9, 10].

The NAHRS has classified PCA based on the predominant type of inflammatory cell on hair follicle biopsy; lymphocyte-predominant subgroup, neutrophil-predominant subgroup, mixed subgroup and non-specific subgroup (**Table 1**) [7, 9].

The general characteristics of PCA subgroups are summarized in **Table 2** [4, 6, 7, 9, 10, 21–25].

3.1 Management of primary cicatricial alopecia

Management of PCA is diagnostically and therapeutically challenging due to progression to permanent hair loss. The most important step is informing the patient about the aims of treatment and providing realistic expectations. The successful management of PCA can be achieved with early diagnosis and appropriate treatment to decrease inflammation and progression to scarring alopecia [7, 9]. For this purpose, clinical, histological and laboratory findings should be carefully examined.

3.1.1 Clinical assessment

Patients with PCA may present various distributions of an acute or gradual onset of symptoms. Although some cases are asymptomatic, common symptoms include

	Clinical features	Histopathology	Patient characteristics	Treatment
Lymphocytic cicatricial alopecia				
DLE	Erythematous and scaling plaques, follicular plugging, central hypopigmentation and peripheral hyperpigmentation, telangiectasia and localized on the scalp.	Epidermal atrophy or hyperplasia, early destruction of sebaceous glands, lymphocytic infiltrate at the dermal-epidermal interface, perifollicular scarring.	Middle-aged European woman, systemic lupus erythematosus accompanies in 20% of DLE patients.	Topical and intralesional corticosteroid, hydroxychloroquine, and methotrexate.
LPP	Perifollicular erythematous papules on the vertex and parietal scalp, possible progress to diffuse scarring alopecia, keratotic papules on the trunk and extremities.	Lichenoid band-like perifollicular lymphocytic infiltration, basal vacuolization, Max Joseph spaces along the follicular epithelium.	No age predilection.	Topical, intralesional and oral corticosteroids, hydroxychloroquine, tetracyclines and cyclosporine.
Frontal fibrosing alopecia	Progressive recession of the frontal and temporal hair lines, follicular hyperkeratosis, loss of follicular ostia and eyebrow hair loss about half of the patients.	Lichenoid reaction against miniaturized hair follicles.	Postmenopausal women.	Topical, intralesional and oral corticosteroids, topical minoxidil and oral hydroxychloroquine.
Classic pseudopelade (Brocq)	Rare and slowly progressive cicatricial alopecia, hypopigmentation, atrophic and alopecic plaques resembling “footprints in the snow”.	Perifollicular lymphocytic infiltration, eccentric atrophy of the outer root sheath epithelium, wide fibrous hyalinized tracts, loss of sebaceous glands and follicles.	Middle-aged Caucasian women.	Topical, intralesional and oral corticosteroids, topical minoxidil and oral hydroxychloroquine.
Central centrifugal cicatricial	Tufting, perifollicular hyperpigmentation, progressive scarring alopecia that starts at crown and vertex of scalp and gradually spreads centrifugally.	Premature desquamation of the inner root sheath, perifollicular lymphocytic infiltration and fibroplasia.	Young and middle-aged women of African-American.	Potent topical or intralesional corticosteroids and hydroxychloroquine can be used in the treatment.
Neutrophilic cicatricial alopecia				
Folliculitis decalvans	Multiple hairs emerge from a single follicular orifice, called "tufted hair folliculitis", erythematous follicular papules or pustules on the crown of scalp. <i>Staphylococcus aureus</i> likely triggers the disease.	Follicular plugging, neutrophilic infiltration of the hair follicle, late-stage replacement of hair follicles with fibrous tracts.	Young and middle-aged men.	Tetracycline, doxycycline, erythromycin, and clindamycin; topical or intralesional corticosteroids.

	Clinical features	Histopathology	Patient characteristics	Treatment
Dissecting cellulitis/folliculitis	Painful and fluctuant nodules, abscesses, sinus tracts with purulent discharge on the occiput or vertex of scalp.	Follicular plugging and neutrophils infiltration at the follicular ostia, extensive abscess formation and dermal fibrosis.	Younger men of African Americans.	Topical, intralesional and oral corticosteroids, isotretinoin, antibiotics.
Folliculitis (acne) keloidalis	Follicular erythematous papules and pustules, hairless keloid-like nodules.	Perifollicular neutrophilic and lymphoplasmacytic infiltration, granulomas or micro-abscess formation around hair-shaft.	African postpubertal males.	Topical and intralesional corticosteroids, oral antibiotics, surgical excision.
Folliculitis (acne) necrotica	Red-brown papules and papulopustules result necrosis and depressed scars.	Fragments of hair shaft, follicular epithelium necrosis.	No age predilection.	Topical and intralesional corticosteroids, oral antibiotics, surgical excision.

Table 2.
The general characteristics of PCA.

itching, pain, burning, irritation and discharge on the affected areas. A complete and careful history should include age, ethnic and family origin, nutrition, psychosocial condition, onset and progression of symptoms, medical disorders including autoimmune and inflammatory diseases, infections, malignancies, trauma, burns, radiation, surgeries and hair care practice (hot combs, excess traction, shampoo, drugs, injections) [5, 7, 9].

Careful physical examination of the affected skin with the aid of a magnifying lens or scalp dermoscopy, also defined as “trichoscopy”, in a well-lit environment is essential. PCA is characterized clinically by the lack of visible follicular ostia and the presence of scarring and alopecia. Symptoms of inflammation of the affected area are often indicative of active disease; erythema, scaling, hyperkeratotic plugs, pustules, crusting, scalp boggy, and different colored dots seen by trichoscopy (**Figure 1**). The epidermal atrophy, irregularly spaced hair shafts, multiple hairs tufts and positive pull test of the anagen hair shaft are other findings of physical examination [5, 7, 9, 26].

During clinical examination, taken digital photography and virtual documentation allows high-speed analysis of prognosis and response to treatment, and facilitates archiving. Additionally, it is like evidence in legal problems.

3.1.2 Laboratory tests

Complete blood count (CBC), serum levels of iron, zinc, folate, vitamin B-12, thyroid-stimulating hormone (TSH) and estrogen should be evaluated. The serum levels of total testosterone, free testosterone and dehydroepiandrosterone sulfate are useful for diagnosis and differential diagnosis of androgenetic alopecia.

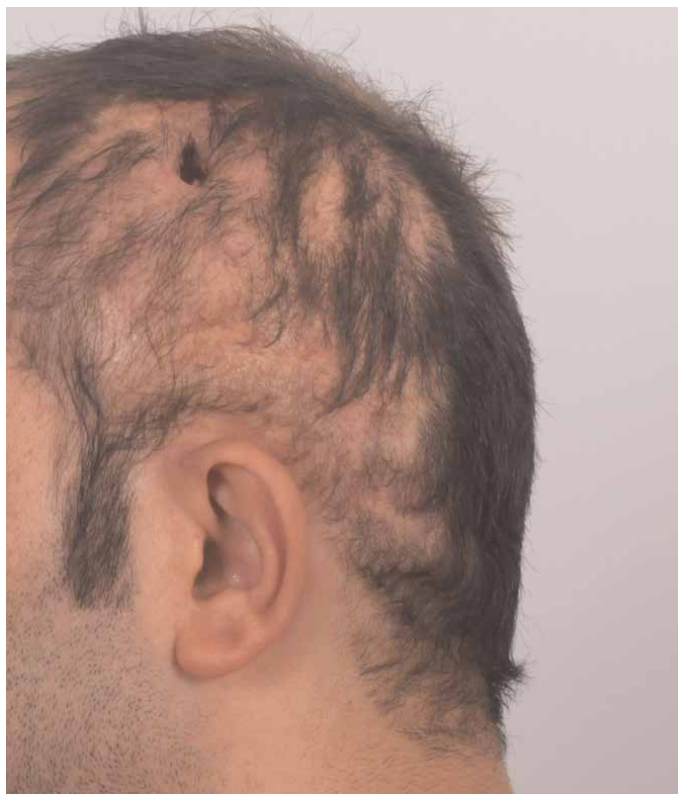

Figure 1. 26-years-old male patient has severe dissecting cellulitis with inflammatory plaques, nodules and discharges purulent material on the scalp.

3.1.3 Histological assessment

A biopsy is always recommended in the assessment of cicatricial alopecia. It can be useful to confirm clinic impression and scarring, identify the underlying pathology and specific type, help guide management and ultimately establishes realistic treatment goals. Samples should be taken using a 4 mm punch biopsy orientated parallel to the angle of the hair shaft growth and deep enough to include the entire HF at the margin of the active disease. Two biopsies are recommended for horizontal and vertical sections. PCA is characterized histopathologically by variable degrees of inflammation of hair follicle epithelium, the replacement of hair follicle structures with scar-like fibrous tissue and hyalinization of surrounding collagen [5–7, 9].

3.2 Treatment

The principal aim of the treatment of PCA is to reduce symptoms and inflammation, slow down and if possible stop the progression of the disease at the earliest phase, and prevent irreversible alopecia [4, 7, 9].

A clear consensus on successful treatments has not yet been achieved in clinical practice. However, immunosuppressants such as potent topical, intralesional and oral

corticosteroids and antimalarials drugs (hydroxychloroquine) are useful for lymphocyte-predominant lesions; antimicrobials (tetracyclines) and dapsone are useful for the neutrophil predominant lesions [4, 7]. Additionally, it is very important to monitor the course and activity of the disease, and response to treatment with regular dermoscopy and clinical examination [26].

Some pharmacological agents such as topical minoxidil and oral finasteride are also used in the treatment. Although controversial and with several side effects including minoxidil-induced telogen effluvium, skin irritation and itching; topical minoxidil can be useful by stimulating vascularity of hair follicles for growth in some patients. Oral finasteride inhibits the enzyme 5-alpha reductase, which is involved in the conversion of testosterone to the more potent dihydrotestosterone, and provides to increase in the ratio of anagen to telogen hairs. However, it can cause erectile dysfunction, decreased libido, impotence and anxiety in men [4, 7, 10, 20].

When severe hair loss occurs, hats, hairpieces and prosthetic wigs may be useful for cosmetic camouflage. The scalp reduction surgeries by primary excisions, local flaps and tissue expansion, and hair transplantation can be used in the surgical treatment of PCA. The stability of PCA is the most important parameter for surgical hair restoration. In the presence of clinically unstable cicatricial alopecia, surgical treatment is not recommended due to the high risk of recurrence of the disease. A 2-year disease-free period is recommended before surgery to minimize the risk of disease recurrence and to increase treatment success [7]. Surgical applications in scarred alopecia are discussed in detail in the section of “secondary cicatricial alopecia”.

3.3 Follow-up

PCA can be reactivated after a quiet of one or more years. Thus, close follow-up is needed for the course of the disease, its severity, response to treatment, treatment-related side effects and the patient’s psychological and social problems with regular dermatoscopic and clinical examination [26].

4. Secunder cicatricial alopecia

SCA develops due to the result of an underlying process or an external agent. The destruction of the hair follicle is not the primary pathological event, generalized disruption of the skin and skin appendages results in scarring and irreversible hair loss [1, 3, 7, 18, 27].

Potential etiological factors are granulomatous and autoimmune diseases, infections, neoplastic processes and physical agents (physical trauma, ionizing radiation, burn, previous surgeries) (**Table 1, Figures 2 and 3**) [1–3, 11, 13–19, 27, 28].

4.1 Management of secunder cicatricial alopecia

The most important step in treatment for SCA is the selection of the right patient and mature scar. The patient’s expectations should be investigated, and the patient should be informed about procedures, complications, and follow-up period [16].

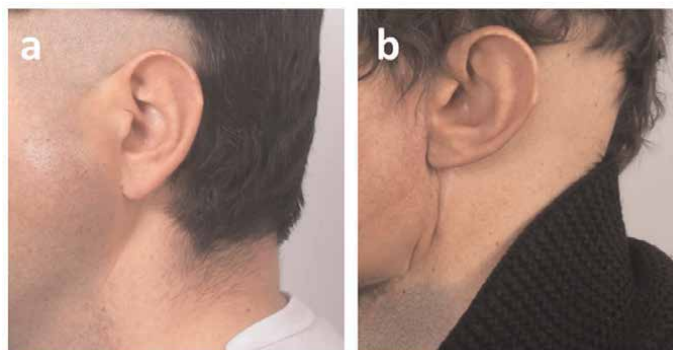

Figure 2.
A 33-years-old male patient presented with malignant head and neck tumor (a). After 1 year of radiotherapy, radiation-induced irreversible scarring alopecia observes on the left face and scalp areas.

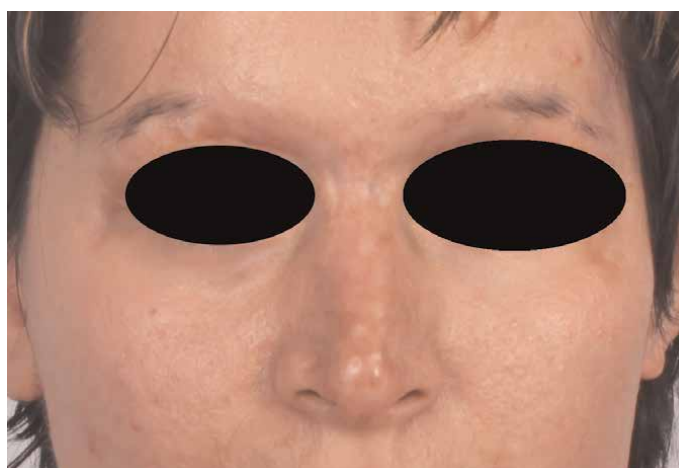

Figure 3.
A 31-years-old female patient presents post-burn scarring alopecia on the bilateral eyebrows.

4.1.1 Clinical and laboratory assessment

The patients should be evaluated for age, sex, etiology, previous medical and surgical treatment, medical conditions with laboratory tests including CBC, blood chemistry panel, coagulation panel, viral serology, localization and dimensions of scarring alopecia, scar characteristics and availability of donor hair for restoration.

Evaluation of scar characteristics is also very important for the management of SCA. The scars should be fully mature that pale, soft, flat, and flexible with sufficient subcutaneous soft tissue and vascular supply [14–16]. If the scar is immature, hypertrophic or excessively atrophic, and located on directly muscle, bone or tendon with not enough subcutaneous tissue, various approaches including preoperative fat grafting, stem cell and laser treatment and combinations could be used to increase the quality, pliability and vascularity of scar tissue [2, 12, 15, 29–32].

4.2 Treatment of seconder cicatricial alopecia

Various medical and surgical procedures have been determined to camouflage and reconstruct scarring alopecia depending on size, location, type of alopecia; laxity, quality, vascular supply of recipient skin and donor hair availability [1–3, 11–14, 16, 28, 29, 33, 34].

4.2.1 Non-surgical camouflage and medical treatment

Prosthetic wigs, tattoo micro-pigmentation, colored spray, dye and make-up can be used for non-surgical camouflage of scalp cicatrice alopecia, but not natural and available for facial scarring alopecia [14, 28, 29, 33].

Some medical management that scar-less ointment, silicone pomade and sheeting, laser treatment, fat injection, *platelet-rich plasma* (PRP) and stem cells can be used for scar treatment and maturity, but alopecia cannot be treated [15, 28–31].

4.2.2 Surgical treatment

Reconstruction of post-burn scarring alopecia is challenging because of permanent hair loss, scar stiffness and poor vascularity, so need to camouflage and removing by surgical procedures [13, 14, 16, 35].

4.2.2.1 Surgical excision

The primary and staged scar excisions are simple methods for correcting small scarring alopecia, but not available for large defects, and scar widening due to secondary tension can be cause relapse [3, 14, 16, 28, 33].

The scar reduction with tissue expansion can be used to avoid relapse and reconstruction of large scarring alopecia. However, increases surgical stage and treatment period, expander-related complications that tissue necrosis, seroma formation, nerve damage and infection; unnatural hair growth direction, facial disfiguring during balloon expansion and a visible scar on expander margins are the main disadvantages [3, 13, 14, 16, 17, 28, 33, 36].

Composite scalp grafts, pedicle and free scalp flap can be used for scarring alopecia, but graft failure in the poor vascular recipient area, increased hair density, unnatural direction of hair, surgery-related scar and complications, microvascular dissection and anastomosis are the main limitations of these techniques [13, 14].

4.2.2.2 Autologous hair transplantation

Otology hair transplantation, that redistributes existing hair follicle units (FUs) to recipient areas, seems to be the most effective technique for scarring alopecia [2, 3, 11–16, 19, 28, 29, 34, 35, 37]. However, poor vascularity and scar stiffness are challenging problem for graft viability [2, 14, 15] and increases post-transplantation complication such as infection, tissue ischemia and necrosis [1, 3, 12, 14–16, 28]. Thus, mechanical and vascular characteristics of scar tissue can be improved by laser, fat injection and stem cell treatments, and combination of them to obtain successful result before hair transplantation [2, 12, 14, 15, 29–32].

Adipose tissue has a volume-increasing effect and includes adipose-derived stem cells (ADSCs) that have a primary role in the regenerative purposes of skin and

subcutaneous tissue by increasing angiogenesis and new collagen deposition [15, 18, 29, 31]. Using autologous fat grafts increase pliability, vascularity and maturity of scar tissues, and fills the loss of volume in depressed scars [2, 12, 14–16, 29–31]. In addition, fat grafts can be prepared rich in stem cells and combined with laser, PRP and other treatments [15, 18, 30].

The FUs can be harvested in ellipse tissue strips from donor areas that follicular unit transplantation (FUT) technique or individually FU with micro-punch that FUE technique. FUT technique has some disadvantages. It causes a permanent scars in donor areas, it is not useful for patients with tight scalp tissue and other body parts (beard, chest, axilla, pubis), it is not available to harvest only single-hair FUs, and it needs more assistance for procedures [3, 14, 16, 19, 35, 37, 38].

FUE is a strategy for graft harvest with different kind's punches with quick healing donor areas without a linear and conspicuous scar [12, 14–16, 29, 34, 35, 37, 38]. It is first-choice method for hair transplants due to the ability to individually choosing of desirable FUs, with minimal spot scarring and no suturing [11, 14, 16, 34].

4.2.2.2.1 Technique detail of FUE hair transplantation

Care should be taken to plan implantation with the correct direction and shaping of hair graft to achieve a good cosmetic result. FUE hair transplantation can be performed under local anesthesia with or without sedation. The number of implantation channels and density of FUs (grafts/cm²) for scar camouflage should be determined by the environment unaffected hair-bearing area or opposite healthy face before surgery.

a) Selection of donor side

Post-auricular and occipital scalp are the most common donor areas for hair transplantations, due to genetically stable and most resistant to hormone-related alopecia [16, 28]. Hair follicles in the scalp grow in groups of one to four hairs, so it is important to choose single-haired follicles for restoration of scarring alopecia on the eyebrows, eyelashes, mustache, beard and hairline of the scalp (**Figure 4**) [35]. Two to more hair-FUs grafts may be used toward the center of the mustache and beard alopecia to improve density but can result in unnatural aesthetic appearances,

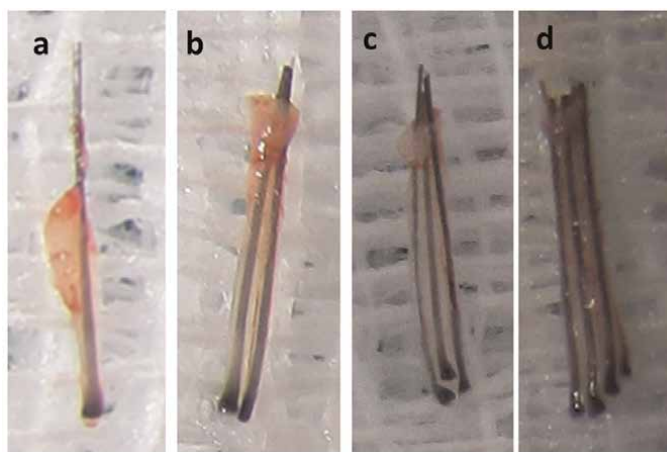


Figure 4. The image shows 1, 2, 3 and 4-hair follicular units on the right to left (a, b, c, d). While each follicular unit has a single hair in hair-bearing aesthetic subunits of the face, it has one to four hairs on the scalp.

especially with a short beard and mustache [16]. Additionally, single-hair FUs have a small size with low metabolic requirements [13, 19], thus, it is also a good option for graft viability in scarring alopecia.

The submandibular beards are the best donor areas with the natural caliber and density for mustache, beard and side-burn scarring alopecia, which have similar hair characteristics. The availability of submandibular beard hair is sometimes a limiting factor, but FUE offers the advantage of harvesting different body hair such as the occipital and post-auricular scalp, suprapubic and other body [2, 14, 16, 37]. However, heterotopic hair transplantation can cause different regrowth duration and physiological cycle, color change by aging, and different calibration and density due to different anatomic and physiological characteristics [14, 28].

b) Anesthesia and harvesting hair follicles

The donor's hairs are cut to 2–3 mm lengths before procedures. With the patient in the supine position, on the operating table, donor and recipient sites are anesthetized by infraorbital, supraorbital, supratrochlear, mental, cervical, post-auricular or occipital nerve block. Then donor area infiltration anesthesia is performed by the tumescent solution that a mixture of 0.9% saline, 2% lidocaine, and 1:1000 epinephrine. Tumescent with low concentration or without epinephrine is injected in the recipient area, to avoid decreased subdermal blood supply due to vasoconstriction [14, 15, 19, 28, 34].

The FUs are harvested from the donor area individually by using handled or low rotational speed electronic micro-motor powered 4–5 mm-length and 0.6–1.2 mm-diameter circular micro-punch to avoid transection of follicles. Single-hair FUs are selected from the occipital and post-auricular scalp for restoration of scalp hairline and facial hair. The micro forceps are used to apply gentle pressure on the skin around the FUs graft, elevating it lightly to allow the top part of the graft to be grasped. The extracted FUs are handled gently and kept moist in sterile petri-dish with 0.9% saline or special solutions at 4°C until transplantation [14–16, 28, 34].

c) Implanting hair follicles

Single channels are opened for each graft and FUs are synchronously implanted into the pre-made channel by using micro forceps. Channeling in fibrotic scar area is performed by using 0.75–1.2 mm width and 4–5 mm length classic micro blade or sapphire blade to make incisions perpendicular parallel to the growth direction of existing hair with similar density of opposite side or environment of scarring alopecia [11, 14, 15, 19, 34].

Attention must be paid for making true channeling and hair transplantation with surrounding facial hair without neurovascular injuries.

d) Discharge

Oral antibiotics and analgesics are administered for 5 postoperative days. Recipient and donor areas left open without occlusive dressing, with daily antibiotic ointment and washing with hair lotion or shampoo after the third postoperative day. Patients should be followed for at least 12 months. Folliscope examination is useful to evaluate the condition and density of transplanted FU [3, 15]. After transplantation, PRP injection can be used to improve graft viability [18].

4.2.2.2.2 *Post transplantation complications*

The most important complications of cicatricial alopecias include graft failure, infection, tissue ischemia and necrosis after surgery because of additional vascular injury during close and deep channel opening and graft implantations [14].

4.2.2.2.3 Survival rate and density of transplanted follicle units

The most important determining factor of surgery success is the survival rate of transplanted FUs in scarring alopecia. The survival rate of transplanted FUs grafts is over 90% in healthy vascularized areas [16, 19], but there is confusion about various survival rates (0–90%) for scarring alopecia [14].

In the scarring alopecia, Shao et al. [3] obtained a mean of 78.96% (ranged from 64.29 to 95.00) surviving FU density. Meyer-Gonzalez and Bisanga [37] considered more than 80% graft survival successful. Yoo et al. [1] obtained a mean 80.67% (ranged from 70% to 90%) survival rate with significant satisfaction. In the literature, an average 80% or over of graft viability has been accepted as success in scarring alopecia [1, 19, 37].

Low graft viability is a challenging problem due to poorly vascularized and fibrotic recipient areas [1, 2, 12, 14, 16, 28]. Various treatment methods are used to increase scar vascularity and maturity before hair transplantation. Akdag et al. [2] transferred fat grafts and FUs to scarring alopecia after cleft lip surgery at 3 months intervals, and an average of 82% (73.6–88.6) graft viability was obtained. Agaoglu et al. [15] combined non-ablative fractional laser and cryopreserved microfat grafting multistage before hair transplantation, and obtained a mean of 85.04% (76–95) graft viability. Podda et al. [32] performed cold-ablative Er:YAG Laser-Assisted hair transplantation and obtain apparent 95% graft survival. Autologous fat grafting, includes adipose-derived regenerative cells that have a primary role in the regenerative purposes by secreting a number of growth factors, increasing local neovascularization, collagen and elastin synthesis, and improving texture, thickness, pliability and angiogenesis of scar tissues [2, 15, 29, 30, 39].

During the treatment of scarring alopecia, one of the most difficult decisions is to determine the density of FUs. Because low blood supply is limited to high-density transplantation in scarring alopecia. While average follicle density for normal scalp alopecia is accepted over 30–35 FU grafts per cm^2 [1, 16], but there was no consensus about scarring alopecia.

Barr and Barrera [16] recommended 20–30 FUs/ cm^2 scarring alopecia according to scar characteristics. Unger et al. [28] recommended a transplantation density of 30 FU/ cm^2 or less to prevent the development of postoperative complications; 15–20 FU/ cm^2 for scarring alopecia with poor blood supply; 20–30 FU/ cm^2 for scarring alopecia with better perfusion. Wang et al obtained 30–34 grafts/ cm^2 graft density and averaged 97% graft survival (range 87–100%) in scarring alopecia at 1-year follow-up. Civas et al. transplanted about 24.9 FU/ cm^2 in scarring alopecia with 86.7% satisfactory result of the patient. As a general rule, there is a decrease in graft survival when the graft frequency exceeds 30 FU/ cm^2 in scarring alopecia areas. While small and mature scars can be transplanted in a close to normal number (30 FUs/ cm^2) since nutrition will be good; however, low-density transplantation and if required staged transplantation is recommended for large and problematic scars [16, 28].

4.2.2.3 Staged hair transplantation

After hair transplant in scarring alopecia, normal perfusion and oxygenation during the ischemia-reperfusion period and re-vascularization of hair follicle grafts mainly affect graft viability. If transplanted grafts are not re-vascularized within a few days after surgery, the graft will go failure [15, 16]. Additionally, the number of transplanted FUs determines the rate of graft survival. If too many grafts are transplanted in a small area, they compete for reduced blood flow through the scar

tissue and low blood flow cannot meet grafts' nutrition. Assuming that there is acceptable blood perfusion, it is recommended that this number does not exceed 30 grafts/cm² when performing a hair transplant in scarring alopecia. For this reason, it is better to perform multistage hair transplantation than running the risk of complications [16].

4.2.2.4 Advantages of FUE technique hair transplantation

FUE technique hair transplantation is the safe, effective and repeatable method in cicatricial alopecia including several advantages; provides a large amount of individual FUs harvesting on donor area with minimally invasive, less pain, less discomfort, less-complication method, high FUs graft survival rate, small implantation hole without formation of a linear scar and neurovascular damage, well accepted by patients with natural-looking hair growth and high level of satisfactory results. Additionally, transplantation of hair FUs to cicatricial alopecia carries epidermis, dermis, hair follicle, skin appendages that sebaceous and sweat glands, neurovascular bundles, piloerectile muscles, surrounded by a sheath of collagen and hair follicle stem cells increases the quality of the scar. FUE has led to improved graft survival and better cosmetics. Moreover, FUE needs less manpower, less equipment and minimal graft preparation period. All patients can be treated at an out-patient clinic with short hospitalization and a faster recovery period without general anesthesia (**Figure 5**) [16, 19, 28, 29, 34, 35, 37].

4.2.2.5 Disadvantages of FUE technique hair transplantation

FUE technique hair transplantation is time-consuming procedure and needs to technique skills. Because it is difficult to keep the punch parallel to the follicles to avoid transactions that result inflammation, cyst formation and inability to harvest all the hair from the mid portion of the donor area [35]. Multistage procedures need to obtain satisfactory hair density in poor vascular scars. Wide donor area and spot scar formation on the punched-out sites are other limitations [1, 14, 28, 35].

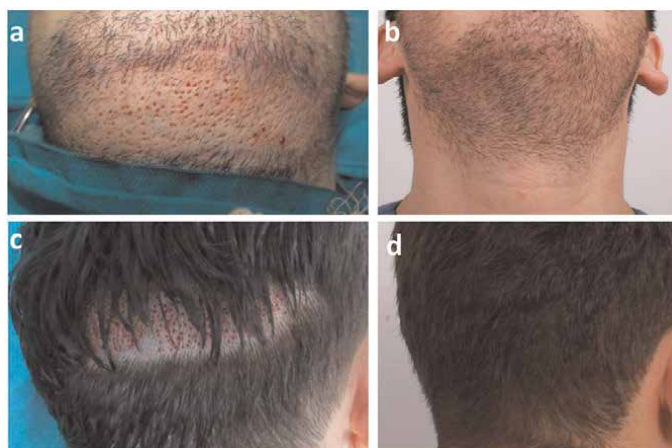

Figure 5.
The intra-operative images of the submandibular (a) and scalp (c) donor areas of follicular unit extraction (FUE) technique hair transplantation. After 1 week of hair transplantation, submandibular (b) and scalp (d) donor areas heal uneventfully.

4.2.2.6 Scalp restoration

The scalp is the most common area of scarring alopecia with its large surface. Several well-established treatment modalities have been used for the reconstruction of scarring alopecia on the scalp, including primary excision, local flaps, tissue expander and hair transplantation. The defects affected 50% of the scalp can be reconstructed by aesthetically and homogeny redistributing of remaining scalp tissue with excellent cosmetic density [16, 17, 33, 36]. It is very important to determine the hairline and exit angle of FUs during scalp hair transplantation. The anterior hairline should reconstruct approximately 8 cm above the glabella in males, approximately 5.5 cm in a female by using single hair FUs. Two or more hair FUs can be used for central scarring alopecia to increase density [16].

4.2.2.7 Beard and mustache restoration

Beards and mustaches are important hair-bearing aesthetic subunits for hirsute men. Especially male patients who underwent cleft lip surgery suffer from bilateral philtrum scars and prolabial alopecia. Hair transplantation is the best treatment option for scarring alopecia on the beard and mustache. The submandibular beard is the best match donor area for beard and mustache (**Figures 6 and 7**). The single-hair FUs from the scalp can be used for beard and mustache restoration in beard-less man [2].

4.2.2.8 Eyebrow restoration

Hair loss in the eyebrow causes de-humanization of the appearance (**Figure 3**). Modern makeup and micropigmentation techniques provide a 3-dimensional eyebrow appearance close to normal [14]. The exit angle and growth direction of the transplanted hair should be determined for the aesthetically pleasing result, that the medial hairs are oriented vertically, followed by the upper marginal hairs angled down and the lower marginal hair angled up. The donor hair can be taken from the opposite eyebrow, single-hair occipital and post-auricular scalp and nasal vibrissae [16].

4.2.2.9 Eyelash restoration

The eyelash restoration can be performed by retrograde or anterograde techniques with the single-hair occipital and post-auricular scalp. In the retrograde technique, hair FUs are implanted in the lid margin with classical techniques [19]. In the anterograde technique, the distal end of long hair is pulled out by a curved needle at the lid margin and provides better control of the growth direction of the hair [14, 16].

4.3 Future

It is a well-established fact that scarring alopecia has lower graft survival rates as compared to non-scarring alopecia. Tissue engineering studies need to develop scar-less wound healing and increase scar maturation similar to normal tissue.

Perhaps in the near future, alopecia will be treated routinely by in-vitro culturing of hair FUs [2, 14]. However, nowadays otology redistribution of existing hair FUs is the most commonly performed treatment for scarring alopecia [16].

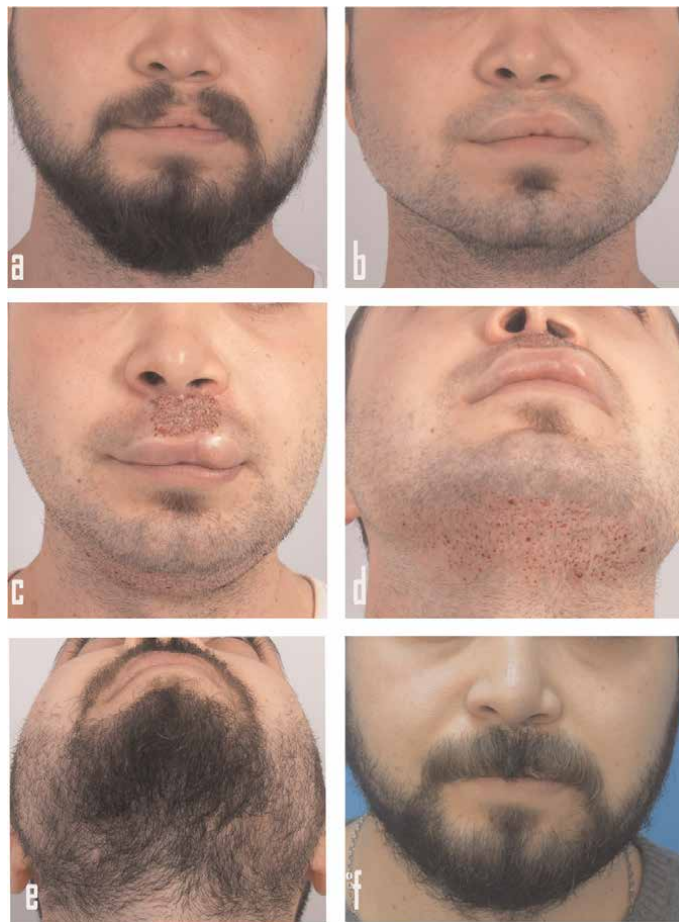

Figure 6. A 22-years-old male patient had serious scarring alopecia after cleft lip surgery (a, unshaved image; b, shaved image). The patient underwent single-stage FUE hair transplantation from the submandibular area (c, d). After 3 years of hair transplantation, lip scarring alopecia has been successfully camouflaged (e, f).

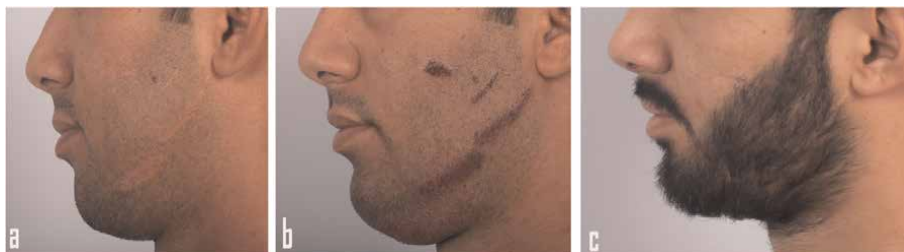

Figure 7. A 27-years-old male patient had multiple scarring alopecia on the face after trauma (a). The patient underwent single-stage FUE hair transplantation from the submandibular area (b). After 24 months of hair transplantation, scarring alopecia has been successfully camouflaged (c).

5. Conclusions

Cicatricial alopecia forms a group of disorders that destroys hair follicles and replaced them by fibrous tissue. Treatment of cicatricial alopecia is challenging because of permanent hair loss. However, in primary scarring alopecia, early diagnosis and treatment can limit or even prevent the progression of hair loss. In contrast to classical techniques including scar excision, local flaps, and tissue expansion, follicular unit hair transplantation offers an innovative and effective treatment option for stable primary scarring alopecia and mature secondary scarring alopecia with several advantages; safe, minimally invasive and aesthetically pleasing results, even after a single session.

Author details


Nuh Evin^{1*} and Seyda Guray Evin^{2*}

1 Faculty of Medicine, Department of Plastic, Reconstructive, and Aesthetic Surgery, Bezmialem Vakif University, Istanbul, Turkey

2 Department of Plastic, Reconstructive, and Aesthetic Surgery, Göztepe Training and Research Hospital, Istanbul, Turkey

*Address all correspondence to: nuhevin@gmail.com and sydguray@gmail.com

IntechOpen

© 2022 The Author(s). Licensee IntechOpen. This chapter is distributed under the terms of the Creative Commons Attribution License (<http://creativecommons.org/licenses/by/3.0>), which permits unrestricted use, distribution, and reproduction in any medium, provided the original work is properly cited. 

References

- [1] Yoo H, Moh J, Park JU. Treatment of postsurgical scalp scar deformity using follicular unit hair transplantation. *BioMed Research International*. 2019; **2019**:3423657
- [2] Akdag O, Evin N, Karamese M, et al. Camouflaging cleft lip scar using follicular unit extraction hair transplantation combined with autologous fat grafting. *Plastic and Reconstructive Surgery*. 2018; **141**: 148-151
- [3] Shao H, Hang H, Yunyun J, et al. Follicular unit transplantation for the treatment of secondary cicatricial alopecia. *Plastic Surgery (Oakville, Ont)*. 2014; **22**:249-253
- [4] Cardoso CO, Tolentino S, Gratieri T, et al. Topical treatment for scarring and non-scarring alopecia: an overview of the current evidence. *Clinical, Cosmetic and Investigational Dermatology*. 2021; **14**: 485-499
- [5] Mubki T, Rudnicka L, Olszewska M, et al. Evaluation and diagnosis of the hair loss patient: part I. History and clinical examination. *Journal of the American Academy of Dermatology*. 2014; **71**:415. e411-415. e415
- [6] Stefanato CM. Histopathology of alopecia: a clinicopathological approach to diagnosis. *Histopathology*. 2010; **56**: 24-38
- [7] Rongioletti F, Christana K. Cicatricial (scarring) alopecias: an overview of pathogenesis, classification, diagnosis, and treatment. *American Journal of Clinical Dermatology*. 2012; **13**:247-260
- [8] Manabe M, Tsuboi R, Itami S, et al. Guidelines for the diagnosis and treatment of male-pattern and female-pattern hair loss, 2017 version. *The Journal of Dermatology*. 2018; **45**: 1031-1043
- [9] Sundberg JP, Hordinsky MK, Bergfeld W, et al. Cicatricial Alopecia Research Foundation meeting, May 2016: progress towards the diagnosis, treatment and cure of primary cicatricial alopecias. *Experimental Dermatology*. 2018; **27**:302-310
- [10] Whiting DA. Cicatricial alopecia: clinico-pathological findings and treatment. *Clinics in Dermatology*. 2001; **19**:211-225
- [11] Martinez D, Sodr e JL, Regis JR, et al. Hair transplantation in uncommon secondary cicatricial alopecias. *Dermatologic Therapy*. 2022; **35**(8):e15592
- [12] Kwon OS, Kim MH, Park SH, et al. Staged hair transplantation in cicatricial alopecia after carbon dioxide laser-assisted scar tissue remodeling. *Archives of dermatology*. 2007; **143**:457-460
- [13] Barrera A. The use of micrografts and minigrafts for the treatment of burn alopecia. *Plastic and Reconstructive Surgery*. 1999; **103**:581-584
- [14] Farjo B, Farjo N, Williams G. Hair transplantation in burn scar alopecia. *Scars, Burns & Healing*. 2015; **1**: 2059513115607764
- [15] Agaoglu G,  zer F, Karademir S, et al. Hair transplantation in burn scar alopecia after combined non-ablative fractional laser and microfat graft treatment. *Aesthetic Surgery Journal*. 2021; **41**:Np1382- np1390
- [16] Barr L, Barrera A. Use of hair grafting in scar camouflage. *Facial*

- Plastic Surgery Clinics of North America. 2011;**19**:559-568
- [17] Jiang W, Chen L, Jia L, et al. Corrective strategies for poor appearance after tissue expansion for temporal and sideburn cicatricial alopecia. *Journal of Cosmetic Dermatology*. 2021;**20**:4001-4004
- [18] Evin N, Tosun Z, Aktan TM, et al. Effects of adipose-derived stem cells and platelet-rich plasma for prevention of alopecia and other skin complications of radiotherapy. *Annals of Plastic Surgery*. 2021;**86**:588-597
- [19] Barrera A. The use of micrografts and minigrafts in the aesthetic reconstruction of the face and scalp. *Plastic and Reconstructive Surgery*. 2003;**112**:883-890
- [20] Tan E, Martinka M, Ball N, et al. Primary cicatricial alopecias: clinicopathology of 112 cases. *Journal of the American Academy of Dermatology*. 2004;**50**:25-32
- [21] Cummins DM, Chaudhry IH, Harries M. Scarring Alopecias: Pathology and an Update on Digital Developments. *Biomedicines*. 2021;**9**(12):1755
- [22] Imhof RL, Cantwell HM, Proffer SL, et al. The spectrum of pediatric scarring alopecia: a retrospective review of 27 patients seen at Mayo Clinic. *Pediatric Dermatology*. 2021;**38**:580-584
- [23] Villablanca S, Fischer C, García-García SC, et al. Primary scarring alopecia: clinical-pathological review of 72 cases and review of the literature. *Skin Appendage Disorders*. 2017;**3**:132-143
- [24] Harries MJ, Paus R. The pathogenesis of primary cicatricial alopecias. *The American Journal of Pathology*. 2010;**177**:2152-2162
- [25] Porriño-Bustamante ML, Fernández-Pugnaire MA, Arias-Santiago S. Frontal fibrosing alopecia: A review. *Journal of Clinical Medicine*. 2021;**10**
- [26] Mubki T, Rudnicka L, Olszewska M, et al. Evaluation and diagnosis of the hair loss patient: part II. Trichoscopic and laboratory evaluations. *Journal of the American Academy of Dermatology*. 2014;**71**:431.e431-431.e411
- [27] Severs GA, Griffin T, Werner-Wasik M. Cicatricial alopecia secondary to radiation therapy: case report and review of the literature. *Cutis*. 2008;**81**:147-153
- [28] Unger W, Unger R, Wesley C. The surgical treatment of cicatricial alopecia. *Dermatologic Therapy*. 2008;**21**:295-311
- [29] Tesauro P, Trivisonno A, Gennai A, et al. Hair transplantation in cicatricial alopecia: the role of autologous fat transfer. *International Journal of Regenerative Medicine*. 2020:1-11
- [30] Onur Erol O, Agaoglu G, Jawad MA. Combined non-ablative laser and microfat grafting for burn scar treatment. *Aesthetic Surgery Journal*. 2019;**39**:Np55-np67
- [31] Klinger M, Klinger F, Caviggioli F, et al. Fat grafting for treatment of facial scars. *Clinics in Plastic Surgery*. 2020;**47**:131-138
- [32] Podda M, Spieth K, Kaufmann R. Er: YAG laser-assisted hair transplantation in cicatricial alopecia. *Dermatologic Surgery*. 2000;**26**:1010-1014
- [33] Leedy JE, Janis JE, Rohrich RJ. Reconstruction of acquired scalp defects: an algorithmic approach. *Plastic and Reconstructive Surgery*. 2005;**116**:54e-72e
- [34] Civas E, Aksoy H, Aksoy B, et al. Clinical experience with hair

transplantation for secondary cicatricial alopecias. 2019;**27**:160-166

[35] Rassman WR, Bernstein RM, McClellan R, et al. Follicular unit extraction: minimally invasive surgery for hair transplantation. *Dermatologic Surgery*. 2002;**28**:720-728

[36] Guzey S, Alhan D, Şahin I, et al. Our experiences on the reconstruction of lateral scalp burn alopecia with tissue expanders. *Burns*. 2015;**41**:631-637

[37] Meyer-Gonzalez T, Bisanga C. Body-hair transplant for cicatricial alopecia. *Actas dermo-sifiliograficas*. 2012;**103**:163-164

[38] Umar S. Use of beard hair as a donor source to camouflage the linear scars of follicular unit hair transplant. *Journal of Plastic, Reconstructive & Aesthetic Surgery*. 2012;**65**:1279-1280

[39] Klinger M, Marazzi M, Vigo D, et al. Fat injection for cases of severe burn outcomes: a new perspective of scar remodeling and reduction. *Aesthetic Plastic Surgery*. 2020;**44**:1278-1282

Section 4

Other Treatments

Overview of the Role of 308 Monochromatic Excimer Phototherapy for the Treatment of Alopecia Areata

Nabeel K. Al Hamzawi and Mohammed S. Al Baaj

Abstract

Treatment of alopecia areata (AA) remains challenging despite the advancement in all these years. Excimer phototherapy has been claimed to offer a practical alternative therapeutic option without significant risks. It is considered a “super-narrowband” UVB light source that emits energy at 308 nm. Excimer laser treatment achieves a remarkable effect in T cell-mediated disorders; thus, it has been used successfully in patients with AA. Compared with narrowband UVB, the excimer laser can induce apoptosis *in vitro*, paralleled by improved clinical efficacy. Both excimer laser and lamp have a similar effect, but they differ in technology. In this chapter, an evaluation of the effectiveness of 308 nm monochromatic excimer phototherapy in AA treatment is clinically warranted. The evidence-based studies that adopted this option using both laser and light are discussed. In addition, the formulation of therapeutic protocol to study the outcome of excimer treatment on moderate-to-severe AA in adults and children is described.

Keywords: alopecia areata, update treatment, 308 monochromatic excimer, targeted phototherapy, evidence-based studies

1. Introduction

Alopecia areata (AA) may cause significant cosmetic and psychological distress in affected persons due to the unpredictable course of the disease. The management of patients with AA is challenging, with no definite cure established. Corticosteroids have been the mainstay treatment used *via* topical, systemic, or intralesional routes. Other various treatment options have been tried, including systemic immunosuppressants such as methotrexate, azathioprine, and sulfasalazine and contact sensitizers such as dinitrochlorobenzene (DNCP), diphenylprone (DPCB), and squaric acid dibutyl ester (SADBE) [1, 2].

Phototherapies including psoralen plus ultraviolet (PUVA), UVA-1, and narrowband UVB (NB-UVB) were used to treat AA with some success rates. However, the disadvantage of these modalities is the exposure of a large area of normal skin to

irradiation along with the alopecia area, making the increment of irradiation dose limited. Despite that, this method could be an effective alternative for patients who are resistant to systemic and topical therapy. Topical PUVA or phototoxic PUVA consists of a solution containing 8-methoxypsoralen that was administered to the affected areas of the scalp around 20 minutes before exposure to ultraviolet radiation. The dose was based on the patient's skin phototype [3]. UVA-1 (340–400 nm) was superior to narrowband-UVB (NB-UVB; 311 nm), as it can penetrate the deep layer of the skin where the hair follicle is situated.

Recently, 308 excimer laser/light therapy has been used for treating AA with the significant results and fewer adverse reactions. This technology has the ability to induce apoptosis of affected T-cells. The advantages of excimer therapy include a lower cumulative UV dose involved, a shorter time of treatment, and the option of targeting individual lesions without affecting the surrounding healthy skin [4]. It is now considered a good option in treating different immune-mediated skin diseases. Moreover, excimer can be emitted as coherent (laser) or non-coherent light, both seem compelling, with the cost-effectiveness ratio more favorable to light.

2. What is excimer?

Excimer, also known as “excited dimer,” is a class of diatomic molecules composed of atoms that are electronically excited and associated with the second atom in its ground (thermally unstable) state. The molecular ground state is unbound or weakly bound (by van der Waals forces). This means that a population inversion can be established automatically when the excited state occurs. Excimer lasers are capable of producing powerful and efficient broadband emissions at various spectral regions throughout the ultraviolet region. The most common types of excimer laser are the rare gas halides, which exhibit high power, average power, and single pulse energy. These include ArF, KrF, XeCl, and XeF. The last two types of excimers with weak ground states exhibit the most structured spectrums of overlapping remission transitions [5].

Formerly, excited dimers were represented only by homonuclear diatomic molecules with a steady excited state but repulsive ground states. Subsequently, excimer was extended to include any polyatomic molecule with a repulsive or weakly bound ground state—excimer molecule with heteronuclear dimer known as “exciplex” or exciting complex. For instance, Xe₂^{*} is an excimer molecule, while XeCl^{*} and KrCl^{*} are exciplex molecules.

The new ultraviolet B ray source, exciplex “xenon chloride lamp,” emits monochromatic 308 nm light representing the natural evolution of the excimer laser (**Table 1**). The monochromatic excimer light (MEL) produces 50 mW/cm² power density at a distance of 15 cm from the source and has a maximum irradiating area of 504 cm² [6].

2.1 Historical aspect

The excimer laser was proposed in 1960 by Fritz Houtermans. Incidentally, in 1967, Mester et al. noted that using low-level laser therapy (LLLT) to treat cancer in mice with shaved backs could induce hair regrowth [7]. Later, the use of noble gas halides (originally Xe Br and then Xe Cl) was developed by many groups in 1975. These groups include the Avco Everett Research Laboratory and Sandia Laboratories [8, 9].

Variables	Excimer laser	Excimer lamp
Wavelength	308 monochromatic	304–308 monochromatic
Coherence	yes	non-coherent
Spot size	small	Large
Erythema	Less pronounce	More pronounce
Treatment cost	More expensive	Favorable cost

Table 1.
 Comparison between excimer light and excimer lamp.

It was used for the first time in medical applications in 1997 when Bónis *et al.* tested its effect on psoriasis [10]. The study reported that excimer lasers might allow targeted, rapid phototherapy superior to conventional UV phototherapy with incoherent light. In 2001, Baltas *et al.* reported using the excimer laser to treat vitiligo [11]. Several studies have investigated the efficacy of 308 excimer on various dermatological disorders such as atopic eczema, mycoses fungoides, and AA [12–17]. All AA (single, multiple, and totalis) were identified and treated in those studies. Various protocols regarding the initial dose, increment dose, number of sessions per week, and complete course of treatment were applied.

2.2 Mechanism of action of 308 excimer in alopecia areata

AA is a T-cell-mediated autoimmune disease. It was believed that the immune system attacks the hair in the anagen phase, which leads to a rapid transition to catagen and telogen, resulting in hair loss. This process is triggered by the activation of the JAK/STAT cytokines, including IL-15 and interferon-gamma pathways [18].

The significant character of the hair follicle lies in its relative immune privilege, established by the suppression of surface molecules needed for presenting autoantigens to CD⁺ T lymphocytes and by the generation of an inhibitory local signaling environment. AA has been thought to develop due to cell death of protein 1 ligand (PD-L1), which leads to the collapse of immune privilege in the hair follicle [19].

Several triggers have been suggested to induce AA, including infection, drugs, trauma, and stress. Others such as autoimmune thyroid disease, atopy, and vitiligo are commonly associated. Psychological and physical insults may trigger the episodes of AA, but there is no evidence that they influence prognosis.

The high-dose monochromatic UV radiation of 308 excimer phototherapy can induce immunological suppression by altering cytokine production such as IL-4, IL-10, prostaglandin E₂, platelet-activating factor, cis-urocanic acid, and trigger apoptosis. A study that used an excimer laser to treat AA in mice evaluated the number of perifollicular CD4⁺ and CD8⁺ in the treated patches before and after 12 weeks [20]. Results showed a significant decrease in the perifollicular infiltration of CD4⁺ and CD8⁺ with gross hair regrowth in the treated area.

It was suggested that the laser's effect on the activity and maintenance of T-cells could be mediated by the exertion of soluble mediators. The short wavelength of the excimer laser cannot penetrate human hair follicles, which means that the soluble mediators could potentially be utilized in inhibiting the activation of autoimmune reactions [20].

3. Evidence-based studies

Analysis of the biomedical literature database, PubMed, using the terms “excimer” and “alopecia areata” revealed that 16 of 38 studies analyzed were clinical trials, and five of these were control trials. Some of these studied protocols are given in **Table 2**. Of the control trials, one included 16 participants with 99 patches of AA [21]. The author of this study concluded that the excimer laser was safe and effective in AA. However, its effect on hair regrowth might be delayed compared with intral-lesional corticosteroids.

In 2004, Gundogan C et al. successfully treated two patients whose AA had progressively worsened for 3 and 14 weeks. They had used a 308 nm xenon chloride excimer laser (dosage: 300–2300 mJ/cm² per session). The entire affected area showed homogenous and thick hair regrowth after 11 and 12 sessions within a 9-week and 11-week period. Relapse was not reported during the 5 and 18 months [22].

Christian Raulin et al. reported that hair regrowth was achieved with the 308 nm xenon chloride excimer laser for AA of the scalp in a prospective side-by-side trial. One representative lesion was chosen; one-half of it was treated, and the other half remained untreated. Only the treated area showed hair growth; after 27 sessions over 3 months (200–4000 mJ/cm², a cumulative dose of 52.6 J/cm²), this was probably not a spontaneous remission [23].

A study published by Zakaria et al. tested nine patients with AA using a 308 nm excimer laser, started with 50 mJ/cm² less than the minimal erythema dose. Then, doses were increased from 50 mJ/cm² every two sessions. The treated lesion was irradiated twice a week for 24 sessions. Each lesion had an opposite side untreated target lesion serving as a control. The results of the study revealed that the 308 nm excimer laser can stimulate hair growth in all patients with partial AA. This proves the effectiveness of laser treatment and excludes the possibility of spontaneous hair

Author	Patient No.	Type of AA	Successful rate	Treatment protocol
Zakaria <i>et al.</i> , [14]	<i>n</i> = 9	Single, AT, AU	55.6	Twice/ week/24 session
Chao-Chun Yang <i>et al.</i> , [15]	<i>n</i> = 17	AA, AT, AU	29.4	2–3 times/ week/14–118 sessions
Alhamzawi [17]	<i>n</i> = 18	MAA	55.5	Twice/week/24 sessions
Al-Mutairi, [24]	<i>n</i> = 18	MAA, one AT	41.5	Twice/ week/24 session
Ohtsuki <i>et al.</i> , [25]	<i>n</i> = 16	Single, multiple	62.5	Once/2 weeks/8–40 sessions
Byun JW <i>et al.</i> , [26]	<i>n</i> = 10	Multiple AA	75	12 weeks/ Twice/ week
Arakawa Y. <i>et al.</i> , [27]	<i>n</i> = 11	AU	36.3	2-week interval/16 weeks

AA—Alopecia areata, AU—Alopecia universalis, AT—Alopecia totalis.

Table 2.

Various studies have used 308 excimer laser/light in the treatment of alopecia areata.

regrowth. No relapse was noted in those patients who lost their hair over a follow-up period of 3 months. Moreover, no hair regrowth was observed in patients with either AA universalis (AAU) or AA totalis (AAT) [14].

In 2007, Al-Mutairi investigated the effect of the 308 nm excimer laser in the treatment of patchy AA. Eighteen patients, seven males and eleven females, with 42 recalcitrant patches (including one adult with AAT) were enrolled. The lesions were irradiated with the 308 nm excimer laser twice a week for 12 weeks. On each patient, one lesion was left as a control for comparison. New hair regrowth was observed in 17 (41.5%) patches, with 13 of the 18 lesions on the scalp showing a complete regrowth of hair. Lesions on the extremities failed to show a response. Atopic diathesis had an unfavorable effect on the outcome of treated patients. The author concluded that the 308 nm excimer laser is an effective therapeutic option for patchy AA of the scalp and some cases of patchy AA of the beard area. In contrast, it does not work for patchy AA of the extremities [24].

Ohtsuki et al. conducted a study to evaluate the effects of the 308 nm excimer lamp on three patients with single AA resistant to conventional therapy. They gave each of the three subjects the laser at two-weekly sessions. After 10 sessions, the hair growth rate in all three patients had returned to normal [25].

In a study conducted by Byun JW et al., 10 patients with AA were investigated, and the alopecic patch was divided into control and treated sides. The excimer laser was administered twice a week for 12 weeks. A therapeutic effect on AA was achieved, proven by photographs and phototrichogram [26].

In a clinical study of 11 patients with AAU conducted by Arakawa Y. et al., participants were treated with a 308 nm excimer light at 2-week intervals for more than 16 sessions. Four patients achieved good responses, and two patients exhibited poor responses. The authors concluded that the 308 nm excimer light therapy significantly affects some AAU patients resistant to other treatments and may be an alternative therapeutic option for AAU. The study suggested that the administration of a high radiation dose is required to achieve a strong inflammatory skin reaction [27].

In a prospective study, Alhamzawi evaluated the efficacy and safety of a 308 nm monochromatic excimer lamp in treating 18 patients with multiple AA. The treatment protocol consisted of two sessions per week for 12 weeks. The excimer safety was evaluated by objectively recording adverse reactions and patient satisfaction. Follow-up continued for 6 months after treatment to assess the level of recurrence. The results significantly affected resistant cases of multiple AA with considerable safety and tolerability (**Figure 1**) [17].

Fenniche S. et al. evaluated the efficacy and safety of combining topical khellin (a furanochromone photosensitizer whose chemical structure is close to that of psoralens) and 308 nm excimer light in the treatment of a refractory ophiasis, of 1-year evolution, in a 5-year-old boy. The trial showed complete hair regrowth with no recurrence one year later [28].

A controlled study by Li A., Meng X., et al. used a 308 nm excimer lamp with minoxidil in 38 patients with AA. Each alopecia lesion was divided into the control and treated sides. Topical minoxidil (2% solution) was used on both sides, with a 308 nm excimer lamp only added on the treated side. The primary objective of the study was to compare the number of hair growth on the treated and control sides. The results indicated that the number of hair growth on the treated side was significantly greater than that on the control side [29].

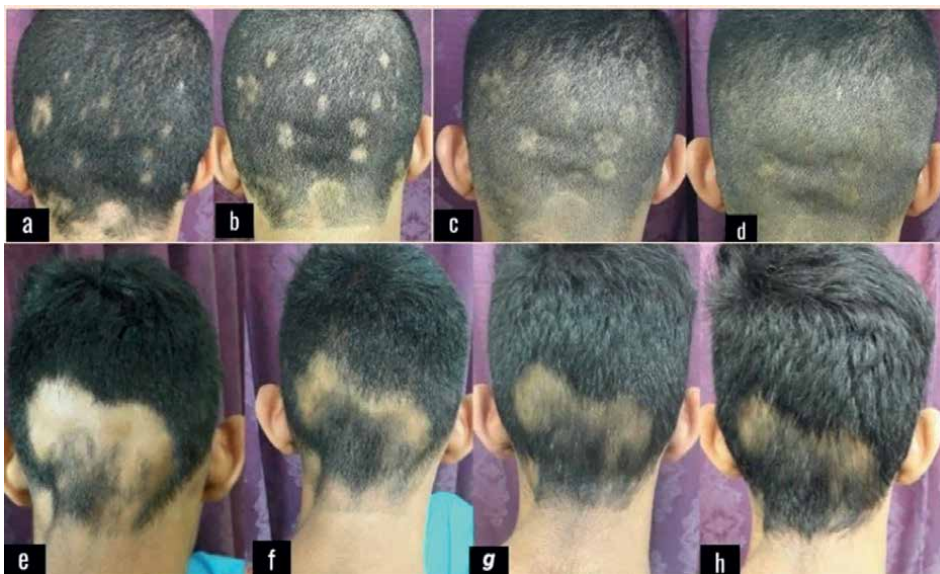

Figure 1. Two patients with alopecia areata successively treated by 308 excimer lamp, a & e baseline, b & f 4 weeks after treatment, d & h 12 weeks after treatment.

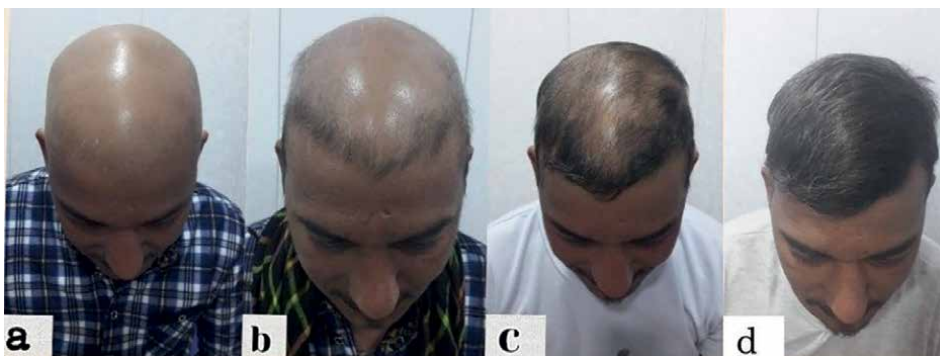

Figure 2. Alopecia totalis treated by combined therapy of twice weekly 308 excimer light with monthly intramuscular triamcinolone acetonide.

Alhamzawi Nabeel K. tested the effect of combining 308 excimer phototherapy with IM triamcinolone acetonide on 10 patients with alopecia totalis. All patients received monthly IM triamcinolone acetonide (TAC) for six pulses and twice-weekly excimer phototherapy for 24 sessions. Four patients (40%) achieved complete regrowth of hair (100% regrowth), and three patients exhibited a satisfactory response (>70% regrowth). Two patients reported an unsatisfactory response (>10 to <70% regrowth). The study showed that younger patients responded better, as did those with a shorter history of the disease (**Figure 2**) [30].

Notably, the combination treatment of 308 excimer with systemic therapy is superior to excimer monotherapy, especially for resistant AA cases [30].

4. Targeted phototherapy

Also called focused phototherapy, it involves the emission of ultraviolet radiation directly at skin lesions through special delivery mechanisms. Targeted phototherapy includes laser and nonlaser technologies.

Excimer lamp is a targeted phototherapy that delivers a specific wavelength of 308 nm of UVB radiation to localized areas of skin lesions. Compared to NB-UVB, targeted phototherapy is more effective and safe. Unlike other laser devices, its templates are compatible with the contours of the target area, which means that they do not expose the normal skin to radiation. The effects of the laser can be delivered with a low cumulative dose and a shorter treatment duration, which are ideal for patients looking for a quick and effective solution. The spot size of the excimer lamp is wider than that of the excimer laser, which helps speed up the treatment of large areas of hair loss within a short time [31, 32].

4.1 Advantages of targeted phototherapy

1. Delivers high doses of energy within a short treatment session
2. Easy to handle and allows efficient treatment of difficult areas such as the scalp, nose, genitals, oral mucosa, and ears
3. Treats only the involved areas, sparing uninvolved regions, thus minimizing unwanted side effects of phototherapy such as erythema and long-term risk of skin cancer
4. Easily administered to children who are intimidated by large phototherapy machines
5. Occupies less space than conventional phototherapy machines
6. Short treatment sessions

4.2 Disadvantages of targeted phototherapy

1. Not recommended for lesions over 10% of the body area.
2. Time consuming for treatment of extensive areas.

4.3 Indications of targeted phototherapy

Localized psoriasis
Localized vitiligo
Mycosis fungoides
Atopic dermatitis
Alopecia areata
Localized morphea
Urticaria pigmentosa

4.4 Contraindications

Photosensitive disorders
Xeroderma pigmentosa
SLE
History of malignant melanoma

4.5 Side effects of excimer light treatment

The treatment aims to induce visible erythema in the treated lesion (supra-erythematous dose) but not cause a blister or second-degree burn. Too high a dose can lead to blister formation. Side effects may include painful erythema, desquamation, erosion, and reactivation of herpes infection.

Although long-term exposure to ultraviolet radiation ultimately causes skin aging and skin cancer, the risk of excimer light therapy is suggested to be less than that of narrowband UVB.

4.6 FDA devices of targeted phototherapy

Excimer laser machines, which are approved by the FDA, have been introduced by companies such as Alcon (Wave Light®, USA) and PhotoMedex. (XTRAC®; USA). The disadvantages of these equipment include their heavy weight, high cost, and difficult maintenance.

The FDA-approved nonlaser-targeted phototherapy includes Excilite® (DEKA, Florence Italy; 304 nm), Pxlite (308 nm), and Exciplex (Excimer Therapies; 308 nm). These machines are less bulky and cheaper and have a comparatively larger treatment surface than that of the excimer laser.

The nonlaser machines are considerably smaller than the laser machines, with fewer maintenance problems, and are cheaper. They have multiple delivery programs and automatic calibration for quick delivery of dosages so that the treatment time is short. Some of these machines have UVA (330–380 nm) and UVB (narrowband; 290–330 nm) spectra [32–34].

5. Treatment protocol

Despite the absence of a universally proven protocol that sustains prolonged remission, many therapeutic regimens for using excimer are available, which can benefit both children and adults with AA. Although the two types (laser and lamp) have similar effects, the difference between them is their technology. An excimer lamp is less expensive than an excimer laser, and it has a more prominent spot size that delivers a high dose of UV radiation to the selected treatment area. Wide spot size helps in treating a larger area in a short time. Any treatment options are frequently based on several parameters, including:

1. Age of the patient
2. Disease duration
3. Disease activity

4. Extension
5. Location
6. Analysis of dermoscopy features and scalp biopsy focused on the hair cycle and degree of inflammation
7. Patient expectations
8. Risk/benefit factors
9. Cost of therapy in terms of time and financial resources
10. Presence of other comorbidities such as low iron stores, thyroid abnormalities, low vitamin D, or other autoimmune diseases
11. Whether the patient has previously received treatment?

Before starting the treatment with monochromatic excimer light, you must calculate the minimal erythematous dose on healthy, unexposed skin. The volar aspect of the forearm is commonly used to determine the starting dose (usually 0.5–0.7 MED).

1. To identify MED, the tested areas irradiated with multiple doses (usually 50 mJ/cm², 100 mJ/cm², and 150 mJ/cm² etc, up to 300 mJ/cm², using different templates and wait for the result after 24 hours.
2. Carry out the treatments with one or two sessions per week until clinical response occurs. Calculate the delivered amount of UV taking into account the skin type, site, age, and response to treatment. In most cases, clinical improvements will be evident after a few treatment sessions. Mild side effects such as fair erythema may be observed (in at least 50% of patients) after the first and second applications. Other adverse reactions such as mild swelling, pruritic sensation, and hyperpigmentation may be noted in the treated areas but can be resolved spontaneously at two weeks post-treatment.
3. The starting dose is 50 mJ/cm² less than the identified MED, then increments are scheduled with 50 mJ/cm² every week. The dose is increased until the appearance of fine or asymptomatic erythema. If the erythema fades in less than 48 h, the treatment will remain fixed, and if it persists longer than 48 h, the dose will be reduced by 50 mJ. If the condition worsens, the treatment should be postponed until the next visit.
4. Irradiate the treat patches of AA twice weekly.
5. Continue the treatment for 12 weeks (24 sessions). If no response is noted after eight sessions, stop the treatment.
6. Avoid repeating the irradiation on the same treated area.
7. Use a template proportional to the size of the alopecia patch to avoid affecting the healthy skin.
8. Evaluate the therapeutic effect.

In evaluating AA treatments, clinicians require valid, clinically meaningful outcome measures.

In 2004, the SALT (Severity of Alopecia Tool) score emerged as a key milestone in the AA field, providing a standardized method to derive 0–100% of the scalp-hair loss. Building on this achievement, the AA-IGA (Alopecia Areata Investigator Global Assessment) provides an ordinal, static measure with five distinct clinical gradations of SALT score (“None” = 0, “Limited” = 1, “Moderate” = 2, “Severe” = 3, and “Complete” = 4). AA-IGA is a meaningful clinician-reported measure of scalp-hair loss, reflecting patients’ and expert clinicians’ perspectives and treatment expectations [35]. Assessment of hair regrowth is based on the change in the SALT score or AA-IGA.

The percentage of hair that grew back after laser treatment was assessed using a six-grade scale. The first grade was A0, where no change was detected in the number of hair (poor). The second grade was A1, with 1–25% regrowth (mild), and the third grade was A2, which was equal to 25–49% (moderate). The fourth grade was A3, with 50–74% regrowth (good), and the fifth was grade A4, with 75–99% regrowth (very good). The sixth grade was A5, with 100% regrowth (excellent).

Absolute change in SALT score = SALT score at baseline – SALT score after treatment. Percent scalp hair regrowth is based on SALT score = $(100 \times [\text{baseline SALT score} - \text{SALT score after treatment}]) / \text{baseline SALT score}$.

The results indicated that hair growth in more than 50% of the area was regarded as a successful response, while that with less than 50% range was considered to be an inadequate response. The poor response was evaluated when the SALT equaled zero. The overall response rate was the percentage of patients who responded positively to the treatment [17].

Evaluation is carried out at four points (baseline, 4 weeks, 8 weeks, and 12 weeks). The SALT score was recorded from the baseline to the last visit and digital photographs were taken at the same points.

The efficacy of the equipment was evaluated by the objective recording of adverse reactions and patient satisfaction. Follow-up continued for 6 months to 1 year after treatment to assess the level of recurrence. Excimer can be used as a monotherapy or combined with another treatment. The additive treatment can be topical, such as corticosteroid or calcineurin inhibitors, and it can be in the form of systemic therapy, such as methylprednisolone or triamcinolone acetonide.

6. Who can benefit from excimer therapy?

Studies have shown that excimer is safe and can be used for everyone. Here are the necessary specifications for candidates.

- Excimer can be used for patients with contraindications to systemic or topical therapy.
- For those with resistance or those who are not suitable for other procedures
- Disease duration: compared to those with long-term lesions, patients with a disease duration of >1 up to 4 years respond better to this procedure.

- Extension of the disease: patchy alopecia (single or multiple) responds faster than AU and AT.
- For patients with no associated comorbidities or other autoimmune diseases [3, 4, 14–17].

7. Conclusion

308 excimer phototherapy is an existing technology in treating AA. It is safe, effective, and easily administered even in difficult areas. The duration of treatment is shorter than that of whole-body phototherapy. A complete response may take 20–30 sessions, with some responses noted as early as 6–8 sessions.

Calculating the UV dose should be monitored considering the skin type, age, lesion site, and treatment response.

Learning points

- 308 nm excimer light is a targeted phototherapy that delivers a specific wavelength (308 nm) of UVB radiation.
- It is available in the form of a coherent excimer laser and non-coherent excimer lamp.
- It requires a short treatment course than conventional UVB phototherapy.
- It is well tolerated by children.
- Different templates are used to protect the surrounding unaffected skin.
- It can deliver a high dose of radiation with a reduced cumulative amount.
- It can use equipment in areas that are difficult to reach with UVB phototherapies, such as genitals and ears

Conflict of interest


None.

Author details

Nabeel K. Al Hamzawi* and Mohammed S. Al Baaj
Department of Dermatology, Diwanayah Teaching Hospital, Diwanayah, Iraq

*Address all correspondence to: alhamzawi_n@yahoo.com

IntechOpen

© 2022 The Author(s). Licensee IntechOpen. This chapter is distributed under the terms of the Creative Commons Attribution License (<http://creativecommons.org/licenses/by/3.0>), which permits unrestricted use, distribution, and reproduction in any medium, provided the original work is properly cited. 

References

- [1] Gupta AK, Carviel J, Abramovits W. Treating alopecia areata: Current practices versus new directions. *American Journal of Clinical Dermatology*. 2017;**18**:67-75
- [2] Alkhalifah A. Alopecia areata update. *Dermatologic Clinics*. 2013;**31**:93-108
- [3] Welsh O. Phototherapy for alopecia areata. *Clinics in Dermatology*. 2016;**5**:628-632
- [4] Abrouk M, Levin E, Brodsky M, et al. Excimer laser for the treatment of psoriasis: Safety, efficacy, and patient acceptability. *Psoriasis (Auckl)*. 2016;**6**:165-173
- [5] Duarte FJ, editor. *Tunable Lasers Handbook*. New York: Academic; 1995
- [6] Mavilia L, Mori M, Rossi R, Campolmi P, Puglisi Guerra A, Lotti T. 308 nm monochromatic excimer light in dermatology: Personal experience and review of the literature. *Giornale Italiano di Dermatologia e Venereologia*. 2008;**143**(5):329-337
- [7] Mester E, Szende B, Gartner P. The effect of laser beams on the growth of hair in mice. *Radiobiologia, Radiotherapia*. 1968;**9**(5):621-626
- [8] Ewing JJ, Brau CA. Laser action on the $2\text{Sigma}^+ 1/2 \rightarrow 2\text{Sigma}^+ 1/2$ bands of KrF and XeCl. *Applied Physics Letters*. 1975;**27**(6):350-352
- [9] Tisone GC, Hays AK, Hoffman JM. 100 MW, 248.4 nm, KrF laser excited by an electron beam. *Optics Communication*. 1975;**15**(2):188-189
- [10] Bónis B, Kemény L, Dobozy A, Bor Z, Szabó G, Ignácz F, et al. 308 nm UVB excimer laser for psoriasis. *Lancet*. 1997;**350**:1522
- [11] Baltás E, Csoma Z, Ignácz F, Dobozy A, Kemény L. Treatment of vitiligo with the 308-nm xenon chloride excimer laser. *Archives of Dermatology*. 2002;**138**(12):1619-1620. DOI: 10.1001/archderm.138.12.1613
- [12] Baltás E, Csoma Z, Bodai L, Ignácz F, Dobozy A, Kemény L. Treatment of atopic dermatitis with the xenon chloride excimer laser. *Journal of the European Academy of Dermatology and Venereology*. 2006;**20**:657-660
- [13] Passeron T, Zakaria W, Ostovari N, Perrin C, Larrouy JC, Lacour JP, et al. Efficacy of the 308-nm excimer laser in the treatment of mycosis fungoides. *Archives of Dermatology*. 2004;**140**:1291-1293
- [14] Zakaria W, Passeron T, Ostovari N, Lacour JP, Ortonne JP. 308-nm excimer laser therapy in alopecia areata. *Journal of the American Academy of Dermatology*. 2004;**51**:837-838
- [15] Hsu TC, Lin TK, Hsu CK, Jou HJ, Yang CC. Excimer lamp as an effective alternative treatment for severe alopecia areata. *Dermatologica Sinica*. 2015;**33**:151-153
- [16] Ohtsuki A, Hasegawa T, Komiyama E, Takagi A, Kawasaki J, Ikeda S. 308-nm excimer lamp for the treatment of alopecia areata: Clinical trial on 16 cases. *Indian Journal of Dermatology*. 2013;**58**:326
- [17] Hamzawi A, Nabeel K. Evaluation of the efficacy and safety of 308-nm monochromatic excimer lamp in the treatment of resistant alopecia areata. *International journal of trichology*. 2019;**11**(5):199-206
- [18] Anzai A, Wang EHC, Lee EY, Aoki V, Christiano AM. Pathomechanisms of

- immune-mediated alopecia. *International Immunology*. 2019;**31**(7):439-447
- [19] Paus R, Bulfone-Paus S, Bertolini M. Hair follicle immune privilege: The key to alopecia areata management. *The Journal of Investigative Dermatology. Symposium Proceedings*. 2018;**19**:S12-S17
- [20] Moon JH, Bang CY, Kang MJ, et al. Therapeutic effect of 308-nm excimer laser on alopecia areata in an animal model. *Annals of Dermatology*. 2019;**31**(4):463-466
- [21] Kainfar N, Dasdar S, Mahmoudi H, Abedini R, Fahim S, Hosseini SA, Daneshpazhooch M. Comparison of the efficacy and safety of 308-nm excimer laser with intralesional corticosteroids for the treatment of alopecia areata: A randomized controlled study. *Lasers in Surgery and Medicine*. Apr 2022;**54**(4):502-510
- [22] Gundogan C, Greve B, Raulin C. Treatment of alopecia areata with the 308-nm xenon chloride excimer laser: Case report of two successful treatments with the excimer laser. *Lasers in Surgery and Medicine*. 2004;**34**(2):86-90. DOI: 10.1002/lsm.20002
- [23] Raulin C, Gündogan C, Greve B, Gebert S. Die Excimer-Laser-Therapie der Alopecia areata--Halbseitige Evaluation eines repräsentativen Areals [Excimer laser therapy of alopecia areata--side-by-side evaluation of a representative area]. *Journal der Deutschen Dermatologischen Gesellschaft*. 2005;**3**(7):524-526
- [24] Al-Mutairi N. 308-nm excimer laser for the treatment of alopecia areata. *Dermatologic Surgery*. 2007;**33**(12):1483-1487
- [25] Ohtsuki A, Hasegawa T, Ikeda S. Treatment of alopecia areata with 308-nm excimer lamp. *The Journal of Dermatology*. 2010;**37**(12):1032-1035
- [26] Byun JW, Moon JH, Bang CY, Shin J, Choi GS. Effectiveness of 308-nm excimer laser therapy in treating alopecia areata, determined by examining the treated sides of selected alopecic patches. *Dermatology*. 2015;**231**:70-76
- [27] Arakawa Y, Nomiyama T, Katoh N. Three hundred and eight nanometer excimer light therapy for alopecia universalis that is resistant to other treatments: A clinical study of 11 patients. *The Journal of Dermatology*. 2016;**43**(12):1412-1416
- [28] Fenniche S, Hammami H, Zaouak A. Association of khellin and 308-nm excimer lamp in the treatment of severe alopecia areata in a child. *Journal of Cosmetic and Laser Therapy*. 2018;**20**(3):156-158
- [29] Li A, Meng X, Xing X, Tan H, Liu J, Li C. Efficacy and influence factors of 308-nm excimer lamp with minoxidil in the treatment of alopecia areata. *Lasers in Surgery and Medicine*. 2020;**52**(8):761-767
- [30] Alhamzawi NK. Combining 308-monochromatic excimer phototherapy with monthly IM triamcinolone acetone for the treatment of resistant alopecia totalis. *American Journal of Dermatological Research and Reviews*. 2021;**4**:37
- [31] Lopes C, Trevisani VF, Melnik T. Efficacy and safety of 308-nm monochromatic excimer lamp versus other phototherapy devices for vitiligo: A systematic review with Meta-analysis. *American Journal of Clinical Dermatology*. 2016;**17**(1):23-32
- [32] Hamzavi I, Lui H. Using light in dermatology: An update on lasers, ultraviolet phototherapy, and photodynamic therapy. *Dermatologic Clinics*. 2005;**23**:199-207

[33] Lapolla W, Yentzer BA, Bagel J, Christian R, et al. A review of phototherapy protocols for psoriasis treatment. *Journal of the American Academy of Dermatology*. 2011;**64**(5):936

[34] York NR, Jacobe HT. UVA1 phototherapy: A review of mechanism and therapeutic application. *International Journal of Dermatology*. 2010;**49**(6):623-630

[35] Wyrwich KW, Kitchen H, Knight S, et al. The alopecia areata investigator global assessment scale: A measure for evaluating clinically meaningful success in clinical trials. *The British Journal of Dermatology*. 2020;**183**(4):702-709



Section 5

Psychological Management
of Alopecia



Psychological Aspect of Alopecia

Dogancan Sonmez and Cicek Hocaoglu

Abstract

Hair is one of the most important components of the individual's appearance and self-perception, as an organ that has an important role in social and sexual communication in humans. Therefore, hair loss can have negative effects on self-confidence, body image and self-esteem. Trichopsychodermatology is a special field of psychodermatology that deals with the psychosocial causes and consequences of hair loss and hair diseases. Alopecia patients suffer from various mental disorders, especially anxiety and depression. Psychological stress and emotional difficulties act as triggers and accelerators in both trichotillomania, which is within the scope of primary psychiatric diseases, and hair diseases with different etiopathogenesis such as alopecia areata, telogen effluvium, cicatricial alopecia, androgenetic alopecia, anagen alopecia. Providing psychiatric diagnosis and treatment in a patient presenting with alopecia may also have a positive effect on the course of alopecia. In this section, the psychiatric approach to patients with alopecia is discussed. This situation, which is frequently observed by dermatologists in clinical practice, has actually been little studied in the literature.

Keywords: alopecia, hair disorders, psychodermatology, psychotrichology, psychiatric management, psychiatric symptoms

1. Introduction

Hair is not only a beauty, but a mirror of health and youth, and also has a cultural, sociological and psychological significance. It was seen as a symbol of power and handsomeness in men, and a tool for beauty and attractiveness in women. Therefore, especially in diseases with hair loss, psychosocial effects such as significant self-image deterioration and loss of self-esteem occur. Hair diseases are one of the challenging areas of dermatology [1]. Especially in cases with chronic hair loss, the psychosocial problems experienced by the patients in the personal, social and professional areas are also added to the difficulties in treatment and complicates the patient management for the dermatologist. Although it is thought that there will be similar psychosocial difficulties in all hair loss, different degrees and serious results may occur in different hair diseases [2]. The stress and embarrassment experienced by patients with hair disease should not be ignored and should be taken into account when creating a treatment plan. Although hair loss is generally seen as a non-threatening cosmetic problem, its psychological effect can reach serious dimensions. In many cultures, hair is associated with one's self or community identity. Hair is considered an indicator of beauty and health. This situation, which is frequently observed by

dermatologists in clinical practice, has actually been little studied in the literature. Trichopsychodermatology is a special and new field of psychodermatology that deals with the relationship between stress and hair loss and the negative psychosocial consequences of hair loss. It focuses on the development of coping strategies and the application of necessary psychotherapeutic and pharmacological treatments [1].

2. General features in psychodermatology

Psychosomatic theory has an important place in elucidating the relationship between the skin and the spiritual phenomena that create the personality of the human being. The relationship between the skin and the soul is tried to be explained with a few links. First of all, the epidermis has the same embryological origin as the nervous system. It separates man from the outside world; It is a person's showcase to the outside world. With these features, leather has a very special place in our individual existence. The skin is an important erogenous zone, and touch, heat and pain are also sources of erogenous pleasure. It is also the source of erotic rewards such as the mother's touch and caress from infancy. If the urge to use the skin in the usual way is suppressed, repetitive tendencies that stimulate and oppose the skin can find an expression on the body through changes in the skin. It can also be a source of anxiety as it involuntarily transmits some of our emotional states such as shame and anger. In addition, the skin is the organ of expression of emotions and the outlet of anxiety [3]. According to psychosomatic theory; Any conflict situation that creates anxiety and injury on the basis of the integrity of the person can turn into a mental or physical illness based on this. As Cazzullo points out on the topic of skin diseases, "a superficialization mechanism from a conflict situation" is ignited. Similarly, Cormia stated that people with psychodermatological diseases could not cope with the difficult situations in their lives and that the use of autonomous mechanisms as a result of the tension and stress created by this strain could lead to skin diseases [4]. While explaining psychosomatic diseases, psychoanalysts did not only mention conflicts, but also included other factors such as personality and life events in their explanations. According to Dunbar and Alexander, there are specific personality traits for each psychosomatic disorder. In line with this idea, they created "personality profiles" and tried to establish a connection between these personality profiles and physical ailments. Alexander emphasizes the importance of the combined effect of conflicts and life events on the development of the disease. According to him, people whose defenses are weakened by the presence of unresolved psychological conflict experience discomfort in their weakest body parts in the face of certain life events [5]. The skin is the focus of stress-reducing behaviors due to its easy accessibility and its primary role in early bonding. Since the skin is the most prominent organ, skin lesions seen in people with low psychological insight and prone to somatization may be the only way to express emotional disturbances [6]. Herman Musaph, an Amsterdam-born psychiatrist, is considered one of the founders of psychodermatology. Musaph became head of the department of psychodermatology at the University of Amsterdam in 1953. Musaph's knowledge and experience in psychoanalysis enabled him to examine and understand the role of psycho-emotional factors in skin patients in more detail and led to the emergence of studies especially on psoriasis, artifact dermatitis and pruritus. One of the best and comprehensive examples on this subject was "Itching and scratching, Psychodynamics in Dermatology" published in 1964. The European Society of Psychiatry and Dermatology was established in Vienna in

1993 [7]. Didier Anzieu, on the other hand, focused on the relationship between self psychology and the skin in his book “Skin-Ego” published in 1985, emphasizing the experiences of body contact and the functions of the skin in the early stages of the development of the child’s self [8]. The first attempts to classify psychodermatological diseases were made by Caroline Koblenzer, a dermatologist and psychoanalyst, in 1982 [9]. One of the widely accepted classifications today is the classifications proposed by Koo and Lee and the other by Harth et al. [10].

When evaluated from a neurobiological point of view, it is known that psychological and physical stress triggers the emergence of various skin and hair disorders. Hair cortisol analysis, which has been used in recent years, has been accepted as an effective method in evaluating disorders in the hypothalamus-pituitary-adrenal axis [11]. Hair cortisol concentrations vary according to both emotional and physical stress. Hair cortisol concentration has proven to be more reliable than blood, saliva, and urine cortisol measurements [12]. Since this technique shows chronic stress, which is the trigger of various skin and hair changes, hair cortisol measurements may be useful for future research [1]. Emotional stress can accelerate alopecia by causing local inflammation with the activation of type 2b corticotropin-releasing hormone receptors that are overexpressed around the hair follicle [13]. It has been reported that substance P is released from nerves in response to stress, and the same has been noted in hair follicles [14]. Similar neurobiological mechanisms are also detected in stress-induced psychiatric disorders such as major depressive disorder, generalized anxiety disorder and phobias, and they also occur comorbidly in patients with alopecia [15].

3. Psychosomatic scalp diseases

3.1 Alopecia areata

Alopecia areata is one of the common causes of hair loss. The lifetime incidence is 2.1% [16]. It has been shown that genetic, autoimmune and environmental factors may play a role in the etiology, but the cause is not known yet. It has been suggested that alopecia areata can be considered among the psychosomatic diseases triggered by stressful life events [17]. Alopecia areata, one of the non-scarring hair loss, is a common inflammatory hair disease and is clinically characterized by asymptomatic, ovarian-round hair loss areas. It is polygenetic and multifactorial and its etiopathogenesis is not clearly understood. Although not life-threatening, psychiatric outcomes are common in alopecia areata, especially in total and universal types where loss is severe. It is extremely important to detect possible emotional problems accompanying the disease. Because pharmacological treatments are ineffective, especially in severe forms, and psychotherapeutic approaches are needed [18, 19]. In a recent study, the association with psychiatric diseases was investigated and it was found that depression, anxiety and sleep disorders often accompanied the disease. In addition, it has been determined that both alopecia areata and psychiatric disorders mutually affect each other and lead to disease progression. The sense of identity is severely damaged, especially in women, and feelings of grief and pain emerge [19]. While sexual identity is damaged in women, social identity is damaged by loss of trust more in men. In addition, marital problems and occupational problems are pointed out in women with alopecia areata [20, 21]. It has been emphasized that stressful events increase with age and eventually lead to stress-related psychological disorders such as anxiety and OCD.

There are views that major depressive disorder (MDD) and alopecia areata share a common pathogenesis [22]. However, it is also suggested that there is a bidirectional relationship between the two diseases. According to these views, alopecia areata may initiate MDD or alopecia areata may be the result of MDD. On the other hand, depression and anxiety emerge as a risk as hair loss creates a negative self-image. There is a high risk of self-harming behaviors and suicide [23, 24]. Socialization problems, increased aggression, fear of ridicule and avoidance of friendships with peers in school-age children were noted [25]. The experiences of patients with Alopecia Areata are complex and highly personal. With the unpredictability of hair loss, life restrictions, cycles of hope and despair are seen. Interestingly, the presence of negative emotions and psychological stress is not parallel to the severity of the disease. Patients with mild Alopecia Areata are just as affected as those with severe hair loss. Although patients receiving psychotherapy have a different experience, positive results provide coping, acceptance and greater personal growth [26]. Although rarer, alexithymia, adjustment disorders, developmental disorders, and substance use-related disorders have been reported with Alopecia Areata. There are also some reports of attention deficit-hyperactivity [24, 27, 28].

3.2 Androgenetic alopecia

Androgenetic alopecia (AGA) is also known as male pattern hair loss. Genetic and hormonal factors are effective in development. It is most often seen in middle-aged white men. About 30% of men are affected by age 30, 50% by age 50, and 80% by age 70 [29]. One of the important topics in the discussion of hair loss has been the effects of hair loss on body image and social acceptability. In fact, various results have been obtained in studies on the psychological effects of androgenic alopecia, which is seen by many men as a part of the natural aging process. In a study conducted several decades ago by Cash, men stated that androgenic alopecia impairs body image and causes stress without significant loss in psychological functioning [30]. Although androgenetic alopecia can be seen by many men as a part of the natural aging process, it has been shown that especially young and single men are adversely affected by alopecia [30]. In a study investigating the effects of androgenetic alopecia on male psychology, men evaluated alopecia or hair loss as an event that disrupted their body image or caused stress. Men with alopecia stated that they were not completely satisfied with their appearance, they actually preferred to have more hair, and some of them questioned their social acceptability due to alopecia and they had to expend more energy to cope. As the severity of alopecia increases, these symptoms also increase [31]. It is reported that androgenetic alopecia, which usually starts in the early 20s, causes the person to compare himself with his peers and decreases his self-esteem over time. Such people can become obsessed with androgenetic alopecia and spend a lot of time and money on the treatment of alopecia [32, 33].

It has been shown that women with androgenic alopecia are affected more negatively than men psychologically. Psychological stress is usually more severe in women [34]. Hair is one of the most important components of physical appearance in women. One study compared 96 female and 60 male patients with androgenic alopecia and reported that 52% of women and 28% of men were extremely unhappy with androgenic alopecia. When female patients with androgenic alopecia were compared with female patients with another dermatological disease, it was found that the androgenic alopecia group was more stressed, experienced more social anxiety, and had lower self-esteem [35]. Studies investigating anxiety, depression and personality traits

associated with androgenetic alopecia in women have been conducted. It is especially seen in women with polycystic ovary syndrome (PCOS). In a study of 254 women with PCOS, androgenetic alopecia was detected in 56 women, and it was determined that these patients were more anxious about hair loss, but Beck depression scores were not higher than other PCOS patients [36]. The presence of psychiatric disorders in androgenic alopecia is actually an expected situation. In the treatment of comorbid conditions, an intervention for the etiology should be considered first, and hormonal regulation should be aimed first. In addition, necessary treatment should be arranged after psychiatric evaluation in symptomatic cases.

3.3 Telogen effluvium

Losses caused by disorders in the development cycle of the hair are called telogen effluvium (TE) or anagen effluvium (AE) according to the stage in which the hair is affected. Causes of TE include high fever, thyroid disorders, surgeries, accidents, some medications, postpartum period, severe emotional stress, heavy diets, eating disorders, vitamin and mineral deficiencies. Hair loss rate in TE cases is generally milder than AE and this rate is usually below 50% [37]. Acute or chronic stress can cause TE to develop, while TE itself can cause secondary stress. As a result, a vicious cycle can occur. Although it is a common condition, there are limited studies in the literature on the psychosocial effects of TE [38]. Indeed, a recent study showed a more than 400% increase in the incidence of TE after a few months in populations heavily affected by COVID-19 [39]. In patients with telogen effluvium, the negative emotions created by the loss and experienced by the patient take place on a wide scale. A wide variety of emotions can be experienced, such as shame, anger, humiliation, disgust, fear, sadness, anxiety, depression, frustration, body image damage, inadequacy and lack of confidence, feeling older and unhappy with their appearance, helplessness, social stress, and even fear [40].

3.4 Anagen effluvium/chemotherapy induced alopecia

Hair loss in the anagen phase, which is the growth phase of the hair, is called anagen effluvium. Unlike TE, intense loss is observed rapidly. It is also called chemotherapy alopecia because it often occurs after chemotherapy treatment [41]. Chemotherapy-induced alopecia (CIA) has various psychosocial effects that adversely affect quality of life such as anxiety, depression, low self-esteem and low self-image. Even the idea of patients developing alopecia after being diagnosed with cancer can cause severe fear and anxiety for patients. It has been shown that CIA is among the three main negative effects of the chemotherapy-induced distressing process, and the distressing process caused by alopecia is more evident in female patients [42–44]. When the studies in the literature were examined, it was determined that hair loss was considered as one of the most disturbing side effects of chemotherapy. In one study, it was shown that 8% of female cancer patients consider stopping chemotherapy to prevent hair loss [45]. The CIA is one of the main sources of stress for patients, as it is the most obvious reminder of the cure and death process for cancer patients [42]. The CIA's effective coping strategies include referrals to mental health professionals, wigs, headscarves, and various haircuts. Patient education and planning are important tools for minimizing distress. Since this approach will prepare the cancer patient for alopecia, it may reduce the effects of alopecia-related emotional stress, anxiety and depression, as well as increase compliance with chemotherapy treatment [38, 42].

3.5 Cicatricial alopecia

Cicatricial alopecia is a type of alopecia characterized by inflammation that permanently destroys hair follicles and leads to fibrotic scarring. Scarred alopecia requires rapid diagnosis and multidisciplinary care due to its irreversible nature and severe psychosocial impact [46]. It has been determined that women with scarred alopecia have a lower quality of life and a heavier psychosocial burden than women with non-scarring alopecia. Psychiatric comorbid conditions such as low quality of life, anxiety, depression, loneliness, social isolation and low self-esteem are found in women with scarred alopecia [47]. In a study examining psychiatric comorbidities in female patients with cicatricial alopecia, a 10% prevalence of comorbid depressive or anxiety disorders was found [48]. The psychological impact of scarred alopecia has been reported to be equally severe in both sexes, but concerns about appearance are more pronounced in female patients. Esthetic concerns were found to be higher in young patients who felt old due to scarred alopecia [49]. In a study comparing female patients with and without scarring, it was shown that the quality of life of female patients with scarred alopecia was more affected, and accordingly anxiety and depression were more common [47]. It has been suggested that in scarred alopecia, patients spend too much time and effort to normalize their appearance, resulting in reduced success in friendship, work and school life [49]. The psychosocial burden of the disease is reduced by including psychological counseling and support groups in the care plan. Early diagnosis and treatment are important to prevent irreversible hair loss in scarred alopecia. The initiation of psychological support in the early period is also important in terms of a holistic treatment approach.

3.6 Trichotillomania

It is a disease that is characterized by the voluntary and involuntary pulling out of one's own hair and hair and is basically included in the scope of primary psychiatric diseases. Due to its similarities with obsessive compulsive disorder, it has also been evaluated as one of the obsessive compulsive spectrum disorders [50]. Although it can be seen in different anatomical regions, one of the most affected areas is the scalp, pubic hair, and facial areas such as the eyebrows, eyelashes and beard. Although rare, one of the areas that are plucked is the nose hair [51]. Trichotillomania patients, on the one hand, relieve their stress and distress with hair pulling, on the other hand, experience a significant sense of shame, social isolation and deterioration in their quality of life. Psychological disorders such as low self-esteem, depression, anxiety etc. are characteristic of these patients [52]. Nail biting, thumb sucking, nose picking, masturbation, school problems and bad friendships may accompany in children. Comorbidity with major depressive disorder and anxiety disorders is quite common. In addition, increased rates of obsessive-compulsive disorder were detected both in patients with trichotillomania and in their relatives. Personality disorders in adults may be accompanied by conduct disorders in young people. The most common personality disorder is histrionic personality disorder with a rate of 26% [53]. Family studies have found an increased rate of hair pulling and obsessive compulsive disorder in first-degree relatives of trichotillomania cases [54].

4. Psychiatric symptoms and disorders comorbid with alopecia

4.1 Alopecia and depression

The presence of depressive symptoms in alopecia areata patients has been known for years. Colon et al. in their study, they predicted the lifetime prevalence of major depressive disorder as 39% in patients with alopecia areata [55]. Studies on this subject in the following years also suggest that the incidence of depression in alopecia has increased. Şahin et al., in their study with the beck depression inventory, compared the patients followed up with the diagnosis of alopecia areata and healthy volunteers; found the rate of depression to be 16.7% in healthy volunteers and 64.6% in patients with alopecia [56]. In the study of Arı et al., in which they compared the Beck depression, beck anxiety and alexithymia scale with patients with alopecia and healthy volunteers, no difference was found between the groups in terms of anxiety and alexithymia, but the depression scores of the alopecia group were found to be higher [57]. In another study conducted with the hospital anxiety depression scale, depression was found to be significantly higher than the control group with 38% [58]. The limitation of all these studies is that they are based on the use of scales rather than clinical interviews, but on the other hand, there seems to be an accumulation of knowledge that depressive symptoms are more common in patients with alopecia. It appears to be a risk group for major depressive disorder in children and adolescents with alopecia. In a study conducted with the evaluation of 5117 patients with alopecia areata in Taiwan, it was determined that alopecia areata, which started under the age of 20, poses a risk for major depressive disorder [24]. Although depression is thought to be more common in patients with alopecia, another point of view is the possibility that depression may exacerbate alopecia. In a case-control study conducted in Taiwan, patients with alopecia areata had higher rates of psychiatric disease; however, 50% of these people have been shown to have a psychiatric illness that precedes alopecia [24]. It has also been reported that a quarter of patients with alopecia areata experience stressful life events before the onset or exacerbation of the disease [59]. In another study, a significant relationship was shown between exacerbations in patients with alopecia areata and the patients' perception of stress and state anxiety scores [60]. Studies have shown that imipramine, an antidepressant drug, and hypnotic approaches reduce depressive symptoms in alopecia areata and produce significant hair growth [61, 62]. There are other studies showing that the onset and exacerbations of alopecia areata may be associated with stressful life events. In fact, it is known that the stress response of the hypothalamopituitary axis (HPA) in the face of emotional stress can trigger not only alopecia, but also many other dermatological diseases (psoriasis, atopic dermatitis, urticaria, vitiligo, acne, etc.). There are studies that associate and investigate this link with common neuromediators associated with psychoneuroimmunological systems [63].

4.2 Alopecia and anxiety disorders

Many studies have shown that anxiety disorders are more common in alopecia areata. It is now accepted that visual lesions in the hair can have negative psychological consequences. In addition to the physical appearance of the disease, it has been shown that the chronic and poor course also causes anxiety. This can

cause great concern, especially in women and young adults [62, 64]. In one study, generalized anxiety disorder was found in 39% of patients with alopecia areata. The same study reported that the frequency of anxiety disorders is higher in first-degree relatives of patients with alopecia [55]. Later, many studies have been conducted to support the knowledge that anxiety disorders are common in alopecia areata [17]. Onset at different ages in alopecia areata can also be a risk factor. Onset between the ages of 20 and 39 has been shown to be a risk factor for anxiety disorders [24]. In a study conducted in patients with refractory alopecia areata, hypnosis was used to improve psychiatric symptoms; It was determined that the severity of alopecia of the patients whose psychiatric symptoms improved, also decreased [62]. The most common anxiety disorder with alopecia areata is obsessive compulsive disorder [28].

4.3 Alopecia and schizophrenia

Schizophrenia is a serious psychiatric disorder with impaired ability to evaluate reality, hallucinations and delusions, disorganized thoughts and behaviors. In a case-control study conducted with 5117 patients in Taiwan, alopecia areata was found to be less common in schizophrenia, unlike other psychiatric diseases [24]. Case reports in this area are also limited. Years ago, Kubota et al. reported three cases of zotepine-induced alopecia areata, one schizophrenic and two bipolar, and the symptoms improved upon reduction or discontinuation of the zotepine dose [65]. In a recent case-control study of alopecia areata in the USA, the authors reported a higher incidence of schizophrenia and other psychotic disorders among patients with alopecia areata [27]. On the other hand, a large case-control study involving 5117 alopecia areata patients in Taiwan reported contrasting findings and showed a negative association between alopecia areata and schizophrenia [24]. A study conducted in Israel comparing 41,055 patients with alopecia areata to a control group found that schizophrenia was negatively associated with alopecia areata in both men and women [66]. It is not known how schizophrenia protects against alopecia areata. This area seems open to research.

4.4 Effects of alopecia on quality of life

Quality of life is a broad concept. It assesses whether it limits the patient's ability to perform a normal role in their daily life, as well as the burden and outcomes of the treatments offered. It is defined as patients' subjective perception of its impact on their physical, psychological, and social functioning [67]. Quality of life in diseases such as alopecia areata is a strong and important indicator of the disease on social relations, daily activities and psychosocial status [67]. The effectiveness of treatment in alopecia areata, the social and financial burden of the disease can be evaluated using quality of life indicators [68]. In a case-control prospective study involving 115 women with alopecia and 97 control patients of the same age, alopecia was found to significantly affect female sexual functioning, reducing desire, arousal, lubrication, orgasm, and satisfaction [69]. A meta-analysis of 2530 patients showed that alopecia significantly reduces patients' quality of life [70]. As a result of studies using various quality of life tools, it has also been shown that alopecia has a detrimental effect on the quality of life of patients and that there is an improvement in quality of life with improvement in disease status [71, 72].

4.5 Alopecia and suicidal behavior

The relationship between suicide and alopecia is not completely clear. Although one report concluded that patients with alopecia areata did not show suicidal thoughts, another study found that 12.8% of patients with alopecia areata were at risk of committing suicide [73, 74]. In further support of the possible increased risk of suicide in patients with alopecia areata, a case series of suicides in 4 boys aged 14–17 years afflicted with alopecia areata within 1 year of diagnosis is presented [75].

4.6 Alopecia and personality profiles

Patients with alopecia areata have a characteristic personality profile with low novelty seeking, low reward dependence, and low self-transcendence [76]. More withdrawn, depressive, and aggressive features are found in approximately 40–50% of children with alopecia areata [77]. There are not many studies on the personality traits of these patients, and the incidence of personality disorders in this group has not been studied either. There is a study documenting high depression, psychosthenia, and social introversion subscales in the Minnesota Multidimensional Personality Inventory (MMPI) assessment in this group [78]. Carrizosa et al. used the Minnesota Multidimensional Personality Inventory to show that patients with alopecia areata expressed more depressed, hysterical, and anxious feelings than healthy subjects [79].

4.7 Alopecia and alexithymia

Alexithymia is a cognitive disorder related to the identification and expression of emotions. Its basic features can be listed as disorders in emotional awareness, social connectedness, and interpersonal relationships [80]. Although there are conflicting results, there are studies showing a relationship between skin diseases and alexithymia [81]. Features associated with alexithymia have also been found in individuals with alopecia areata. Alexithymia is seen at a higher rate in patients with alopecia areata than in the healthy group [82]. It will be useful to take alexithymia into account when evaluating the psychological state of the patient [83].

4.8 The effects of alopecia on self-image and self-esteem

Hair is important for individuals due to its cosmetic functions as well as its anatomical and physiological features. Hair loss can lead to low self-esteem and a negative self-image. It is known that hair loss in children significantly affects their social and psychological well-being, and children may experience significant psychological distress due to stigma, ridicule, bullying and peer pressure [84]. In a study conducted on female patients with a diagnosis of gynecological cancer, it was determined that 13% of the patients believed that they would be rejected by their spouses when hair loss occurred [85]. In a study conducted by Yin et al. between patients with and without cosmetic surgery, it was found that preoperative patients had lower self-esteem than the control group, and there was no significant difference in the self-esteem of the patients after surgery compared to the control group. As a result, it shows that plastic surgery can increase self-esteem and self-efficacy [86].

4.9 Alopecia and stigmatization

Physical appearance and attractiveness have a special importance in today's social structure. Therefore, hair problems, which play an important role in physical attractiveness, can create significant psychological and social problems for people. One of these problems is stigma [87]. Stigma is the state of being humiliated, ostracized and ignored by the general society due to an illness. In other words, stigma means scar, stain, a sign of shame and humiliation that marks the person [88]. Hair diseases act as a stigma, as they cause significant changes in physical appearance. For this reason, stigma becomes an important psychological problem in patients with hair diseases [23]. In a study conducted by Temel et al., a statistically significant correlation was found between the Internalized Stigma Scale scores of patients due to alopecia areata and the scores measured by both the Dermatology Quality of Life Index and the General Health Questionnaire. In the study, internalized stigma scores of patients with alopecia areata were also found to be higher than those of patients with acne vulgaris and vitiligo [89]. In another study by Creadore et al., it was determined that as the severity of alopecia increased, the approval of each stigma item by the participating patients increased [90]. Medical and complementary treatments for alopecia, such as wigs, can alleviate the severity of stigma.

5. Alopecia and psychotropic drugs

It does not seem possible to say that psychotropic drugs are directly related to alopecia. There are case reports with citalopram, sertraline, venlafaxine and quetiapine [91–94]. Psychotropic drugs are widely used in the research, development, production, measurement of clinical effects and use in the community, and side effect profiles are created. A direct relationship between alopecia and any antipsychotic or antidepressant drug has not been determined. Case reports remind us that individual responses should be considered. It is known that mood-stabilizing drugs such as lithium, valproic acid and carbamazepine may be associated with hair loss [95]. It may be necessary to benefit from psychotropics in the treatment of comorbid psychiatric comorbidity in patients with alopecia as well as in the normal population. In a study comparing the use of 20 mg citalopram and triamcinolone with the use of only triamcinolone injections in patients with alopecia diagnosed with major depressive disorder, it was found that the use of citalopram significantly contributed to the improvement of alopecia symptoms as well as depression symptoms [96].

6. Psychiatric treatment approaches of alopecia

Data on the results of the use of psychopharmacology in the treatment of alopecia are very limited in the literature. The positive effect of imipramine, which is a tricyclic antidepressant, on alopecia has been demonstrated in a study in the literature [61]. The useful effects of citalopram and paroxetine were also demonstrated in one study [97, 98]. If there are psychiatric disorders or symptoms accompanying alopecia, some psychotherapy treatment methods can be used as well as psychopharmacological treatments. In dermatology, indications for psychotherapy include: worsening of disease-related symptoms under chronic or acute stress, increased secondary social avoidance and anxiety when a possible cause of body dysmorphic disorder

is suspected, significant skin manipulation or self-harm is observed [99]. Some of these psychotherapy methods are cognitive behavioral therapy (CBT), habit reversal training (HRT), mindfulness therapies and hypnosis [99]. In a study conducted on patients with alopecia, it was shown that CBT has a positive effect on quality of life and depressive symptoms. In addition, it was determined that hair loss was less than the control group during the treatment [100]. Various psychotherapeutic techniques have been applied in the treatment of trichotillomania. However, HRT has been widely used with success, especially when combined with pharmacological therapy. HRT shares the basic principles of CBT but aims to reverse the positive reinforcement developed by patients with trichotillomania. By completing therapy, patients learn to effectively monitor and raise awareness of their hair-pulling behavior [101]. In a study conducted by applying mindfulness therapy, an improvement in quality of life and a decrease in psychiatric symptoms were found in patients with alopecia [102].

7. Conclusion


Hair is the most appearing and noticeable part of the body. It is a very important part for the psychologically healthy development of the individual from childhood to adulthood and even death. Alopecia is a disease that should be evaluated with its psychiatric dimensions. Having a diagnosis of alopecia at a young age, especially in children and adolescents, increases the risk in terms of psychiatric diseases. Mental disorders related to alopecia manifest themselves with many different psychiatric symptoms. However, many psychiatric disorders can also cause hair loss. The basis of psychosomatization of patients with alopecia who usually present to the dermatology outpatient clinic should be investigated and referred to a psychiatrist for appropriate psychotherapy or psychopharmacotherapy.

Author details

Dogancan Sonmez* and Cicek Hocaoglu
Department of Psychiatry, Medical School, Recep Tayyip Erdogan University, Rize,
Turkey

*Address all correspondence to: dogancansonmezz@gmail.com

IntechOpen

© 2022 The Author(s). Licensee IntechOpen. This chapter is distributed under the terms of the Creative Commons Attribution License (<http://creativecommons.org/licenses/by/3.0>), which permits unrestricted use, distribution, and reproduction in any medium, provided the original work is properly cited. 

References

- [1] Jafferany M, Patel A. Trichopsychodermatology: The psychiatric and psychosocial aspects of hair disorders. *Dermatologic Therapy*. 2020;**33**(1):e13168. DOI: 10.1111/dth.13168
- [2] Aghaei S, Saki N, Daneshmand E, Kardeh B. Prevalence of psychological disorders in patients with alopecia areata in comparison with normal subjects. *ISRN dermatology*. 2014;**2014**:304370. DOI: 10.1155/2014/304370
- [3] Eller JJ. Skin disorder and the psyche. *Cutis*. 1974;**13**:395-416. DOI:
- [4] Fruensgaard K, Hjortshøj A, Nielsen H. Neurotic excoriations. *International Journal of Dermatology*. 1978;**17**(10):761-767. DOI: 10.1111/j.1365-4362.1978.tb05976.x
- [5] Alexander F. Psychosomatic medicine. *British Journal for the Philosophy of Science*. 1953;**4**(15):260-262
- [6] Gupta MA. Somatization disorders in dermatology. *International Review of Psychiatry (Abingdon, England)*. 2006;**18**(1):41-47. DOI: 10.1080/09540260500466832
- [7] Altunay IK. History of psychodermatology and a global view/ Psikodermatoloji tarihcesi ve genel bakis. *Archives of the Turkish Dermatology and Venerology*. 2010;**44**(1):4-6
- [8] Didier A. *The Skin-Ego*. New Haven-London: Yale University Press; 1985
- [9] Koblenzer PJ. A brief history of psychosomatic dermatology. *Dermatologic Clinics*. 1996;**14**(3): 395-397. DOI: 10.1016/s0733-8635(05) 70367-3
- [10] Koo JY, Lee CS. General approach to evaluating psychodermatological disorders. In: Koo J, Ya L, editors. *Psychocutaneous Medicine*. New York: Marcell Dekker; 2003. pp. 1-29
- [11] Gow R, Thomson S, Rieder M, Van Uum S, Koren G. An assessment of cortisol analysis in hair and its clinical applications. *Forensic Science International*. 2010;**196**(1-3):32-37. DOI: 10.1016/j.forsciint.2009.12.040
- [12] Wester VL, van Rossum EF. Clinical applications of cortisol measurements in hair. *European Journal of Endocrinology*. 2015;**173**(4):M1-M10. DOI: 10.1530/eje-15-0313
- [13] Katsarou-Katsari A, Singh LK, Theoharides TC. Alopecia areata and affected skin CRH receptor upregulation induced by acute emotional stress. *Dermatology (Basel, Switzerland)*. 2001;**203**(2):157-161. DOI: 10.1159/000051732
- [14] Toyoda M, Makino T, Kagoura M, Morohashi M. Expression of neuropeptide-degrading enzymes in alopecia areata: An immunohistochemical study. *British Journal of Dermatology*. 2001;**144**(1):46-54. DOI: 10.1046/j.1365-2133.2001.03951.x
- [15] Basavaraj KH, Navya MA, Rashmi R. Relevance of psychiatry in dermatology: Present concepts. *Indian Journal of Psychiatry*. 2010;**52**(3):270-275. DOI: 10.4103/0019-5545.70992
- [16] Mirzoyev SA, Schrum AG, Davis MDP, Torgerson RR. Lifetime incidence risk of alopecia areata estimated at 2.1% by Rochester epidemiology project, 1990-2009. *The*

Journal of Investigative Dermatology. 2014;**134**(4):1141-1142. DOI: 10.1038/jid.2013.464

[17] Ghanizadeh A, Ayoobzadehshirazi A. A review of psychiatric disorders comorbidities in patients with alopecia areata. *International Journal of Trichology*. 2014;**6**(1):2

[18] Messenger AG, McKillop J, Farrant P, McDonagh AJ, Sladden M. British Association of Dermatologists' guidelines for the management of alopecia areata 2012. *The British Journal of Dermatology*. 2012;**166**(5):916-926. DOI: 10.1111/j.1365-2133.2012.10955.x

[19] Barkauskaite R, Serapinas D. Therapeutic implications of psychological state in patients with alopecia areata: A qualitative study. *Dermatologic Therapy*. 2020;**33**(6):e14269. DOI: 10.1111/dth.14269

[20] Lee H, Kim YC, Choi JW. Alopecia areata is not a risk factor for heart diseases: A 10-year retrospective cohort study. *PLoS One*. 2021;**16**(5):e0250216-e025021e. DOI: 10.1371/journal.pone.0250216

[21] Schmidt S. Female alopecia: The mediating effect of attachment patterns on changes in subjective health indicators. *The British Journal of Dermatology*. 2003;**148**(6):1205-1211. DOI: 10.1046/j.1365-2133.2003.05327.x

[22] Dai YX, Tai YH, Chen CC, Chang YT, Chen TJ, Chen MH. Bidirectional association between alopecia areata and major depressive disorder among probands and unaffected siblings: A nationwide population-based study. *Journal of the American Academy of Dermatology*. 2020;**82**(5):1131-1137. DOI: 10.1016/j.jaad.2019.11.064

[23] Kacar SD, Soyucok E, Bagcioglu E, Ozuguz P, Coskun KS, Asik AH, et al. The perceived stigma in patients with alopecia and mental disorder: A comparative study. *International Journal of Trichology*. 2016;**8**(3):135-140. DOI: 10.4103/0974-7753.189005

[24] Chu SY, Chen YJ, Tseng WC, Lin MW, Chen TJ, Hwang CY, et al. Psychiatric comorbidities in patients with alopecia areata in Taiwan: A case-control study. *British Journal of Dermatology*. 2012;**166**(3):525-531

[25] Liakopoulou M, Alifieraki T, Katideniou A, Kakourou T, Tselalidou E, Tsiantis J, et al. Children with alopecia areata: Psychiatric symptomatology and life events. *Journal of the American Academy of Child and Adolescent Psychiatry*. 1997;**36**(5):678-684. DOI: 10.1097/00004583-199705000-00019

[26] Davey L, Clarke V, Jenkinson E. Living with alopecia areata: An online qualitative survey study. *The British Journal of Dermatology*. 2019;**180**(6):1377-1389. DOI: 10.1111/bjd.17463

[27] Singam V, Patel KR, Lee HH, Rastogi S, Silverberg JI. Association of alopecia areata with hospitalization for mental health disorders in US adults. *Journal of the American Academy of Dermatology*. 2019;**80**(3):792-794. DOI: 10.1016/j.jaad.2018.07.044

[28] Ghanizadeh A. Comorbidity of psychiatric disorders in children and adolescents with alopecia areata in a child and adolescent psychiatry clinical sample. *International Journal of Dermatology*. 2008;**47**(11):1118-1120. DOI: 10.1111/j.1365-4632.2008.03743.x

[29] Ellis JA, Sinclair R, Harrap SB. Androgenetic alopecia: Pathogenesis and potential for therapy. *Expert Reviews in*

Molecular Medicine. 2002;4(22):1-11.
DOI: 10.1017/s1462399402005112

[30] Cash TF. The psychological effects of androgenetic alopecia in men. *Journal of the American Academy of Dermatology*. 1992;26(6):926-931. DOI: 10.1016/0190-9622(92)70134-2

[31] Cash TF. The psychology of hair loss and its implications for patient care. *Clinics in Dermatology*. 2001;19(2):161-166. DOI: 10.1016/s0738-081x(00)00127-9

[32] Budd D, Himmelberger D, Rhodes T, Cash TE, Girman CJ. The effects of hair loss in European men: A survey in four countries. *European Journal of Dermatology : EJD*. 2000;10(2):122-127

[33] Girman CJ, Rhodes T, Lilly FR, Guo SS, Siervogel RM, Patrick DL, et al. Effects of self-perceived hair loss in a community sample of men. *Dermatology (Basel, Switzerland)*. 1998;197(3):223-229. DOI: 10.1159/000018001

[34] Tabolli S, Sampogna F, di Pietro C, Mannooranparampil TJ, Ribuffo M, Abeni D. Health status, coping strategies, and alexithymia in subjects with androgenetic alopecia: A questionnaire study. *American Journal of Clinical Dermatology*. 2013;14(2):139-145. DOI: 10.1007/s40257-013-0010-3

[35] Cash TF, Price VH, Savin RC. Psychological effects of androgenetic alopecia on women: Comparisons with balding men and with female control subjects. *Journal of the American Academy of Dermatology*. 1993;29(4):568-575. DOI: 10.1016/0190-9622(93)70223-g

[36] Quinn M, Shinkai K, Pasch L, Kuzmich L, Cedars M, Huddleston H. Prevalence of androgenic alopecia in patients with polycystic ovary

syndrome and characterization of associated clinical and biochemical features. *Fertility and Sterility*. 2014;101(4):1129-1134. DOI: 10.1016/j.fertnstert.2014.01.003

[37] Jackson AJ, Price VH. How to diagnose hair loss. *Dermatologic Clinics*. 2013;31(1):21-28. DOI: 10.1016/j.det.2012.08.007

[38] Kutlubay Z, Serdaroglu S. *Hair and Scalp Disorders*. London: IntechOpen; 2017. DOI: 10.5772/63002

[39] Cline A, Kazemi A, Moy J, Safai B, Marmon S. A surge in the incidence of telogen effluvium in minority predominant communities heavily impacted by COVID-19. *Journal of the American Academy of Dermatology*. 2021;84(3):773-775. DOI: 10.1016/j.jaad.2020.11.032

[40] Kıvanç Aİ. Saç dökülmelerinin psikososyal etkileri. In: Z İ, editor. *Saç Dökülmeler*. 1.Baskı ed. Ankara: Türkiye Klinikleri; 2021. pp. 78-82

[41] Moattari CR, Jafferany M. Psychological aspects of hair disorders: Consideration for dermatologists, cosmetologists, aesthetic, and plastic surgeons. *Skin Appendage Disorders*. 2022;8(3):186-194. DOI: 10.1159/000519817

[42] Hesketh PJ, Batchelor D, Golant M, Lyman GH, Rhodes N, Yardley D. Chemotherapy-induced alopecia: Psychosocial impact and therapeutic approaches. *Supportive Care in Cancer : Official Journal of the Multinational Association of Supportive Care in Cancer*. 2004;12(8):543-549. DOI: 10.1007/s00520-003-0562-5

[43] Dua P, Heiland MF, Kracen AC, Deshields TL. Cancer-related hair loss: A selective review of the alopecia

research literature. *Psycho-Oncology*. 2017;**26**(4):438-443. DOI: 10.1002/pon.4039

[44] Griffin AM, Butow PN, Coates AS, Childs AM, Ellis PM, Dunn SM, et al. On the receiving end. V: Patient perceptions of the side effects of cancer chemotherapy in 1993. *Annals of Oncology : Official Journal of the European Society for Medical Oncology*. 1996;**7**(2):189-195. DOI: 10.1093/oxfordjournals.annonc.a010548

[45] Tierney AJ, Taylor J, Closs SJ. Knowledge, expectations and experiences of patients receiving chemotherapy for breast cancer. *Scandinavian Journal of Caring Sciences*. 1992;**6**(2):75-80. DOI: 10.1111/j.1471-6712.1992.tb00128.x

[46] Tan E, Martinka M, Ball N, Shapiro J. Primary cicatricial alopecias: Clinicopathology of 112 cases. *Journal of the American Academy of Dermatology*. 2004;**50**(1):25-32. DOI: 10.1016/j.jaad.2003.04.001

[47] Katoulis AC, Christodoulou C, Liakou AI, Kouris A, Korkoliakou P, Kaloudi E, et al. Quality of life and psychosocial impact of scarring and non-scarring alopecia in women. *Journal der Deutschen Dermatologischen Gesellschaft = Journal of the German Society of Dermatology : JDDG*. 2015;**13**(2):137-142. DOI: 10.1111/ddg.12548

[48] McKenzie SA, Roche FC, Onyekaba G, Williams DM, Ogunleye TA, Taylor SC. Comorbid anxiety and depression among black women with central centrifugal cicatricial alopecia: A retrospective study. *The Journal of Dermatology*. 2021;**48**(1):e19. DOI: 10.1111/1346-8138.15595

[49] Pradhan P, D'Souza M, Bade BA, Thappa DM, Chandrashekar L. Psychosocial impact of cicatricial alopecias. *Indian Journal of Dermatology*. 2011;**56**(6):684-688. DOI: 10.4103/0019-5154.91829

[50] Van Ameringen M, Patterson B, Simpson W. DSM-5 obsessive-compulsive and related disorders: Clinical implications of new criteria. *Depression and Anxiety*. 2014;**31**(6):487-493. DOI: 10.1002/da.22259

[51] Sonmez D, Hocaoglu C. A rare type of trichotillomania: Rhinotillomania. Dusunen Adam the *Journal of Psychiatry Neurological Sciences*. 2019;**32**(3):279. DOI: 10.14744/DAJPNS.2019.00039

[52] Jafferany M. Tricho psychodermatology (Psychiatric Aspects of Hair Disorders). *Handbook of Psychodermatology: Introduction to Psychocutaneous Disorders*. Cham: Springer International Publishing; 2022. pp. 57-64. DOI: 10.1007/978-3-030-90916-1_9

[53] Swedo SE, Leonard HL. Trichotillomania. An obsessive compulsive spectrum disorder? The psychiatric clinics of north. America. 1992;**15**(4):777-790. DOI: doi

[54] Keuthen NJ, Altenburger EM, Pauls D. A family study of trichotillomania and chronic hair pulling. *American Journal of Medical Genetics Part B, Neuropsychiatric Genetics : The Official Publication of the International Society of Psychiatric Genetics*. 2014;**165b**(2):167-174. DOI: 10.1002/ajmg.b.32218

[55] Colón EA, Popkin MK, Callies AL, Dessert NJ, Hordinsky MK. Lifetime prevalence of psychiatric disorders in patients with alopecia areata. *Comprehensive Psychiatry*.

1991;**32**(3):245-251. DOI: 10.1016/0010-440X(91)90045-E

[56] Şahin GÖ, Akyol M, Kuğu N, Özçelik S. Alopesi Areata olgularında depresyon. Cumhuriyet Üniversitesi Tıp Fakültesi Dergisi. 2008;**30**:2-3

[57] Ari B, Cenesizoglu E, Denli Y. Psychiatric symptoms in patients with alopecia areata. Turkderm-Archives of the Turkish Dermatology Venerology. 2011;**45**(4):203-205

[58] Sellami R, Masmoudi J, Ouali U, Mnif L, Amouri M, Turki H, et al. The relationship between alopecia areata and alexithymia, anxiety and depression: A case-control study. Indian Journal of Dermatology. 2014;**59**(4):421

[59] Alfani S, Antinone V, Mozzetta A, Pietro CD, Mazzanti C, Stella P, et al. Psychological status of patients with alopecia areata. Acta Dermato-Venereologica. 2012;**92**(3):304-306

[60] Brajac I, Tkalčić M, Dragojević DM, Gruber F. Roles of stress, stress perception and trait-anxiety in the onset and course of alopecia areata. The Journal of Dermatology. 2003;**30**(12):871-878

[61] Perini G, Zara M, Cipriani R, Carraro C, Preti A, Gava F, et al. Imipramine in alopecia areata. A double-blind, placebo-controlled study. Psychotherapy and Psychosomatics. 1994;**61**(3-4):195-198. DOI: 10.1159/000288889

[62] Willemsen R, Haentjens P, Roseeuw D, Vanderlinden J. Hypnosis and alopecia areata: Long-term beneficial effects on psychological well-being. Acta Dermato-Venereologica. 2011;**91**(1):35-39. DOI: 10.2340/00015555-1012

[63] Lugović-Mihić L, Ljubešić L, Mihić J, Vuković-Cvetković V, Troškot N, Šitum M. Psychoneuroimmunologic aspects of skin diseases. Acta Clinica Croatica. 2013;**52**(3):337-345

[64] Hawryluk EB, English JC 3rd. Female adolescent hair disorders. Journal of Pediatric and Adolescent Gynecology. 2009;**22**(4):271-281. DOI: 10.1016/j.jpag.2009.03.007

[65] Kubota T, Ishikura T, Jibiki I. Three cases of alopecia areata induced by zotepine. Acta Neurologica. 1993;**15**(3):200-203

[66] Tzur Bitan D, Berzin D, Kridin K, Cohen A. The association between alopecia areata and anxiety, depression, schizophrenia, and bipolar disorder: A population-based study. Archives of Dermatological Research. 2022;**314**(5):463-468. DOI: 10.1007/s00403-021-02247-6

[67] Shi Q, Duvic M, Osei JS, Hordinsky MK, Norris DA, Price VH, et al. Health-related quality of life (HRQoL) in alopecia areata patients—A secondary analysis of the National Alopecia Areata Registry Data. Journal of Investigative Dermatology Symposium Proceedings. Elsevier. 2013;**16**(1):49-50

[68] Inui S, Inoue T, Itami S. Effect of hairpieces on perceived quality of life in female pattern hair loss patients: Questionnaire based study. The Journal of Dermatology. 2013;**40**(8):671

[69] Sancak EB, Oguz S, Akbulut T, Uludag A, Akbas A, Kurt O, et al. Female sexual dysfunction in androgenetic alopecia: Case-control study. Canadian Urological Association Journal—Journal de l'Association des urologues du Canada. 2016;**10**(7-8):E251-E2e6. DOI: 10.5489/cuaj.3582

- [70] Rencz F, Gulácsi L, Péntek M, Wikonkál N, Baji P, Brodszky V. Alopecia areata and health-related quality of life: A systematic review and meta-analysis. *The British Journal of Dermatology*. 2016;**175**(3):561-571. DOI: 10.1111/bjd.14497
- [71] Ghajarzadeh M, Ghiasi M, Kheirkhah S. Associations between skin diseases and quality of life: A comparison of psoriasis, vitiligo, and alopecia areata. *Acta Medica Iranica*. 2012;**50**(7):511-515
- [72] Fabbrocini G, Panariello L, De Vita V, Vincenzi C, Lauro C, Nappo D, et al. Quality of life in alopecia areata: A disease-specific questionnaire. *Journal of the European Academy of Dermatology Venereology*. 2013;**27**(3):e276-ee81
- [73] Toussi A, Barton VR, Le ST, Agbai ON, Kiuru M. Psychosocial and psychiatric comorbidities and health-related quality of life in alopecia areata: A systematic review. *Journal of the American Academy of Dermatology*. 2021;**85**(1):162-175. DOI: 10.1016/j.jaad.2020.06.047
- [74] Vélez-Muñiz RC, Peralta-Pedrero ML, Jurado-Santa Cruz F, Morales-Sánchez MA. Psychological profile and quality of life of patients with alopecia Areata. *Skin Appendage Disorders*. 2019;**5**(5):293-298. DOI: 10.1159/000497166
- [75] Hankinson A, McMillan H, Miller J. Attitudes and perceptions of school-aged children toward alopecia areata. *JAMA Dermatology*. 2013;**149**(7):877-879
- [76] Beard HO. Social and psychological implications of alopecia areata. *Journal of the American Academy of Dermatology*. 1986;**14**(4):697-700. DOI: 10.1016/s0190-9622(86)80482-0
- [77] Reeve EA, Savage TA, Bernstein GA. Psychiatric diagnoses in children with alopecia areata. *Journal of the American Academy of Child and Adolescent Psychiatry*. 1996;**35**(11):1518-1522. DOI: 10.1097/00004583-199611000-00021
- [78] Monselise A, Bar-On R, Chan L, Leibushor N, McElwee K, Shapiro J. Examining the relationship between alopecia areata, androgenetic alopecia, and emotional intelligence. *Journal of Cutaneous Medicine and Surgery*. 2013;**17**(1):46-51. DOI: 10.2310/7750.2012.12003
- [79] Carrizosa A, Estepa-Zabala B, Fernandez-Abascal B, Garcia-Hernandez MJ, Ruiz-Dablado S. Alopecia areata: A specific personality? *International Journal of Dermatology*. 2005;**44**(5):437-438. DOI: 10.1111/j.1365-4632.2005.02277.x
- [80] Durak Batıgün A, Büyükaşahin A. Alexithymia: Psychological symptoms and attachment styles. *Journal of Clinical Psychiatry*. 2008;**11**(3):105-114
- [81] Poot F, Antoine E, Gravellier M, Hirtt J, Alfani S, Forchetti G, et al. A case-control study on family dysfunction in patients with alopecia areata, psoriasis and atopic dermatitis. *Acta Dermato-Venereologica*. 2011;**91**(4):415-421. DOI: 10.2340/00015555-1074
- [82] Yazici AC, Basterzi A, Acar ST, Ustunsoy D, Ikişoğlu G, Demirseren D, et al. Alopecia areata and alexithymia. *Türk Psikiyatri Dergisi*. 2006;**17**(2):-99
- [83] Willemsen R, Roseeuw D, Vanderlinden J. Alexithymia and dermatology: The state of the art. *International Journal of Dermatology*. 2008;**47**(9):903-910. DOI: 10.1111/j.1365-4632.2008.03726.x
- [84] Silverberg NB. Helping children cope with hair loss. *Cutis*. 2006;**78**(5):333-336

- [85] Münstedt K, Manthey N, Sachsse S, Vahrson H. Changes in self-concept and body image during alopecia induced cancer chemotherapy. *Supportive Care in Cancer : Official Journal of the Multinational Association of Supportive Care in Cancer*. 1997;5(2):139-143. DOI: 10.1007/bf01262572
- [86] Yin Z, Wang D, Ma Y, Hao S, Ren H, Zhang T, et al. Self-esteem, self-efficacy, and appearance assessment of young female patients undergoing facial cosmetic surgery: A comparative study of the Chinese population. *JAMA Facial Plastic Surgery*. 2016;18(1):20-26. DOI: 10.1001/jamafacial.2015.1381
- [87] Schielein MC, Tizek L, Ziehfrennd S, Sommer R, Biedermann T, Zink A. Stigmatization caused by hair loss—A systematic literature review. *JDDG. Journal der Deutschen Dermatologischen Gesellschaft*. 2020;18(12):1357-1368. DOI: 10.1111/ddg.14234
- [88] Sonmez D, Hocaoglu C. Psychosocial impact of COVID-19: Stigma and xenophobia. In: Sánchez-García JC, Hernandez-Sanchez B, Moreira AC, Monteiro APA, editors. *Psychosocial, Educational, and Economic Impacts of COVID-19*. London: IntechOpen; 2021. DOI: 10.5772/intechopen.101527
- [89] Temel A, Bozkurt S, Senol Y, Alpsoy E. Internalized stigma in patients with acne vulgaris, vitiligo, and alopecia areata. *Turkish Journal of Dermatology*. 2019;13(3):109-116. DOI: 10.4103/tjd.Tjd_14_19
- [90] Creadore A, Manjaly P, Li SJ, Tkachenko E, Zhou G, Joyce C, et al. Evaluation of stigma toward individuals with alopecia. *JAMA Dermatology*. 2021;157(4):392-398. DOI: 10.1001/jamadermatol.2020.5732
- [91] Gupta S, Masand PS. Citalopram and hair loss. *The Primary Care Companion for CNS Disorders*. 2000;2(2):61-62. DOI: 10.4088/pcc.v02n0208d
- [92] Rais T, Singh T, Rais A. Hair loss associated with long-term sertraline treatment in teenager. *Psychiatry (Edgmont)*. 2005;2(7):52
- [93] Demir EY. Venlafaxine induced hair loss: A case report. *Dusunen Adam The Journal of Psychiatry and Neurological Sciences*. 2016;29(2):163. DOI: 10.5350/DAJPN2016290208
- [94] Yazici KU, Percinel I. Quetiapine induced hair loss in an adolescent case/ Bir ergen olguda ketiyapin kullanimina bagli saç dökülmesi. *Anadolu Psikiyatri Dergisi*. 2015;16(2):143. DOI: 10.5455/apd.45925
- [95] McKinney PA, Finkenbine RD, DeVane CL. Alopecia and mood stabilizer therapy. *Annals of Clinical Psychiatry : Official Journal of the American Academy of Clinical Psychiatrists*. 1996;8(3):183-185. DOI: 10.3109/10401239609147756
- [96] Abedini H, Farshi S, Mirabzadeh A, Keshavarz S. Antidepressant effects of citalopram on treatment of alopecia areata in patients with major depressive disorder. *The Journal of Dermatological Treatment*. 2014;25(2):153-155. DOI: 10.3109/09546634.2013.768761
- [97] Ruiz-Doblado S, Carrizosa A, García-Hernández MJ. Alopecia areata: Psychiatric comorbidity and adjustment to illness. *International Journal of Dermatology*. 2003;42(6):434-437. DOI: 10.1046/j.1365-4362.2003.01340.x
- [98] Cipriani R, Perini GI, Rampinelli S. Paroxetine in alopecia areata. *International Journal of Dermatology*. 2001;40(9):600-601. DOI: 10.1046/j.1365-4362.2001.01261-3.x

[99] Patel A, Jafferany M, Roque FB. Principles of psychotherapy applied to the Psychodermatologic disorders. In: Jafferany M, Roque Ferreira B, Patel A, editors. *The Essentials of Psychodermatology*. Cham: Springer International Publishing; 2020. pp. 105-110. DOI: 10.1007/978-3-030-45582-8_12

[100] Hart S. A randomised controlled trial of integrative cognitive behavioural therapy for patients with alopecia areata: A pilot study. 2020;**185**(1):49

[101] Bottesi G, Ouimet AJ, Cerea S, Granzio U, Carraro E, Sica C, et al. Comprehensive behavioral therapy of trichotillomania: A multiple-baseline single-case experimental design. *Frontiers in Psychology*. 2020;**11**:1210. DOI: 10.3389/fpsyg.2020.01210

[102] Gallo R, Chiorri C, Gasparini G, Signori A, Burrone A, Parodi A. Can mindfulness-based interventions improve the quality of life of patients with moderate/severe alopecia areata? A prospective pilot study. *Journal of the American Academy of Dermatology*. 2017;**76**(4):757-759. DOI: 10.1016/j.jaad.2016.10.012



*Edited by Trinidad Montero-Vilchez
and Salvador Arias-Santiago*

Discover the latest advancements in alopecia management with *Alopecia Management - An Update*. This comprehensive edited volume brings together leading experts in the field to provide a timely and informative exploration of strategies for managing alopecia. Covering a wide range of topics, this book offers valuable insights into understanding the different types and causes of alopecia, addressing its emotional and psychological impact, practical hair care tips, and emerging therapies. With its cohesive and logically arranged chapters, *Alopecia Management - An Update* is an essential resource for individuals affected by alopecia, caregivers, and healthcare professionals. Benefit from the expertise of renowned contributors who share their knowledge and experiences in this comprehensive volume. Explore the latest advancements in alopecia management, make informed decisions, and enhance your understanding of this condition.

Published in London, UK

© 2023 IntechOpen
© Arthito / iStock

IntechOpen

