

MUNI
MED

UNIVERSITY
TEXTBOOK
ON ORAL
MUCOSAL
DISEASES

LYDIE IZAKOVIČOVÁ HOLLÁ
ANTONÍN FASSMANN
HANA POSKEROVÁ
PETRA BOŘILOVÁ LINHARTOVÁ
ZDENĚK DANĚK

Masaryk University Press
Brno 2020

Authors:

Prof. MUDr. Lydie Izakovičová Hollá, Ph.D., Department of Stomatology, St. Anne's University Hospital Brno and Faculty of Medicine, Masaryk University, Brno

Prof. MUDr. Antonín Fassmann, CSc., Department of Stomatology, St. Anne's University Hospital Brno and Faculty of Medicine, Masaryk University, Brno

MUDr. Hana Poskerová, Ph.D., Department of Stomatology, St. Anne's University Hospital Brno and Faculty of Medicine, Masaryk University, Brno

Doc. RNDr. Petra Bořilová Linhartová, Ph.D., Department of Stomatology and Department of Pathophysiology, Faculty of Medicine, Masaryk University, Brno

MUDr. et MUDr. Zdeněk Daněk, Ph.D., Department of Oral and Maxillofacial Surgery, Faculty of Medicine, Masaryk University, Brno, and University Hospital Brno

Consultant:

Prof. MUDr. Markéta Hermanová, Ph.D., Institute of Pathological Anatomy, St. Anne's University Hospital Brno and Faculty of Medicine, Masaryk University, Brno

Reviewers:

MUDr. Věra Sazmová

Doc. MUDr. Ivan Erdelský CSc.

Translated to English by:

RNDr. Jaroslav Janošek, Ph.D.



CC BY-NC-ND 4.0 Creative Commons Attribution-NonCommercial-NoDerivatives 4.0

© 2020 Masaryk University Press

ISBN 978-80-210-9563-2

ISBN 978-80-210-9550-2 (Czech edition)

Table of Contents

TABLE OF CONTENTS.....	3
FOREWORD.....	9
LIST OF ABBREVIATIONS AND ACRONYMS	10
1. NOTES ON THE MORPHOLOGY OF THE ORAL MUCOSA	12
2. PRINCIPLES OF PATIENT INVESTIGATION.....	16
2.1. Patient history	16
2.2. Objective findings and methods of examination of the oral cavity	17
2.2.1. Histopathological changes.....	18
2.2.2. Morphology of mucosal manifestations	19
Primary efflorescences	19
Secondary efflorescences	20
2.2.3. Location and duration of mucosal manifestations	21
2.2.4. The examination.....	21
2.3. Additional laboratory tests.....	23
2.3.1. Haematological tests	23
2.3.2. Immunological tests	23
2.3.3. Biopsy	23
2.3.4. Microbiological examination	24
Virological examination	24
Bacteriological examination.....	25
Mycological examination	26
2.4. Specialist examinations and consultations	26
3. COMMON ANATOMICAL ABNORMALITIES OF THE ORAL MUCOSA	28
3.1. Linea alba.....	28
3.2. Fordyce spots/granules (morbus Fordyce).....	28
3.3. Leukoedema.....	28
3.4. Physiological melanin hyperpigmentations.....	28
4. CONGENITAL AND DEVELOPMENTAL ABNORMALITIES OF THE ORAL MUCOSA	30
4.1. Cleft lip.....	30
4.2. Double lip.....	30

4.3. Bifid uvula/hypoplasia of the uvula	30
4.4. Ankyloglossia (lingua accreta, tongue tie).....	30
4.5. White sponge nevus (Cannon disease, naevus spongiosus albus).....	31
4.6. Darier disease (hereditary follicular dyskeratosis)	31
4.7. Geographic tongue (lingua geographica, glossitis migrans)	31
4.8. Fissured tongue (l. plicata/ gyrata/scrotalis/cerebriformis/fissurata).....	32
4.9. Crenated tongue (impressions on the sides of the tongue).....	33
5. EXTERNAL CAUSES.....	34
5.1. Physical factors.....	34
5.1.1. Traumatic changes of the oral mucosa	34
Traumatic ulcer	34
Neurodystrophic ulcer of the oral mucosa.....	35
Traumatic gingivitis/stomatitis.....	35
Epulis fissuratum (denture hyperplasia)	35
Cheek and lip bite stomatitis (morsicatio buccarum et labiorum)	36
Frictional keratosis	36
Cotton roll stomatitis.....	36
Oral haematoma	36
Suction trauma of the palatal mucosa.....	36
Common cheilitis (chapped lips, cheilitis simplex).....	37
Exfoliative cheilitis (cheilitis exfoliativa)	37
5.1.2. Stomatitis caused by thermal factors.....	37
5.1.3. Electrogalvanic stomatitis	37
5.1.4. Actinic cheilitis (solar cheilitis, ch. actinica, solaris, abrasiva).....	38
5.2. Chemical factors.....	38
5.2.1. Stomatitis due to corrosive substances (burning).....	39
5.2.2. Toxic effects of xenobiotics	39
Drug-induced stomatitis of toxic origin.....	41
5.2.3. Tobacco abuse-associated changes of the oral mucosa	43
Smoker's melanosis	43
Smoker's leukokeratosis (stomatitis fumantium, leukokeratosis nicotinic palati)	43
Smoking related leukoplakia	44
Squamous cell carcinoma of the oral cavity	44
5.2.4. Exogenous pigmentations.....	44
Amalgam tattoo	45
Metallic gingival pigmentations	45
Pigmentations caused by heavy metals and their salts	45
5.3. Viral infections	46
5.3.1. Diseases caused by the „herpes simplex virus“	46
Primary herpetic gingivostomatitis.....	47
Pustulosis varioliformis (eczema herpeticum, Kaposi varicelliform eruption)	48
Recurrent herpetic stomatitis (intraoral herpes, stomatitis herpetica recidivans)	48
Labial herpes simplex (herpes simplex labialis, herpes labialis).....	49
5.3.2. Diseases of the „Varicella zoster virus“ group.....	50
Varicella (chicken pox)	50
Herpes zoster (shingles)	50

5.3.3.	Epstein-Barr virus and cytomegaloviruses group diseases.....	52
	Infectious mononucleosis (monocytic angina, Pfeiffer's disease).....	52
	„Hairy“ leukoplakia.....	53
	Cytomegalovirus disease.....	54
5.3.4.	Enterovirus infections	54
	Herpangina	54
	Vesicular stomatitis with exanthema on hands and feet (hand, foot and mouth disease).....	55
5.3.5.	Measles (morbilli)	55
5.3.6.	Infections caused by the human papillomavirus (HPV).....	55
5.3.7.	Manifestations of the primary HIV infection in the oral cavity	57
5.4.	Bacterial infections.....	57
5.4.1.	Necrotizing diseases of the periodontium	57
	Acute necrotizing ulcerative gingivitis.....	58
	Necrotizing ulcerative periodontitis	59
5.4.2.	Contagious impetigo (impetigo contagiosa).....	59
5.4.3.	Syphilis.....	60
5.4.4.	Tuberculosis	62
5.5.	Fungal (mycotic) infections	63
5.5.1.	Oral candidosis (formerly moniliasis, thrush).....	63
	Acute pseudomembranous candidosis.....	65
	Acute erythematous candidosis	65
	Chronic pseudomembranous candidosis	65
	Chronic hyperplastic candidosis.....	65
	Chronic erythematous atrophic candidosis.....	66
	Angular candidosis.....	66
	Median rhomboid glossitis (glossitis rhombica mediana, Brocque-Pautrier's glossitis).....	67
	Black hairy tongue (lingua villosa nigra)	67
5.5.2.	Systemic (deeply invasive) mycoses.....	68
5.6.	Manifestations of deficiency of vitamins of the A and B groups and Fe on the oral mucosa	68
6.	INTERNAL CAUSES	69
6.1.	Immunopathological diseases of the oral mucosa.....	69
6.1.1.	Allergic reactions, hypersensitivity of the oral mucosa.....	70
	Drug-induced allergic stomatitis (stomatitis medicamentosa).....	71
	Angioedema	71
6.1.2.	Manifestations of autoimmune diseases on the oral mucosa.....	72
	Diseases of the pemphigus group	73
	Diseases of the pemphigoid group	75
	Dermatitis herpetiformis (Duhring-Brocque disease)	76
	Epidermolysis bullosa	77
	Lupus erythematosus (LE)	77
	Psoriasis (psoriasis vulgaris)	79
	Sjögren syndrome.....	79
6.1.3.	Immune system-associated stomatitides.....	81
	Oral lichen planus.....	81
	Oral lichenoid lesions (lichenoid reactions of the oral mucosa).....	83
	Erythema multiforme (erythema exsudativum multiforme Hebrae, EEM)	83
	Stevens-Johnson's syndrome.....	84
	Recurrent aphthous stomatitis	84
	Behçet's syndrome	88
	Touraine's aphthosis.....	89

6.1.4.	Immunodeficient conditions.....	89
	Changes in the oral cavity in patients with HIV infection/AIDS (Acquired Immune Deficiency Syndrome)	89
6.2.	Changes in the oral cavity associated with systemic diseases	94
6.2.1.	Changes in the oral cavity associated with diseases of haematopoiesis and vessels	94
	Diseases associated with the red blood cells	94
	Diseases associated with white blood cells	96
	Haemorrhagic disorders (bleeding diathesis)	98
	Vascular anomalies.....	99
6.2.2.	Changes in the oral cavity associated with diseases of heart and circulatory system.....	100
6.2.3.	Changes in the oral cavity associated with respiratory diseases.....	101
6.2.4.	Changes in the oral cavity associated with diseases of the GIT	101
	Crohn's disease (morbus Crohn)	101
	Ulcerative colitis (colitis ulcerosa)	102
	Celiac disease (gluten enteropathy)	102
6.2.5.	Changes in the oral cavity associated with diseases of the kidney	102
	Uremic stomatitis	102
6.2.6.	Changes in the oral cavity associated with metabolic and endocrine disorders	102
	Glycogenoses and mucopolysaccharidoses	102
	Diabetes mellitus	103
	Insufficient function of the thyroid gland (hypothyroidism)	103
	Increased function of the thyroid gland (hyperthyroidism)	103
	Increased function of the parathyroid glands (hyperparathyroidism)	104
	Primary hypofunction of the adrenal cortex (Addison's disease)	104
	Acromegaly	104
6.2.7.	Paraneoplastic processes	104
6.3.	Endogenous pigmentations.....	104
6.3.1.	Melanin pigmentations.....	105
	Melanin pigmentations caused by increased melanin production	106
	Melanin pigmentations in systemic diseases	107
	Melanin pigmentations caused by a local proliferation of melanocytes and nevus cells.....	108
	Melanin pigmentations with malignant proliferation of abnormal melanocytes	109
6.3.2.	Haemochromatosis	109
6.3.3.	Porphyrias	109
6.3.4.	Discolorations of vascular origins	109
7.	POTENTIALLY MALIGNANT LESIONS OF THE ORAL MUCOSA.....	110
7.1.	Leukoplakia	113
7.1.1.	Proliferative verrucous leukoplakia.....	114
7.2.	Erythroplakia (erythroplasia)	114
7.3.	Erythroleukoplakia	114
7.4.	Oral submucosal fibrosis	115
7.5.	Dyskeratosis congenita.....	115
7.6.	Chronic hyperplastic candidosis	115
7.7.	Oral lichen planus – atrophic and erosive forms.....	115
7.8.	Discoid lupus erythematosus (DLE) – atrophic and erosive forms.....	115

7.9. Epidermolysis bullosa	115
7.10. Syphilitic glossitis	116
7.11. Actinic cheilitis (cheilitis actinica, solaris, abrasiva)	116
7.12. Sideropenic dysphagia (Patterson-Kelly, Plummer-Vinson syndrome)	116
8. NOTES ON DIFFERENTIAL DIAGNOSIS OF ORAL MUCOSAL LESIONS.....	117
8.1 Pigmented lesions	117
8.2. White lesions of the oral mucosa.....	117
8.3. Red lesions of the oral mucosa	118
8.4. Erosions and blisters on the oral mucosa	119
8.5. Ulcerations of the oral mucosa	123
8.5.1. Ulcers affecting primarily the gingiva.....	123
8.5.2. Ulcers primarily affecting other sites than gingiva	124
8.5.3. Ulcers in specific inflammations	125
8.6. Lip inflammation (cheilitis)	125
8.6.1. Overview of the cheilitides.....	126
8.6.2. Painful corners of the mouth (stomatitis angularis).....	127
8.6.3. Melkersson-Rosenthal syndrome	127
8.7. Macroglossia and microglossia	128
8.7.1. Congenital anomalies of the size of the tongue.....	128
8.7.2. Acquired anomalies of the size of the tongue.....	128
8.8. Pathologies of the coating of the tongue	129
8.8.1. Pathologically increased coating of the tongue	130
8.8.2. Pathologically reduced coating of the tongue.....	130
8.9. Inflammation of the tongue (glossitis)	131
8.9.1. Overview of glossitis.....	132
9. DISEASES OF THE ORAL CAVITY/MANIFESTATIONS IN THE ORAL CAVITY ASSOCIATED WITH PATHOLOGY OF THE ORAL MUCOSA	133
9.1. Salivary secretion and its disorders	133
9.1.1. Saliva functions	133
9.1.2. Salivary secretion	134
Quantitative analysis of the saliva (Škach's test)	134
9.1.3. Salivary secretion disorders.....	134
Ptyalism (sialorrhoea, hypersalivation)	135
Hyposialia (hyposalivation).....	135
Xerostomia	136
9.2. Glossodynia and stomatodynia	137
9.3. Bad breath (foetor ex ore, halitosis).....	138

10. TREATMENT OF MUCOSAL DISEASES.....	139
10.1. General rules for treatment of mucosal diseases	139
10.2 New trends in the treatment of oral mucosal diseases	140
10.2.1. Ozone therapy	140
10.2.2. Laser therapy	141
10.2.3. Biological treatment.....	141
10.2.4. Other substances potentially useful in treatment of mucosal diseases	142
 ACKNOWLEDGEMENT	 143
 REFERENCES	 144
 APPENDIX	 148
 LIST OF FIGURES	 154
 LIST OF TABLES	 154

Foreword

The term “diseases of the oral mucosa” describes a diverse group of diseases of various etiologies and seriousness constituting an integral part of stomatology. The issues associated with the orofacial region however cannot be taken out of the context of other specializations as they are closely related to internal, ENT, endocrinology, haematology, rheumatic, dermatovenereology and other diseases. The dentist may often be the first physician noticing and possibly diagnosing a general, sometimes very serious, disease based on symptoms of the oral cavity. This textbook is primarily intended for students of dental medicine, it can also be useful for the students of general medicine whom it can help in clinical and field practice. The new edition reflects the improving knowledge of the etiopathological processes of individual diseases on the molecular level and the ever increasing range of diagnostic laboratory tests and/or therapeutic options. To allow interested readers an easy access to a deeper insight into the individual topics, new findings are cited directly in the text.

The textbook is adapted to the curriculum of current courses, which also determines its extent. The imagery is available to students in the electronic atlas. The individual chapters of the Atlas of Oral Mucosal Diseases are arranged in the same order as in this textbook and logically complement the textbook. Hence, we recommend the readers of this textbook to use both these sources when studying.

Authors

List of Abbreviations and Acronyms

ACE	angiotensin-convertase enzyme
ACTH	adrenocorticotropic hormone
AIDS	acquired immunodeficiency syndrome
ATB	antibiotics
C3a (C5a)	complement components
CHX	chlorhexidine
CMV	cytomegalovirus
CRP	C-reactive protein
Dif. dg.	differential diagnosis
DLE	discoid lupus erythematosus
EBA	epidermolysis bullosa acquisita
EBC	epidermolysis bullosa congenita
EBNA	Epstein-Barr virus nuclear antigen
EBV	Epstein-Barr virus
EEM	erythema exsudativum multiformae Hebrae
ELISA	enzyme-linked immunoassay
GIT	gastrointestinal tract
HBV	hepatitis B virus
HIV	human immunodeficiency virus
HLA	human leucocyte antigen
HSV	herpes simplex virus
IF	immunofluorescence
Ig	immunoglobulin
IL	interleukin
LE	lupus erythematosus
LLLT	low-level laser therapy
B-MALT	mucosa-associated lymphoid tissue lymphoma
MSH	melanocyte stimulating hormone
NSAIDs	non-steroidal antiinflammatory drugs
OLL	oral lichenoid lesion
OLP	oral lichen planus
PCR	polymerase chain reaction
PGE2	prostaglandin E2
PNC	penicilin
PTT	partial thromboplastine time

PUVA	psoralen and ultraviolet A photochemotherapy
RA	rheumatoid arthritis
RAS	recurrent aphthous stomatitis
RIA	radioimmunoassay
RTG	X-ray
sine	without (therapy)
SLE	systemic lupus erythematosus
TBC	tuberculosis
TNF-a	tumor necrosis factor alpha
Th.	therapy
TTC	tetracycline
UV	ultraviolet
VCA	virus cellular antigen
VZV	varicella-zoster virus

1. Notes on the morphology of the oral mucosa

The thorough knowledge of both macroscopic and microscopic structure of tissues at physiological conditions is necessary for being able to assess pathological changes of the oral mucosa. Fig. 1 shows the structure of individual segments of the oral mucosa compared mutually and with the skin. The principal features distinguishing the mucosa from skin include:

- 1) **colour** – the mucosa is pink in the areas with the keratinized epithelium (which is caused both by the thinner layer of the *stratum corneum* and by a higher degree of blood supply) while the red colour is more intense in the areas with incomplete cornification.
- 2) **moisture** – caused by the saliva secretion.
- 3) **absence of skin appendages**

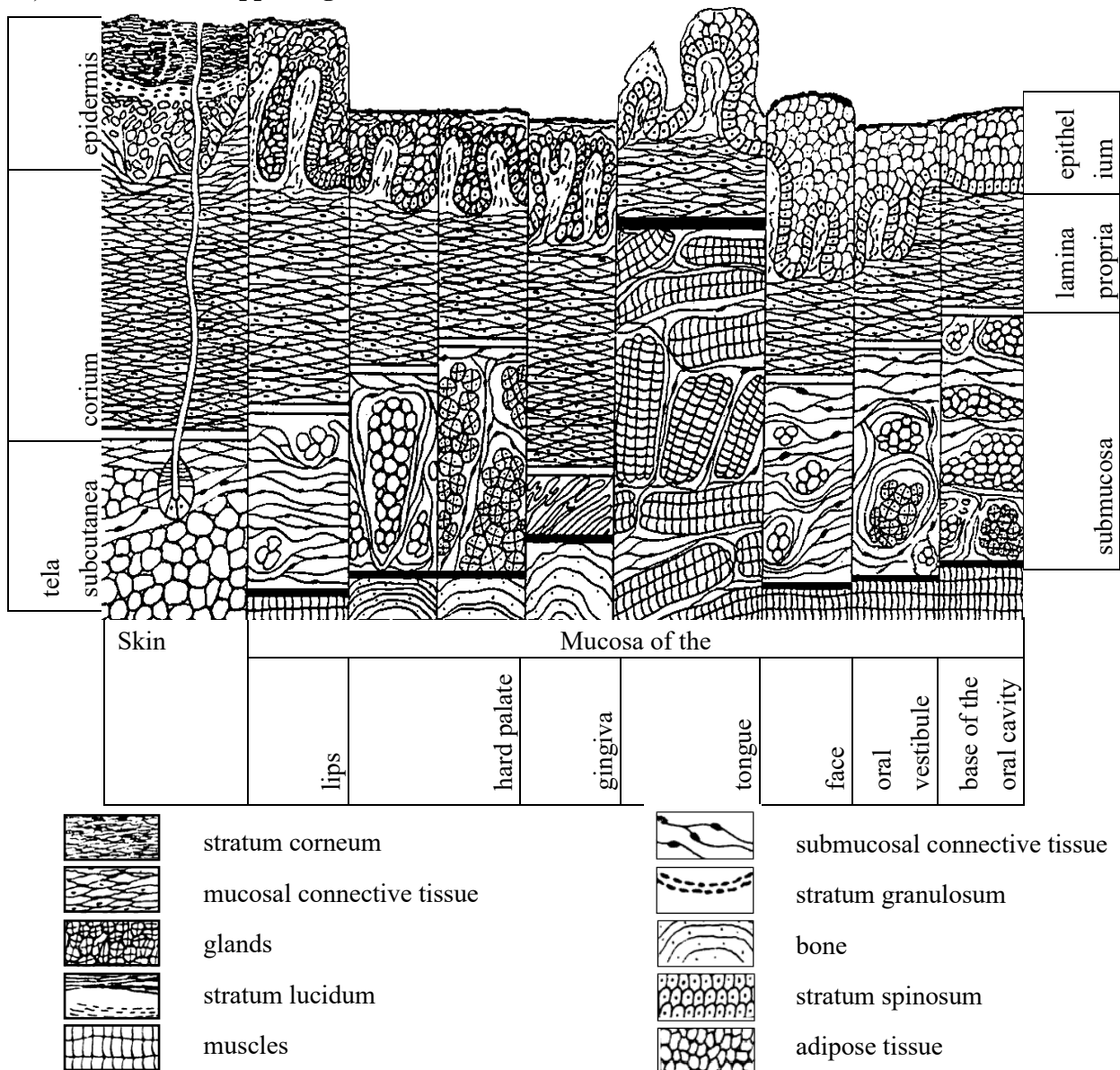


Fig. 1: A schematic view of the microscopic structure of the skin and oral mucosa (Škach et al., 1982)

From a topography point of view, the oral mucosa can be divided into several regions that correspond with the anatomy of jaws and attached muscles. The following types of the mucosa are recognized: buccal mucosa, labial mucosa, alveolar mucosa, palatine mucosa including the uvula and frontal palatine arches, the mucosa of the oral base and the tongue. The oral mucosa consists of stratified squamous-cell epithelium, the properties of which vary according to the function, i.e. to the load to which it is exposed (they differ in the presence or absence of the cornified layer on the surface of the mucous epithelium):

a) The **ortho-keratinizing epithelium** can be found on the hard palate, alveolar mucosa and attached gingiva; it has four layers – stratum basale, stratum spinosum, stratum granulosum and stratum corneum. Layers resemble the epidermis of the skin but are substantially thinner and the stratum lucidum is absent (Fig. 2).

b) The **para-keratinizing epithelium** covers the remaining parts of the oral mucosa (i.e., vestibular mucosa, buccal mucosa, soft palatine mucosa, sublingual region). It has two layers - stratum basale and stratum spinosum.

A specific position between the skin and the mucosa is attributed to the vermilion zone (also called lip red). Clinically, it resembles the oral mucosa while histologically, it resembles the epidermis with keratinization without the presence of most skin appendages (hair follicles, skin glands) and without the presence of salivary gland ducts.

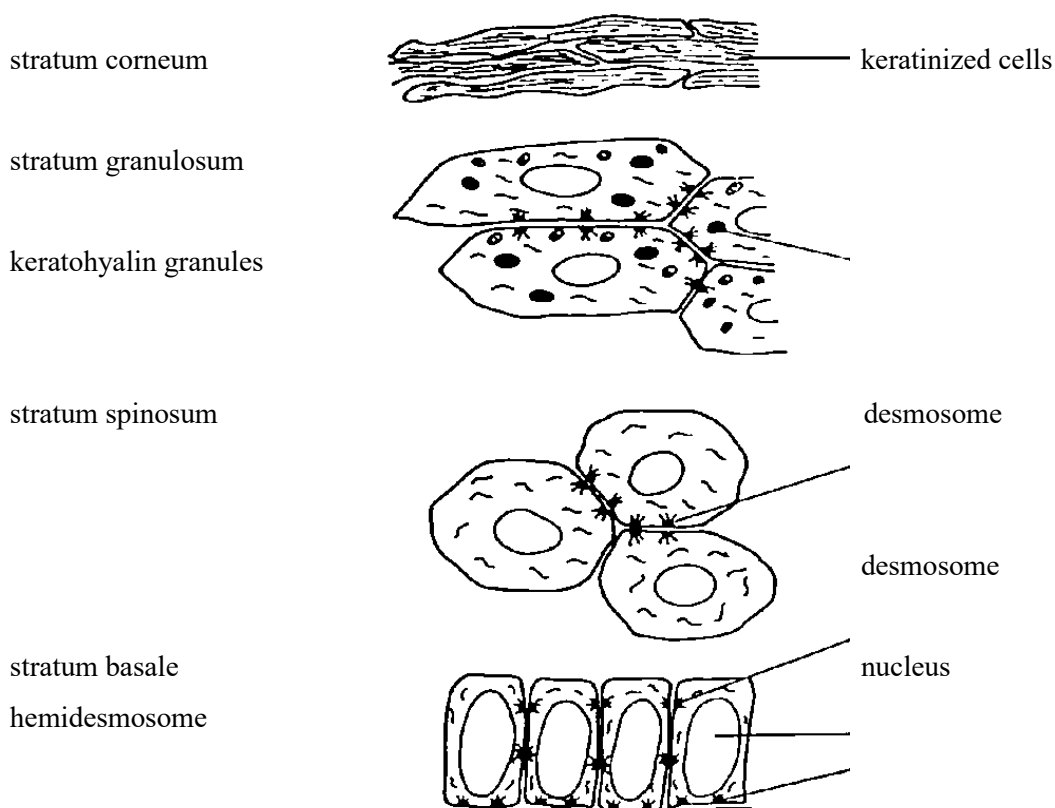


Fig. 2: An illustration of keratinizing epithelium (Tyldesley, 1981)

Other types of cells are present among epithelial cells (keratinocytes) in the basal layers of the mucous epithelium, such as melanocytes (forming and accumulating the pigment melanin) or Langerhans and dendritic cells (antigen-presenting cells) that are involved in immune reactions. The epithelium on the dorsum of the tongue forms duplicatures, i.e. **papillae** that can take several forms: filiform papillae, fungiform papillae, circumvallate papillae, or foliate papillae. Filiform and fungiform papillae form the basis of the physiological coating of the tongue; foliate papillae are predominantly located along the side of the tongue whereas circumvallate papillae are located on the border between the body of the tongue and the root of the tongue, accommodating taste receptors.

The cells of the stratum basale are attached to the basement membrane (Fig. 3). This fibrous membrane is located between the epithelium and lamina propria mucosae. It is folded in various ways – depending on the height of the papillae of lamina propria and the depth of the rete ridges. The density of interdigitation (the interlocking of epithelial and fibrous parts) determines the mechanical resistance of the mucous membrane. The lamina propria mucosae consists of a thin collagen tissue penetrated with elastic fibres, cellular elements (fibroblasts, fibrocytes, histiocytes, heparinocytes), blood and lymphatic vessels and nerve endings, which gradually turns into the submucous fibrous tissue (except for the dorsum of the tongue where it is firmly attached to the lingual aponeurosis (aponeurosis linguae) or into the periostal ligament (the alveolar process, hard palate). The submucous tissue contains tiny (minor) salivary glands (serous, mucinous or mixed) practically in the entire oral mucosa; those glands permanently produce small amounts of saliva, thereby keeping the oral mucosa wet and lubricated.

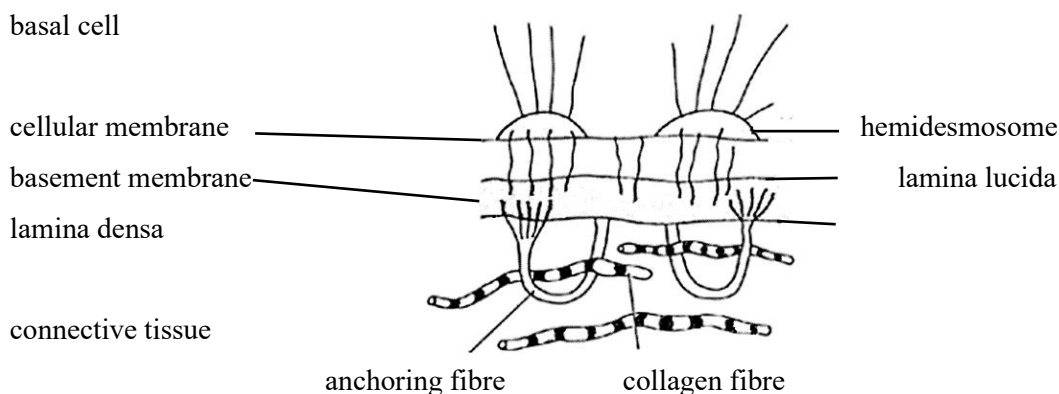


Fig. 3: A simplified chart of the basal complex of the oral epithelium: connection of basal cells and connective tissue by means of hemidesmosomes (Tyldesley, 1981)

Generally, the following three types of oral mucosa can be distinguished according to the function of individual segments:

- 1) Specialized mucosa: the dorsum of the tongue
- 2) "Functional" (masticatory) mucosa: palate, attached gingiva
- 3) "Non-functional" (lining) mucosa: remaining parts of the oral cavity

2. Principles of patient investigation

Various manifestations can be brought about by harmful factors. When establishing the diagnosis of a disease of the oral mucosa, one has to take into account the general variability of pathological processes, the individual response of a particular individual and – last but not least – the specific features of the oral environment, which characterize a particular disease but can also lead to diagnostic uncertainty (morphea maceration in wet conditions, difficulty in finding the blister roof due to mastication, etc.). In order to establish the exact diagnosis, it is necessary to take into account the distribution of lesions and their clinical appearance as well as the patient history and the results of additional tests (histology, serology ...).

Patient examination includes:

- 1) Patient history
- 2) Objective finding
- 3) Additional tests
- 4) Specialist examinations and consultations

2.1. Patient history

Taking the patient history is an indispensable part of any examination. The procedure is identical with that used in other medical fields –it includes the family and personal history and detailed questioning regarding current diseases. As for the present diseases, the following pieces of information are collected: **when** the disease manifested and **how long** it has been present, how it is associated with external and internal factors, what is the intensity of the local and general symptoms. The talk usually starts with the following questions: when did the disease first appear, how long has it lasted, and did it occur for the first time or repeatedly.

Recurrences are typical of recurrent aphthae whereas seasonality is characteristic e.g. for erythema exsudativum multiformae Hebrae (EEM) one however has to take into account that the presenting patient may only have his/her first attack of the disease. Subsequently, possible links are investigated – the patient often recalls some facts only after a targeted question (e.g. consequences of a dental treatment such as stomatitis caused by cotton wool swabs used for drying out the mucosa, allergic reaction after the use of a new product – cosmetic products, toothpaste, etc.). Information on the speed of the development of symptoms is also important – the treatment of acute symptoms must be initiated quickly whereas in case of chronic problems, it is usually possible to wait for results of additional tests.

The subjective information about **pain** – be it spontaneous pain or pain induced by a stimulus – is also very important since it is usually typical of acute conditions. Contrary, painlessness is

a typical feature of some diseases (syphilis, carcinoma), although an inflammatory modification is possible (for example secondary infection).

Bleeding is another symptom occurring when the integrity of the mucous surface is affected, especially obvious where vessels have been afflicted. It may also be a sign of serious changes in the blood count (leukemia, agranulocytosis, thrombocytopenia or thrombocytopathy) or occur as a result of some medications (anticoagulants, antiaggregants, etc.).

Mouth odour (foetor ex ore) is another frequently examined symptom accompanying the diseases of the oral mucosa. It can be a non-specific symptom of poor hygiene (which may represent the etiological cause or just patient's efforts to avoid pain). A typical sweetish odour is usually associated with necrotic mucosal decomposition (e.g. in ulcerative gingivostomatitis or leukaemia-associated necrosis).

The **disorders of salivation** – hyposalivation or hypersalivation – may also accompany oral mucosal diseases. Xerostomia is usually associated with fever, being typical of the Sjögren, Mikulicz or Felyt syndromes. They may occur at dehydration of different origins, atherosclerosis, after the use of some medication or radiation therapy. Hypersalivation usually occurs at acute inflammations of the oral mucosa (herpetic gingivostomatitis, epidemic stomatitis) or heavy metal poisoning.

General symptoms preceding the symptoms in the oral cavity may also represent a part of the clinical picture of the disease (for example prodromes during herpetic gingivostomatitis). At other times, they may represent an individual disease reducing the systemic immunity and thus indirectly affecting the findings on the oral mucosa (herpes simplex after getting chilled). If parallel to local symptoms, the general symptoms can indicate a potentially serious general disease (necroses associated with acute leukaemia) or a metabolic disorder (candidiasis in diabetic patients).

2.2. Objective findings and methods of examination of the oral cavity

Easy access is the main advantage. Visual inspection should always include palpation in order to identify any unevenness of the surface, the consistency and size of formations, the mobility and relationship to the surrounding tissues, and pain. The examination should proceed at perfect lighting. Attention is paid to the face as a whole, the oral cavity, tonsils, nasopharynx, as well as the submandibular and cervical regions. The examination of the oral cavity starts systematically with the lips and mouth corners, followed by the vestibular region, dental arches including the marginal periodontium, the dorsum and base of the tongue, the base of the oral cavity, buccal mucosa, hard and soft palates and palatine arches with the uvula and the outlets of large salivary glands. Any changes in the mucosa are examined, paying attention to the colour, thickness, and moisture of the mucosa, the presence of mucosa-associated efflorescences, and the localization and extent of any affliction.

The **colour** of the mucosa shows both racial and individual variations. Normally, the mucosa has a light pink colour; in patients with anaemia, the mucosa is paler, white colour is typical of hyperkeratosis and leukoedema whereas red (erythematous) mucosa is characteristic of inflammations. Sometimes, physiological or pathological pigmentations can be found.

Mucosal **thickening** (hyperplasia) can typically occur as a consequence of chronic tissue irritation, tumour growth or hormonal disorders. In other cases, **atrophy** (reduction) **of the mucosa** is found, most commonly associated with deficiency conditions (Fe and vitamin B or oestrogen deficiency) or some autoimmune conditions. The physiological atrophy of the mucosa often occurs at older age.

Moisture may be subject to change due to various pathophysiological conditions; the healthy mucosa is always wet. Reduced moisture or complete dryness can occur most frequently at Sjögren and Mikulicz syndromes, at dehydration or after the use of certain drugs, such as atropine.

2.2.1. Histopathological changes

The microscopic picture of mucosal diseases in the oral cavity is only rarely sufficient for diagnosis on itself. In most cases, it can only help classify a particular pathological condition in a certain group of afflictions. Additional diagnostic methods are then usually needed for establishing the exact diagnosis. The schematic view of basic histopathological changes is depicted in Fig. 4:

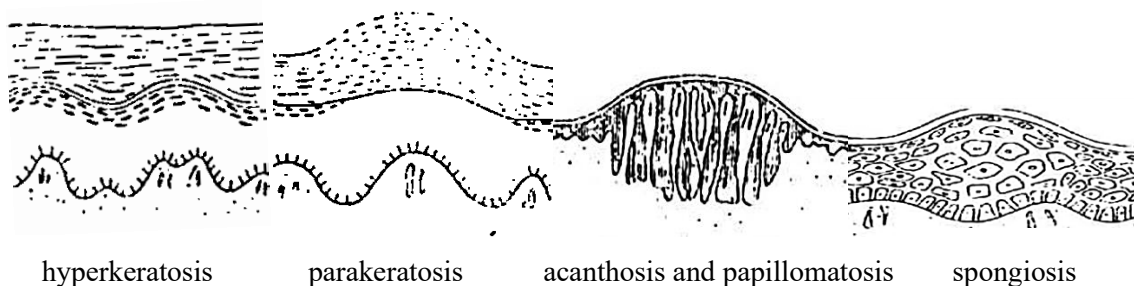


Fig. 4: The schematic view of basic histopathological changes (Záruba et al., 1992)

Hyperkeratosis is a simple thickening of the keratinized layer (stratum corneum); the remaining layers can be thinner, normal or thickened as well. Hyperkeratosis can result from various processes. It clinically manifests as a white patch.

Parakeratosis means imperfect keratinization, which is characterized by the presence of persistent nuclei in the stratum corneum, whereby the layer is thickened, just like in the case of hyperkeratosis. Again, it clinically manifests as a white patch.

Dyskeratosis is another keratinization defect manifesting as premature keratinization of individual epidermal cells, with characteristic corneal granules and bodies formed in their plasma. It

is a premalignant change of the epithelium with changes of nuclei, in cell polarity, and presence of mitotic figures.

Acanthosis is a thickening of the epidermis due to pathological multiplication of the cells of stratum spinosum. It is usually accompanied with the extension and enlargement of interpapillary spikes. It may occur together with or without hyperkeratosis. Acanthosis is a common pathological reaction to various stimuli.

Spongiosis is a term used to describe the intercellular oedema with increased intercellular space in the epithelium and prominent intercellular bridges in the stratum spinosum (e.g. in pemphigus).

Hydropic (vacuolar) degeneration develops as a consequence of intracellular oedema and cell degeneration in the stratum germinativum where the cell nuclei are replaced with empty space. The whole cells gradually degenerate and the border between the epithelium and connective tissue is difficult to distinguish (e.g. in lichen planus).

Acantholysis is a process characterized by the dissolution of desmosomes that results in „loosening“ the cells and in the increase in the intercellular space. This in turn leads to formation of intraepithelial blisters (typical of pemphigus).

Epithelial atrophy is manifested by the loss of various layers of the epithelium (particularly of the stratum spinosum). It can develop as a result of several different processes (inflammations, trophic changes).

2.2.2. Morphology of mucosal manifestations

All diseases of the oral mucosa manifest themselves morphologically by visible lesions that can be divided into primary and secondary efflorescences.

Primary efflorescences (Fig. 5):

Macule (spot) is a circumscribed red area at the level of the mucosa of various shapes and sizes. It can be either isolated or occur in groups, possibly with individual spots merging together. Erythema covering a larger area of the mucosa is called **enantheme** (scarlet fever, drug-induced allergies).

Papule (bud) is a small, circumscribed bulge, varying in size and shape, protruding above the surrounding mucosa. Papular eruptions are usually multiple, their colour on the oral mucosa is usually whitish or white-grey. Oral lichen planus (OLP) is a typical manifestation within the oral cavity.

Tubercle (bulge) is actually a large papule, such as a lipoma.

Vesicle (blister) is a small (up to 5 mm), circumscribed, elevated lesion that is, unlike a papule, filled with fluid. A large blister (5 mm to several cm) is called **bullae**. The contents of the blister is usually clear, the thickness of the blister's roof depends on the location (subepithelial

blisters have a thicker roof than intraepithelial blisters). It occurs in the oral cavity during viral infections such as herpetic infections or in blistering diseases such as pemphigus (intraepithelial blister), pemphigoid (subepithelial blister), EEM, or Dühring's dermatitis herpetiformis (subepithelial blister).

Pustule is a vesicular lesion that is – unlike the vesicle – filled with pus (causing a yellowish discoloration). It occurs e.g. during varicella.

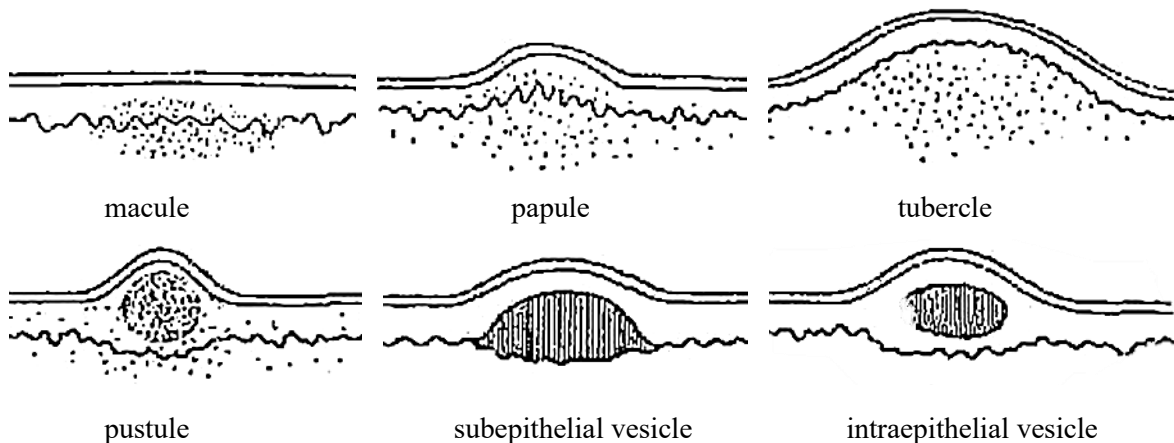


Fig. 5: Primary efflorescences of the oral mucosa (Záruba et al., 1992)

Secondary efflorescences (Fig. 6):

Crack (crevice) results from a rupture of the mucosa. It is most common in the corners of the mouth, on the lip or on the tongue. A deep, bleeding crevice is called a **fissure**.

Erosion is a mucosal defect characterized by the loss of superficial layers of the epithelium (not including stratum germinativum). It is probably the most common mucosal efflorescence. It can be painful but it heals without scars (e.g. minor aphthae). **Aphtha** is a specific efflorescence of the oral mucosa. The primary manifestation is a blister; its roof is however lost soon and an erosion develops, the base of which is covered with fibrin. The erosion is surrounded by a red, erythematous halo. It often occurs after a mechanical injury or may result from the loss of the blister's covering in a bullous disease. Sometimes, it may be covered by a pseudomembrane on the mucosa or by a crust on the skin.

Squama (scale) is a flattened plate of the superficially cornified layer that easily separates from the mucosa during hyperkeratosis; it affects the lip red or the skin.

Crust (scab) is a dry exudate on the skin or on the lip red. It does not occur on the mucosa.

Eschar is a result of skin necrosis caused by chemical or thermal burning, after frostbites or as a result of trophic disorders. Initially, the necrotizing tissue is whitish, then turns grey or black. It is sloughed off by circumscribed inflammation, leaves an ulcer behind that heals with a scar.

Ulcer (ulcer) has a deeper loss of tissue than an erosion – the base of the ulcer consists of connective tissue and fibrin with the infiltration of polymorphonuclear leukocytes. It always leaves

a scar. The edges of the ulcer can be distinct or jagged, elevated or depressed, hard or soft. It is usually round, although linear ulcerations may also occur as a result of mechanical or chemical injury. Like erosions, ulcers can also result from blistering diseases (pemphigus, pemphigoid, major aphthae). The pain depends on the etiology (painless ulcers are associated with carcinoma, syphilis!).

Tumour is a local swelling of the tissue including the mucosa of various sizes. It is a typical symptom of carcinoma, neoplasms or tumour-like lesions, such as pyogenic granuloma.

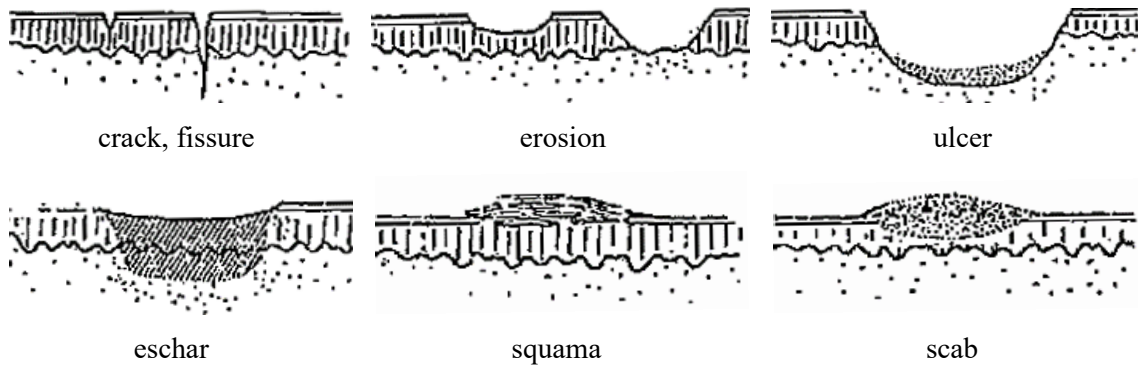


Fig. 6: Secondary efflorescences of the oral mucosa (Záruba et al., 1992)

2.2.3. Location and duration of mucosal manifestations

Besides the type of manifestations present in an individual, the location of the lesion also plays an important role in establishing the diagnosis. For example, eruption of vesicles in the rear part of the oral cavity and oropharynx suggests a possible herpangina whereas the affliction of the gingiva and mucosa in the frontal part of the oral cavity can be a typical symptom of herpetic stomatitis. The presence of vesicles and bullae on the labial mucosa suggests erythema multiforme, which usually also manifests elsewhere in the oral mucosa. The shape and arrangement of efflorescences can also have a diagnostic value (linear, herpetiform, follicular, multiform). The time of the onset (or recurrence) of clinical symptoms can help in diagnosis (e.g. recurrent aphthous stomatitis).

2.2.4. The examination

During examination of the oral mucosa, it is crucial to prevent any transmission of contagious diseases (Hepatitis B, HIV, etc). For example, clinical manifestations of HIV may only appear a long time after the contact with the virus and not even laboratory tests are for a certain period (3-6 months) fully reliable. For these reasons, we always abide by the rules ensuring the protection of the healthcare personnel from disease transmission during the performance of their duties as well as protection of patients from the hospital-acquired infections. The basic hygienic regulations must be adhered to during any examination, protective gloves and surgical masks/face shields must be used.

HIV transmission is similar to that of Hepatitis B virus (HBV), the latter is however much easier to transmit. In addition, HIV is very susceptible to heat and most common disinfectants. Adhering to the rules for prevention of HBV transmission therefore provides a sufficient protection from HIV infection as well, no additional measures are necessary. Patients with HIV infection can be hospitalized and examined at any healthcare provider or be clients of social services (see the Guidelines on the Issues of HIV/AIDS infection in the Czech Republic – Ministry of Health of the Czech Republic, 2016).

The examination begins at the **lips** where the symptoms of various diseases can manifest either on the cutaneous (common skin diseases) or on the vestibular part of the lips (mucosal diseases). The vermilion zone is a transitional tissue that is particularly prone to changes, e.g. during fever (dry lips, formation of crevices). The normal labial mucosa is pink, a pale colour is usually associated with poor circulation or anaemia whereas the blue-red colour (cyanosis) is typical of a number of congenital cardiac abnormalities, intoxications and cardiac insufficiency. Blisters and crusts (during infections – particularly herpetic infections) or hyperkeratosis (lichen ruber planus) are the most common symptoms found on the lips. The examination of mouth corners is important as it often reveals painful mouth corners with cracks, macerated skin and crusts.

The **gingiva** is examined next. The healthy gingiva has a light pink colour, turning red if inflamed or pale in the case of anaemia. Epithelial desquamation – scaling of the superficial epithelium – can also be present, with patches of exposed connective tissue that bleed easily (a typical sign of desquamative gingivitis, pemphigus, pemphigoid, OLP). Bleeding of the gingiva is one of the most common problems in patients with acute or chronic inflammations of the gingiva (most cases, approx. 90 %, are plaque-induced gingivitis); severe bleeding can however occur at gingival inflammation concomitant with serious general diseases. Pain is another serious symptom associated with acute inflammations (ulcerative gingivitis). In chronic inflammations, pain is usually induced (during teeth cleaning, eating, etc.). The condition of the periodontium must be examined thoroughly in order to distinguish true and false pockets (gingival hyperplasia may conceal serious general diseases such as haemoblastosis or tumours).

Subsequently, the tongue shall be examined, focusing on the tongue size, the condition of the tongue edges and tip. The surface of the mucosa of the tongue dorsum depends on the presence of papillae, coating, colour and moisture. Erosions, inflammations of the orifices of salivary glands or leukoplakia (hyperkeratosis) are often found on the floor of the oral cavity.

The **vestibular and buccal mucosa** often show inflammatory symptoms or hyperkeratosis (oral lichen planus and leukoplakia). On the **palatine mucosa**, herpetic or allergic changes or hyperkeratosis can be observed.

2.3. Additional laboratory tests

Such tests are instrumental for diagnosis of some diseases to verify the diagnosis or to differentiate between conditions the etiology of which is not clear from the clinical picture. They are also important for establishing the sensitivity of the pathogen on the treatment agents (antibiotics, antimycotics, etc.).

2.3.1. Haematological tests

It is necessary to perform such tests in patients with symptoms of acute infectious stomatitis (caused for example by the herpes virus) that are severe or prolonged, in ulcerative gingivostomatitis or some other diseases to exclude any potential serious general disease. Routine tests such as erythrocyte sedimentation, complete blood count, differential count of white blood cells and/or CRP test are performed. When indicated (angular cheilitis, glossitis), the full red blood cell count is supplemented with the determination of plasma iron and iron-binding capacity values as well as that of ferritin (an iron-containing storage protein). The basic haemocoagulation tests (thrombocyte count, Quick test, aPTT = activated partial thromboplastin time) shall carried out in cases where coagulation disorders are suspected.

2.3.2. Immunological tests

The complete immunological examination should be performed in patients with oral mucosal diseases such as chronic forms of oral candidiasis and recurrent infections caused by herpes viruses, or recurrent aphthae. An examination for autoantibodies is necessary if Sjögren syndrome or other autoimmune diseases are suspected. This examination should also always be performed before administering medication affecting the immune system at the general level (immunosuppressants, immunostimulants).

2.3.3. Biopsy

Biopsy often plays a key role in differential diagnosis in patients with chronic or recurrent conditions of unknown origin. Histopathological or immunofluorescence tests of the excised sample help distinguish diseases with similar symptoms (for example chronic hyperplastic candidiasis from leukoplakia). A diagnostic excision is also performed when an abnormal intraoral manifestation of a disease that does not normally affect the oral mucosa (for example primary TB ulcer) is suspected. A biopsy of the mucosa is also necessary to confirm the diagnosis of "hairy" leukoplakia and all blistering diseases.

The physician must be aware of the circumstances and conditions for performing a biopsy. Contraindications include acute viral diseases of the oral mucosa, ulcerative gingivitis, bleeding disorders, suspected hemangioma or malignant melanoma. The extent of the excision and the site of biopsy are of key importance. Efforts during the diagnostic excision should always be made

to collect the entire pathological formation. When the affliction is large, a typical part of the suspected tissue should be collected together with the adjacent healthy tissue. The procedure is usually performed at local anaesthesia; the sample collection should be performed very gently, without traumatizing the tissue unnecessarily. This can be for example done by placing an auxiliary stitch into the collected sample to prevent the forceps from bruising the collected tissue. The mucosa is not disinfected prior to the excision. The patient must be properly instructed about the nature of the procedure and possible postoperative complaints or complications.

The excised tissue is usually placed in a 10% formaldehyde solution. The sample of the tissue (including the shortened stitch) is placed on a gauze square to facilitate orientation during the histopathological examination. A properly filled-in dispatch note must be attached to the specimen. Staining is usually performed using haematoxylin and eosin; special staining techniques may be needed in some cases. In order to distinguish blistering diseases and to confirm the diagnosis of lichen, an examination of non-fixed tissue by the direct immunofluorescence method is necessary to prove the presence of autoantibodies bound to the target tissue (usually, an assay for circulating antibodies using the indirect immunofluorescence method complements this test).

2.3.4. Microbiological examination

Microbiological examination is used for direct or indirect determination of the causative agent of the particular infectious disease. It also serves for establishing the sensitivity to ATBs. In the everyday clinical practice, it is recommended that the physician agrees the medium to be used and the method of sample transfer with the laboratory that would perform the examination prior to taking the sample. A direct determination of the infectious agent (microscopically, by cultivation) is often impossible (for example due to secondary infections/changes in symptoms). For this reason, indirect (serological) methods are frequently used to prove the presence or absence of specific antibodies or microbial antigens.

Virological examination

Isolation of viruses and detection of viral antigens

For successful isolation of the virus, the following conditions have to be met:

- a) the collection of the specimen must be performed as soon as possible after the onset of the disease (within 2-3 days).
- b) the specimen shall be collected from the site with the highest assumed release of the virus.
- c) the specimen must be stored and transported at a suitable temperature (+4° C).
- d) the dispatch note must be filled in correctly and the respective test tube with the specimen must be labelled properly. It must contain the patient's name and surname, birth identification number, health insurer, diagnosis, the date of the sample collection, of the onset of the disease, and the name of the physician who performed the sample collection.

The isolation of the virus is performed using living cells, usually in-vitro cultivated cell cultures (other species such as laboratory mice or chicken embryos can also be used but they are quite expensive). The viral antigen is visualized using labelled, (preferably) monoclonal antibodies binding to it. Depending on the method of labelling, antibodies can be detected either by fluorescence or by the enzyme-linked immunosorbent assay (ELISA). Nowadays, molecular biological methods are used for accurate diagnosis, such as in-situ hybridization or polymerase chain reaction (PCR). The principle of the PCR method is that the selected piece of DNA is amplified across several orders of magnitude and the obtained product can be analysed for the presence of specific sequences of bases (for example for the presence of typical viral segments).

Indirect evidence of viral infections

This method is based on identification of the presence of specific antibodies in the patient's serum. In order to be able to interpret the results, one must know the principle and the dynamics of the formation of these antibodies. Out of the five existing classes of immunoglobulin antibodies, IgM and IgG antibodies are the most useful for diagnostic purposes. IgM antibodies are produced first, their production only lasts for a limited period of time and stops within a few weeks. The presence of IgG antibodies reaches the maximum level only several weeks after infection (and may remain lifelong for some infections, making it possible to see whether an individual has had a particular infection in his/her life).

Specific antibodies can be monitored using various methods. The complement-fixation reaction (CFR) is, compared to the methods mentioned below, relatively less sensitive. Its main disadvantage is the need for collection of two samples from a patient approx. 2-3 weeks apart in order to follow the dynamics of changes.

The immunofluorescence method is a more advanced and accurate method. It is based on the principle that some stains emit light after being exposed to UV radiation. If the fluorescent substance is bound directly to a specific antibody and thus used for a direct evidence of the antigen, we speak of direct detection; indirect immunofluorescence requires the use of two antibodies – one (of human or animal origin) reacting to the target molecule and the other, carrying the fluorophore, binding to the first antibody. Enzymatic methods such as ELISA utilize antibodies labelled with an enzyme; after binding to an antigen and washing, the enzymatic activity is measured and is directly proportional to the concentration of the antigen. Another method, radioimmunoassay (RIA), utilizes radiolabelled antibodies for the detection of the target antigens.

Bacteriological examination

Cultivation methods are typically used both for recognizing the responsible bacterial pathogen and to determine its sensitivity to antimicrobial therapy.

Aerobic and anaerobic cultivation

As the collection of the biological material is nowadays performed simultaneously for both aerobic and anaerobic microorganisms, protection of the material from the contact with air oxygen is a necessary prerequisite for successful cultivation. It is therefore recommended that the sample should be collected (ideally in the morning on an empty stomach) by means of a smear from the afflicted area of the mucosa using a sterile cotton swab. The swab is then placed on the bottom of a test tube containing a semi-solid transport medium (on rare occasions, it is transported in a test tube containing CO₂). Cultivation is then performed on bacteriological media selected depending on the particular (assumed) infectious agent (blood agar, End medium, Fortner medium for anaerobes, etc.). It should be pointed out that anaerobic cultivation is usually much longer than that of aerobic bacteria. The identification of some causative agents such as gonorrhoea (*Neisseria gonorrhoea*), tuberculosis (*Mycobacterium tuberculosis*) and other infections requires the use of special media.

Microscopic examination

As an example of microscopic examination, it is possible to mention dark-field microscopy for diagnosing the first stage of syphilis where serum reactions are still negative.

Serological examination

This type of examination is important e.g. when syphilis is suspected; specific serum reactions are used to diagnose the second and third stages.

Mycological examination

Similar to the bacteriological examination, it is used to verify the clinical diagnosis and determine the sensitivity of (usually) yeasts to the antimycotic therapy. Smears are performed with the above-mentioned precautions. Cultivation is usually performed on the Sabouraud agar with the addition of antibiotics to suppress bacterial contamination.

2.4. Specialist examinations and consultations

Consultations with experts in other specializations is necessary when:

a) **a well-founded suspicion on an underlying non-dental disease** is present, requiring a confirmation of the diagnosis and suggestion or approval of the suggested treatment.

b) **in the case of diagnostic quandary** – even if the attending physician has good knowledge and adheres to good practices of patient examination, the oral mucosa may exhibit symptoms whose cause is too difficult to determine or classify.

The specialist consultation component may also include an examination by a more experienced dentist or specialist.

The most common consultations called for by dentists include a dermatology examination (SLE, pemphigus), ophthalmology (Sjögren syndrome, Behçet disease), neurological (glossodynia,

neuralgia), allergological (drug-induced exanthema, Quincke's oedema), or haematological (anemia, haemoblastosis) examination, a consultation with an expert in ENT or rheumatology (necessary in Sjögren syndrome), or, if need be, a general examination by a specialist in internal medicine.

The request for consultation should contain a full detailed description of so far performed treatment steps and administered medications (due to a possible change in the clinical picture resulting from the use of medication) including a brief patient history and a suspected diagnosis.

3. Common anatomical abnormalities of the oral mucosa

3.1. Linea alba

Linea alba is an elevation of the buccal mucosa running at the level of the occlusal line from the mouth corner to third molars. Clinically, it manifests as a bilateral linear elevation of a normal mucosal or slightly whitish colour with normal consistence upon palpation. It occurs more frequently in obese individuals in whom the oral mucosa can be slightly compressed and adapted to the shape of the occlusal line of teeth.

Th.: Removal of the mechanical irritation

3.2. Fordyce spots/granules (morbus Fordyce)

Fordyce disease is a developmental abnormality characterized by the occurrence of heterotopic sebaceous glands in the mucosa of the oral cavity. Clinically, it manifests as multiple small, slightly elevated, whitish-yellow well circumscribed granules (only rarely accumulating and forming plaques). They occur most commonly on the mucosal surface of the upper lip, in commissures and on the buccal mucosa bilaterally and symmetrically attached to the molars. It is a relatively common finding and occurs in both genders. They are asymptomatic and although they can become more noticeable with increasing age, they should not cause major concern.

Th.: Without therapy

Dif. dg.: OLP, candidiasis, leukoplakia

3.3. Leukoedema

This abnormality is a harmless anatomical variation of the oral mucosa caused by the increased epithelial thickness arising due to an intracellular oedema in the stratum spinosum. It usually occurs bilaterally and can be most commonly found on the buccal mucosa, more rarely on the labial mucosa or tongue. Clinically, the mucosa has opalesque or whitish-grey discoloration and slightly wrinkled appearance that disappears when manually stretching the buccal mucosa. During palpation, leukoedema has a normal consistency and should not be mistaken for leukoplakia or oral lichen planus.

Th.: None.

3.4. Physiological melanin hyperpigmentations

Melanin hyperpigmentations of the oral mucosa are usually a chance finding during the dental examination. They are not usually associated with subjective problems. Melanocytes of the oral mucosa usually do not produce melanin as such, regions of a darker discoloration (**melanoplakia**) can be however a relatively common finding in dark-skinned persons (racial pigmentations) as in melanocytes of these individuals, bigger melanosomes with a higher activity can usually be

found. The pigmentations are usually diffuse, symmetrical, localized especially on gingiva and buccal mucosa, often appearing during childhood.

Physiological pigmentations also present as **freckles (ephelides)** caused by an increased production of melanin after exposure to sun in fair-haired people with a low phototype. They manifest as multiple brown spots in the solar localization (face, vermillion zone), usually from the childhood.

Th.: Not necessary in physiological pigmentations

Dif. dg.: Increased deposition of dark pigments in the oral mucosa can be a symptom of many diseases. It is necessary to differentiate it from heavy metal deposits (amalgam tattoo inks, metallic pigmentations), drug-induced pigmentation, melanin pigmentations in Addison's disease and Peutz–Jeghers syndrome, pigment nevi, lentigo maligna and malignant melanoma.

4. Congenital and developmental abnormalities of the oral mucosa

Congenital anomalies of the oral cavity arise as a result of disturbances during the embryogenesis. Lips, gingiva, hard palate, floor or oral cavity or tongue – all these organs can be affected. Most anomalies are detected at birth, some can nevertheless only be noticed later, at the infant age.

Congenital anomalies of the lips include cleft lip, double lip, congenital fistulas and lip pits (recesses and paramedial sinuses), which can be mucus-secreting.

Many congenital malformations of the tongue are extremely rare, such as aglossia (missing tongue), microglossia (congenitally small tongue), ankyloglossia (lingua accreta, tongue tie), cleft tongue (lingua bifida) or double tongue (diglossia vera).

4.1. Cleft lip

Cleft lip is a developmental abnormality affecting usually the upper lip, often in combination with cleft jaw and cleft palate. The cause is an incomplete adhesion of the jaw and nasal processes of the upper jaw during the embryonic development. The cleft can be both uni- or bilateral, complete or incomplete. The fusion of individual parts of the upper lip takes place later during embryogenesis than in the lower lip, which is the reason for the upper lip being more prone to this defect.

Th.: Complex, depending on the severity of the anomaly.

4.2. Double lip

This abnormality can either have a congenital etiology or can be acquired as a result of an injury. It manifests as a hypertrophied mucosa on either lip, which can protrude especially while speaking or smiling.

Th.: Surgical correction.

4.3. Bifid uvula/hypoplasia of the uvula

Bifid uvula is a congenital cleft of the uvula, often considered the slightest form of cleft palate. Hypoplasia of the uvula means that the uvula is insufficiently developed; if it is missing completely, we speak of aplasia. All these congenital abnormalities can occur isolated or as a part of certain syndromes.

4.4. Ankyloglossia (lingua accreta, tongue tie)

Ankyloglossia is a relatively rare congenital abnormality in which the frenulum of the tongue is short or attached close to the tip of the tongue. The frenulum is in such cases usually strong and fibrotic. Tongue mobility and function are affected which results in difficulties when swallowing and talking.

Th.: Surgical.

4.5. White sponge nevus (Cannon disease, naevus spongiosus albus)

White sponge nevus is a rare autosomal dominant hereditary disease with which the child is born or which first manifests during childhood. It progresses until early adulthood and then stabilizes.

In this disease, the oral mucosa is affected by white or white-grey efflorescences with multiple furrows and a "spongy" surface. Lesions are usually symmetrical, occurring most frequently on the buccal mucosa but possibly occurring anywhere in the oral cavity. Some patients also show similar symptoms on the vaginal or rectal mucosa. Histologically, this disease manifests as mucosal hyperplasia with local hydropic epithelial degeneration.

Th.: Not necessary.

Dif. dg.: When differentiating among the diseases with white mucosal lesions, family history combined with the manifestation of the problems in childhood and histological examination are keys to identifying the disease.

4.6. Darier disease (hereditary follicular dyskeratosis)

Darier disease is a rare autosomal dominant hereditary disorder affecting predominantly males. The symptoms manifest during childhood or adolescence. Typically, the disease affects skin and nails, mucosa (oral, rectal, genitals) can however also be affected.

The disease manifests as multiple, brownish-red papules on the skin that usually combine to form large areas. The oral mucosa is affected in 20-40% of patients. The extent and severity of the disease of the mucosa in the oral cavity depends on the activity of the disease on the skin. In the mouth, typical lesions appear as small white papules, which may combine to form larger areas and be hypertrophic.

Th: Vitamin A and retinoic acid derivatives are used for therapy.

4.7. Geographic tongue (lingua geographica, glossitis migrans)

Geographic tongue is considered to be a developmental abnormality. It may occur at any age approx. in 2-10 % of the population. Familial occurrence is common; it usually occurs together with plicated tongue (lingua plicata). Clinical signs include vast red patches on the mucosa of the dorsum of the tongue. Some patients experience enhanced sensitivity of the tongue when eating some foods (citrus, spices).

Red patches of various sizes are forming and rapidly changing, spreading centripetally into the surrounding physiological coating of the tongue. Their formation is associated with a complete loss of all 3-4 keratin hairs of filiform papillae, which is preceded by excessive keratinization (macroscopically, it looks like a focal whitish thickening of the mucosa) and by prominent desquamation of the squamous-cell epithelium of hair-like prominences covered with bacterial

colonies. Spongy papillae are preserved and visible inside the patches. Such red foci can be circumscribed with white margins along their perimeter where the above-mentioned process is proceeding, thereby spreading the depapillated patches into the surroundings. In several hours or days, the filiform papillae restore quickly and red patches disappear completely. The tendency to recurrence is high. Besides familial occurrence, infectious, psychogenic and neurohumoral factors play a role.

Th.: Not possible, the patient must be instructed about the nature of the disease

Dif. dg.: It is important to distinguish the geographic tongue from the onset of atrophic glossitis. The main differences are:

Geographic tongue	Atrophic glossitis (smooth tongue)
· Smooth patches are changing quickly	· Smooth patches are changing very slowly
· Spontaneous reversibility of changes	· The changes do not regress spontaneously
· Constant changes	· Changes usually progress up to the development of the full picture of the smooth tongue
· The surface area of the unaffected parts of the tongue is normal	· The papillae are also changed on other parts, fissures, erosions or petechiae may be present
· The transition of papillae has usually circumscribed, often rolled margins	· The transition of papillae into smooth areas is fuzzy
· Most common in children and young individuals	· Most common in adults and elderly individuals
· General examination is usually negative	· Anaemia, metabolic disorders or the use of medication are often found during the general examination

4.8. Fissured tongue (l. plicata/ gyrata/scrotalis/cerebriformis/fissurata)

This disorder counts among the anomalies with unknown etiology. It is an abnormality in the structure of the dorsum of the tongue, sometimes associated with a general enlargement of the tongue (macroglossia) characterized by the presence of symmetrical grooves and elevations determined by muscle fascicles (resembling cerebral convolutions). Changes are usually asymptomatic and mostly stationary and may sometimes progress with age. Some individuals experience enhanced sensitivity and burning of the tongue of various intensities, particularly while eating (and often after the intake of alcohol).

Th.: Therapy is not possible, it is important to instruct patients properly about the harmlessness of changes (the possibility of cancerophobia).

Dif. dg.: It may sometimes occur together with other diseases such as syphilis, TB, or OLP. Combined with facial nerve paralysis and granulomatous cheilitis, it constitutes the Melkersson-Rosenthal syndrome.

4.9. Crenated tongue (impressions on the sides of the tongue)

This term describes changes on the lateral edges of the tongue, which are probably caused by indentations of the adjacent teeth. The oral mucosa in the area of crenation is usually without visible changes, although erythema, erosions, enlarged lingual papillae and whitish edges in the vicinity of the indentations may occur. In such cases, the mucosa is also sensitive or even painful. We can also find changes on the buccal mucosa (linea alba, repetitive biting). Where the condition causes discomfort, it is beneficial to grind off the sharp cusps of the teeth traumatizing the edge of the tongue or to make a protective occlusal splint.

5. External causes

Development of any disease (be it an oral mucosal disease or any disease in general) always combines the provoking causes on the one side and the susceptibility of the individual (i.e., the given organism's reaction) that depends largely on his/her genetic predispositions and actual health condition. The etiology of various diseases of the oral mucosa varies – the causes differ in their quality (power), quantity and length of exposure, they can combine or even show synergistic effects. The causes can be classified as local and general or internal and external.

External factors include in particular physical (mechanical, thermal, radiation and electrogalvanic), chemical (toxic) and infectious (viral, bacterial, fungal) causes. While infectious agents may be external, the reaction of the organism still depends on the condition and individual immune reaction of the organism.

5.1. Physical factors

a) **mechanical** – in the sense of injuries to the mucosa (sharp edges of carious teeth, dental tartar, defective prosthesis) that can be acute or chronic.

b) **thermal** – the effect of heat (burns – caused by hot food or dental treatment) or cold, caused by the patient himself or the attending physician.

c) **irradiation** – ultraviolet rays (only concerns lip red), X-ray radiation overdose (or even therapeutic doses), penetrating radiation during accidents of atomic emitters.

d) **electric current** – it can damage tissue in the oral cavity either during an accident (giving rise to extensive necroses that heal with difficulty) or due to the galvanic irritation.

5.1.1. Traumatic changes of the oral mucosa

There are various mechanisms of injury of the oral mucosa causing acute or chronic changes. Long-term inflammatory changes causing a permanent chronic trauma can become precancerous.

Traumatic ulcer

It is the most common ulcer on the oral mucosa resulting from mechanical irritation. If resulting from pressure irritation caused by a denture, we speak of decubitus or pressure ulcers. It usually presents as a flat or dish-shaped ulceration with distinct margins. Defects can occur anywhere in the oral cavity – the respective location depends on the traumatizing factor. The most common sites are the lateral side of the tongue, the buccal mucosa, lips or gingiva. It is painful, the surrounding area is erythematous and can be covered by a greyish pseudomembrane. Patients report severe pain; regional lymph nodes can be swollen. The ulcer develops due to the traumatization of the oral mucosa – most commonly caused by unsuitable dental prosthesis (decubitus ulcer), carious or destructed teeth with sharp edges or hygienic dental tools; the causes may however include

orthodontic apparatus, surgical splints, tools used in dental treatment or externally applied drugs. In most cases, the causes of such defects can be easily recognized and proved both clinically and based on personal history of the patient; in some patients, however, it can only be established indirectly or with difficulties.

Neurodystrophic ulcer of the oral mucosa

The neurodystrophic ulcer develops in patients who were given local anaesthetics (usually mandibular) who injure the (at the time insensitive) oral mucosa by their own teeth. Typical sites include the mucosa of the lower lip and vestibule. Lesions have ulcerative character and are very painful; informing the patient after administering the anaesthetic is helpful in preventing this problem.

Traumatic gingivitis/stomatitis

This problem results from long-term deliberate or unintentional damage (including self-injury) of the oral mucosa and gingiva. Typically, such injuries are caused by hygienic dental tools but other objects may be also at fault. Clinically, we observe an erythematous mucosa with erosions. Petechiae can be also present, ulcerations can develop at a later stage.

Epulis fissuratum (denture hyperplasia)

It appears in the vestibular region in patients with a poorly fitting dental prosthesis. It manifests as a hyperplastic fold of various extents with erythematous mucosa and possibly a pressure ulcer. It forms in the vestibulum of the edentulous alveolar process in places of long-term mechanical irritation of the tissue by a flange of an ill-fitting denture. It is usually not associated with any subjective problems.

Th.: Traumatic defects of the oral mucosa cannot be successfully (i.e., completely and permanently) cured without removing the provoking cause. Once the cause is removed, spontaneous healing of the mucosal defect should occur within 1-2 weeks, depending on the size, severity and location of the defect. In the keratinized areas of the mucosa (dorsum and sides of the tongue, hard palate), healing takes longer. Sometimes, it is necessary to change the patient's hygienic habits, eliminate unsuitable dental care tools and/or teeth cleaning technique. Healing can be augmented with mouthwashes, gels or mucoadhesive preparations with wound healing and antiseptic effects. Most frequently, herbal infusions (chamomile, agrimony, yarrow, sage, etc.) are used for this purpose. Of other antiseptics, CHX can be used. The treatment can be augmented with application of surface anaesthetics (especially before eating). Denture hyperplasia must be surgically removed.

Cheek and lip bite stomatitis (morsicatio buccarum et labiorum)

The reason for this problem is the bad habit of biting the buccal or lip mucosa with teeth. The clinical picture is characterized by epithelial damage in the respective area. The epithelium is „torn“, locally hyperplastic or desquamating. The finding is not always clear – when in doubt, histological examination is recommended (with this diagnosis, a chronic inflammation will be revealed). The prognosis is often problematic as it depends to a large degree on the patient’s cooperation.

Frictional keratosis

Increased production of keratin causes a whitish discoloration of the oral mucosa, i.e., keratosis. Microscopically, ortho- para- or hyperkeratosis can be distinguished. Frictional keratosis is caused by mechanical irritation (e.g. of gingiva when using a toothbrush incorrectly – hard bristles, horizontal method of cleaning).

Histology: No dysplastic changes can be found histopathologically, only a simple hyperkeratosis is present (i.e., this is not a premalignant lesion).

Th.: A biopsy is not necessary, long-term observation is however recommended. Keratosis can disappear after removing the provoking cause.

Dif. dg: Leukoplakia

Cotton roll stomatitis

This problem appears after an oral procedure when a cotton roll or swab used during the procedure sticks to the vestibular mucosa and when removed without appropriate care, it can tear away the surface layer of the epithelium.

Oral haematoma

A random one-time bite on one’s cheek or side of the tongue that injures a blood vessel and the blood gets into the submucosal connective tissue is the most common cause of oral haematoma. The appearance is that of a (usually) small round dark red spot, often slightly elevated.

Suction trauma of the palatal mucosa

This problem arises as a result of repeated application of positive and negative pressure on the mucosa. Those mechanisms probably lead to rupturing of small vessels in the submucosal connective tissue of the traumatized mucosa and to bleeding into the mucosa. Clinically, an enanthema is observed, i.e., red spots on the palatal mucosa, which are well circumscribed with small petechiae. Remaining parts of the mucosa remain normal. While taking the patient’s history, the etiology can be found if the patient is willing to disclose it. Healing usually does not last for longer than two weeks, no therapy is needed.

Common cheilitis (chapped lips, cheilitis simplex)

This term describes changes on the vermilion zone and border manifesting as drying and chapping of lips, the development of which is affected by multiple factors. Besides mechanical (usually unconscious) irritation such as biting or constant licking of lips, adverse effects of weather can play a role (sunshine, frost, wind). The lip red is too dry, epithelial desquamation occurs; sometimes, even small crevices are formed. It is recommended to moisturize the lips regularly and to prevent their traumatization and chronic irritation.

Exfoliative cheilitis (cheilitis exfoliativa)

Compared to the simple cheilitis, the exfoliative cheilitis is characterized by a greater (pathological) degree of keratinization of the vermilion zone; the changes may also spread periorally. In addition to the above mentioned causes, some chronic dermatoses (atopic or seborrhoeic eczema, ichthyosis). It occurs more frequently in persons breathing through their mouths, a contribution of mental stress is also expected. When the keratinized scales are torn away, crevices and fissures appear, even secondary infections (mostly in the corners of the mouth) or slight oedema can develop. The disease recurs frequently and its treatment is more difficult than in common cheilitis. It is necessary to prevent the chronic irritation and to support the healing with local preparations with antiseptic, keratolytic and wound healing effects. Sometimes, even a short-term application of corticoids is necessary.

5.1.2. Stomatitis caused by thermal factors

Burns can occur by accident due to random drinking hot beverages or eating hot meals, or due to carelessness during manipulation with some medical tools. Low temperatures (frost, snow) can represent the etiology, e.g. of frozen lips in skiers, etc. Depending on the temperature and duration of the exposure, the clinical picture can show various changes ranging from simple erythema with oedema to tissue necrosis with a subsequent development of an ulcer. A chronic exposure to heat may lead to hyperkeratotic changes. Damage due to low temperatures again depends on the intensity and duration of the exposure. Initially, it presents as a pale to livid discolouration, later as an oedema with ulcerative mucosal defects. Diagnosis is usually clear from the patient's description of the etiology.

Th.: The therapy is local, preparations with wound-healing and antiseptic effects are recommended.

5.1.3. Electrogalvanic stomatitis

The presence of various metals in metallic tooth fillings or prosthetic devices may initiate the development of electrogalvanic irritation with the metals acting as electrodes and saliva as an electrolyte. All substances that can be used as electrodes in a galvanic cell are ranked according

to their potential. The function of the galvanic cell depends on a difference between potentials of both metals. When two metals with similar potential (e.g. silver, platinum, gold) are both present in the oral cavity, the risk of developing a dangerous potential difference is much lower than where metals from further apart in the table are concerned (e.g. gold versus zinc or tin). This leads to development of various electric currents depending on the potential difference (voltage) and resistance of individual tissues (Ohm's Law). The manifestations of galvanism result either from the direct effects of the electric current (the tolerated, i.e., „no damage“ intensity is 10 microamperes, tolerable voltage is approximately 80-100 mV) or from electrolysis which leads (via ionization of tissue liquids) to decomposition of organic substances and irritation of the oral mucosa. This results in electrogalvanic stomatitis, which may produce both general (GIT symptoms, headache, joint pain) and local symptoms in the oral cavity. Patients usually report subjective problems such as tingling, burning or metallic taste. Objective findings reveal various changes ranging from erythema, erosion or ulcer to hyperplastic changes. Symptoms usually occur at the site of contact between each of the metal and the edge of the tongue or the buccal mucosa.

5.1.4. Actinic cheilitis (solar cheilitis, ch. actinica, solaris, abrasiva)

This type of cheilitis is a chronic damage to the vermilion zone occurring as a result of a long-term exposure to the sunlight (its UV-component). It mostly occurs in older people and especially affects the lower lip.

Clinical picture: First, a small oedema or erythema develops, the lip is dry; later, small scales begin to desquamate from the vermilion zone and erosions appear. Leukoplakia patches may appear in the vicinity. The condition is not constant, it improves and gets worse again over time.

Th: The treatment is difficult; in the initial stages, local preparations with wound-healing and antiseptic effects may improve the condition. A surgical removal of the lesion including histopathological examination is often necessary. Carcinoma develops in approx. 10 % of cases of solar cheilitis.

5.2. Chemical factors

Usually, this kind of injuries occur during accidents (drinking, spilling) or when the dentist is not careful enough. The oral mucosa is sensitive to burning both by acids and bases as well as by salts of heavy metals. This group of factors also includes the effects of some treatment agents applied locally (in the past, e.g. arsenic), or generally. The chemical factors contain among other things the effects of smoking and action of compounds formed by erosion of metals used in the dental practice.

5.2.1. Stomatitis due to corrosive substances (burning)

Those typically occur due to the accidents in laboratories, improper handling of the chemicals in the clinical practices, or as a result of harmful effects of chronic exposure to corrosive chemicals in the working environment. The action of acids or bases leads (depending on the concentration and duration of exposure) to the development of necroses of various depths that originally manifest as pale spots on the tissue. Acids cause a circumscribed delimited coagulation necrosis, the colour of the damaged mucosa depends on the used chemical (nitric acid- yellowish; hydrochloric acid – white; sulphuric acid – black. When the tissue is burnt by bases, the surface is usually greyish and mushy (liquefactive necrosis). When the necroses separate, painful ulcers appear that heal only with difficulty and leave scars. When chronic exposure occurs, damage to the mucosa of the eye and nose is the most prominent while on the oral mucosa, hyperkeratotic changes can be observed.

Th.: The most important rule is to neutralize the agent as quickly as possible. When the burn was caused by an acid, a 5% sodium bicarbonate solution is used while when the agent was a base, the best course of action is to rinse the mouth repeatedly by a solution of citric acid. If those (or similar) chemicals are not available, it is important to at least keep rinsing the mouth with water for 20 minutes. Other measures include protection from secondary infection and painkillers.

5.2.2. Toxic effects of xenobiotics

Xenobiotics are substances that are not formed in the human organism but possess pharmacological (medicines), endocrine or toxic effects affecting the organism. In the oral cavity, xenobiotics may affect:

- 1) the oral mucosa – lichenoid reaction, EEM, pigmentation, gingival hyperplasia and bleeding, mucositis and non-specific ulcerations (Fig. 7).
- 2) salivary glands – xerostomia, ptyalism, induration and/or pain in the salivary glands.
- 3) hard tissues – caries, discoloration of teeth, alveolitis, osteonecrosis of the jaw.
- 4) non-specific inflammations – changes in the taste perception, halitosis, neuropathy, motility disorders, infections.

Unwanted effects of medications may also cause variable mucosal and dermal changes. Various mechanisms can be involved in the drug-induced pathogenesis (general toxic effects, drug interactions, immunopathological effects, allergic, provoking an autoimmune disease).

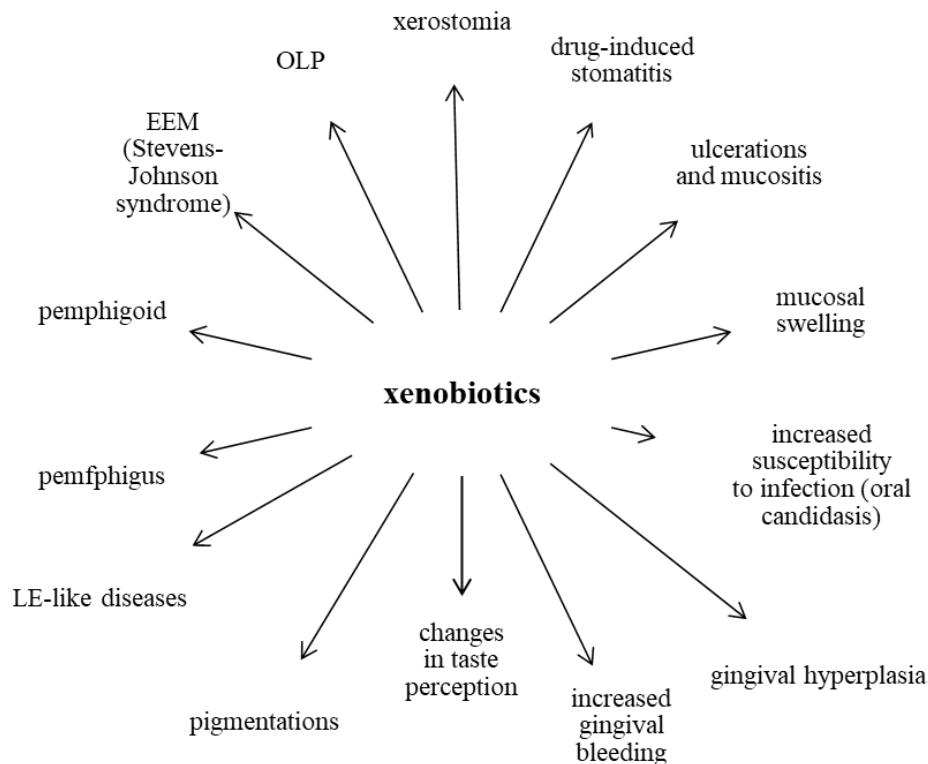


Fig. 7: Xenobiotics-induced diseases of the oral cavity

The problems can be provoked by an abnormally high drug dosage, although even therapeutic doses can elicit pathological processes. Complications after the use of ATBs manifesting as **dysmicrobia** (dysbalance of the microbial equilibrium of the digestive tract caused by ATB-induced destruction of the physiological microflora) is a typical example of such process. Dysmicrobia can subsequently facilitate the development of a **superinfection**, i.e., of proliferation of pathogenic microorganisms insensitive to the particular ATB (e.g. proliferation of yeasts after ATB therapy).

The method of the exposure to the xenobiotics also plays a role. A direct contact with the oral mucosa can cause local irritation, allergic reaction or other pathological processes. Drugs administered as inhalation preparations may lead to disorders of taste perception. Drug-abusing individuals (e.g. cocaine) can after a long-term oral or nasal application suffer with serious damage to the tissues of the oral cavity, even to perforation of the hard palate.

Swellings in the oral cavity can be caused e.g. by cardiac medications (ACE inhibitors), ATBs, barbiturates, NSAIDs. The symptoms usually appear within minutes to hours after administration of the respective drug. ACE inhibitors can induce a non-allergic intraoral swelling caused by a change in levels of locally released bradykinin. Although such swelling can be usually

observed during the first weeks of therapy, it is not uncommon that it only appears after a longer period of using.

Individuals taking multiple medications or their excessive doses have a higher risk of developing **drug-induced xerostomia** due to the synergistic effects of the active substances. Smoking, alcohol abuse and/or long-term usage of caffeine-containing drinks also add to the burden and affect the moisture of the oral mucosa.

Drug-induced gingival hyperplasia is a relatively common condition, usually manifesting 1-3 months after the initiation of the therapy with a new drug. First, it appears on the interdental papillae, especially frontally, a generalized affliction of the entire gingiva is nevertheless not uncommon. Typically, this type of gingival affliction results from the use of calcium channel blockers, cyclosporine or hydantoinates.

Drug-induced discolorations (pigmentations) of the mucosa can be caused by a direct stimulation of melanocytes to melanin production, by storage of pigmented drug metabolites, or by a combination of both. Usually, such pigmentation occurs in the centre of the posterior part of the hard palate, is bluish-black to brown and can be bilateral. During HIV treatment with antiretrovirotics, diffuse oral discolorations can occur. Pigmentations of the tongue (and hard dental tissues) was also observed after the use of tetracyclines.

Drug-induced stomatitis of toxic origin

In comparison to the allergic form of drug-induced stomatitis (see Chapter 6.1.1), the inflammatory component is less pronounced while tiny erosions and haemorrhages are more prominent. The symptoms are rather localized.

The physiological coating of the tongue is typically reduced or completely suppressed and the mucosa on the remaining islands (patches) of the coating on the tongue surface bears signs of hyperkeratotic changes. The diagnosis of drug-induced exanthemas can be facilitated by a parallel occurrence of skin problems. Reasons of toxic reactions may include too high dosage of the drug, reduced tolerance of the organism to the drug or accumulation of the medicine in the organism during long-term use. Mixed toxic-allergic manifestations combine symptoms of both types, the clinical picture therefore contain both inflammatory and non-inflammatory manifestations. Smooth tongue with inflammation can be observed, which however do not combine with hyperkeratotic manifestations. Tiny erosions in a certain area resulting from disintegration of the capillaries (arteriolitis) in the affected area are the most common manifestation. If larger vessels are affected, extensive necroses can occur.

Dif. dg.: It is especially difficult to distinguish this type of stomatitis from enanthemas associated with infectious diseases that may be almost indistinguishable from drug-induced stomatitis (a general examination usually helps as infectious diseases are typically associated with the alteration of the patient's general condition).

Th: The most important therapeutic step is, if possible, discontinuation of the respective medicine that is identified as the causal factor of the drug-induced stomatitis (which of course must be preceded by discussion with the attending physician).

Erosions and ulcerations: Some medicines used for treatment of myeloproliferation diseases may be toxic for the oral mucosa (e.g. methotrexate, daunomycin, cyclophosphamide, 6-mercaptopurine). Clinical manifestations include extensive painful erosions covered with fibrin pseudomembranes on the buccal, vestibular or labial mucosa, on the palate or pharynx that can become infected with candida. Severe dysphagia is often present. **Ulceration** or epithelial necrosis can also develop as a result of taking over-the-counter drugs (such as aspirin) and various antiseptics that are getting into a direct contact with the oral mucosa. Most commonly, labial mucosa is affected, followed by buccal mucosa and palate.

There is still a lot of controversy regarding drug-induced tumours. The use of strong immunosuppressants and/or their long-term use is likely to increase the risk of initiation and development of a malignant disease (Yuan a Woo, 2015).

Many drug-induced oral reactions may clinically, histopathologically and even immunopathologically resemble idiopathic OLP, EEM, pemphigus, pemphigoid or LE. Any site of the oral cavity may be affected, most commonly affected sites however include the buccal mucosa, lateral sides of the tongue and alveolar mucosa. Lesions can be either solitary or multiple.

OLP-like drug-induced reactions were originally described as reactions to antimalarial drugs; nowadays, however, cardiac medications are most commonly associated with this problem, along with NSAIDs and peroral antidiabetic drugs. Both lichenoid papuloreticular and erosive manifestations can be observed. In contrast with a bilateral occurrence in idiopathic OLP, drug-induced lichenoid reactions usually manifest by unilateral erosions.

Drug-induced EEM represents approximately 25 % of all cases of this affliction. Similar to the idiopathic or postinfectious (often with HSV etiology) cases, the disease has a quick onset with a variable clinical picture that can vary from lesions limited to the oral mucosa up to an extensive general affliction of the mucosae and skin all over the body. Drug-induced EEM is often associated with ATB therapy, antihyperuricemics and barbiturates. More serious forms of EEM include **Stevens-Johnson syndrome** and **toxic epidermal necrolysis** (Lyell syndrome) that are much more frequently drug-induced than „normal“ EEM and can be life-threatening.

Drug-induced pemphigus can take a form of pemphigus vulgaris or pemphigus foliaceus. Drugs inducing this problem usually contain a thiol bond. **Drug-induced pemphigoid-like reactions** may either manifest solely on the oral mucosa or affect also other mucosae and skin. Most commonly, they occur after derivatives of thiols and/or sulfonamides. Clinically, relatively large vesicles or bullae appear that have a tendency to burst and turn into extensive erosions and shallow ulcerations that are often covered by a fibrinous pseudomembrane. The gingiva is often affected by **desquamative gingivitis** with a notable erythema, erosions and epithelial peeling (of the vesicular roofs).

Drug-induced lupus erythematosus (LE) is a well-known adverse reaction that can arise following the use of more than 70 drugs, most commonly of procainamide, hydralazine, penicillamine and chlorpromazine. Erosions or ulcerative lesions can occur on the palatal or buccal mucosa as well as on the gingiva or alveolus.

Drugs known to induce diseases of oral mucosa, xerostomia or changes in taste perception are listed in the Appendix 1 (Kalmar, 2016).

5.2.3. Tobacco abuse-associated changes of the oral mucosa

Smoking represents the most harmful form of tobacco abuse (when compared with chewing and snuff). Several hundred substances have been identified in the tobacco smoke, many of which are toxic and carcinogenic for the oral mucosa. A parallel alcohol consumption further pronounces those negative effects. Over the last years, many studies reported adverse effects even of e-cigarettes on the oral mucosa (Bardellini et al., 2018). Although they do not contain tar-like substances formed during tobacco burning, their cartridges contain besides nicotine also many other chemical compounds.

Smoking-associated changes of the oral mucosa include smoker's melanosis and leukokeratosis that are considered benign. Leukoplakia (see Chapter 7.1) is another type of lesion, the occurrence of which can be associated with smoking – it is much more common in smokers than in non-smokers and is considered as precancerous lesion. The most serious disease developing due to smoking is the squamous cell carcinoma. Tobacco abuse also constitutes one of predisposing factors for development of oral candidosis and acute necrotizing ulcerative gingivitis.

Smoker's melanosis

This condition represents a melanin hyperpigmentation of the oral cavity in heavy smokers developing due to irritation of melanocytes by substances from the cigarette smoke (which stimulate melanin synthesis). It especially affects the vestibular part of gingiva, to a lesser degree also the buccal mucosa.

Smoker's leukokeratosis (stomatitis fumantium, leukokeratosis nicotinic palati)

It appears in some smokers as a result of a long-term tobacco abuse (especially of cigarette smoking), which leads to a chronic, toxic-mechanical irritation of the palatal mucosa. This in turn leads to a higher keratinization of the mucosal epithelium manifesting as whitish discoloration and inflammatory reaction of the salivary gland orifices both on the soft and hard palate. Those changes may also be a reason for development of small elevations – papules with a central dip or dots representing erythematous orifices of minor salivary glands. In case of smoking cessation, those lesions can disappear.

Histology: Histopathologically, no dysplastic changes are present, only a simple hyperkeratosis (not parakeratosis) is observed. It can however coincide with leukoplakia in smokers.

Th.: A biopsy is not necessary, a long-term observation due to a possible risk of development of leukoplakia or squamous cell carcinoma is however recommended. When removing the etiological factor, the hyperkeratosis can regress spontaneously.

Smoking related leukoplakia

Smoking related leukoplakia appears predominantly on the floor of the oral cavity and buccal mucosa in the region of corners of the mouth. The risk of malignant transformation is the highest in female smokers with lesions located on the inferior surface of the tongue or on the floor of the oral cavity (Slezák a Ryška, 2006).

Squamous cell carcinoma of the oral cavity

Smoking is one of the predominant etiological factors of this malignant epithelial tumour. In some patients, it may appear as a consequence of smoking-related leukoplakia, it is however more commonly formed „*de novo*“. Alcohol abuse in smokers significantly increases the risk of the carcinoma development.

5.2.4. Exogenous pigmentations

In this type of pigmentation, the pigment originates externally (Fig. 8). The discoloration of the dorsum of the tongue may be a result of some **pigment-containing foods** (liquorice), frequent use of **mouthwashes** (especially CHX-containing brands), **smoking** and **pigment-producing microorganisms** (that have proliferated during dysbiosis caused e.g. by some antibiotics). Some **medications** can also cause mucosal pigmentation. The mechanisms of action may include the aforementioned effects of ATBs on microbial balance, presence of metallic salts that may constitute a component of some drugs, or a direct deposition of insoluble pigmented complexes into the mucosa/bone.

Tattoo of the oral mucosa is caused by direct implantation of pigments into the submucosal connective tissue (pen or pencil injury, artistic tattoo).

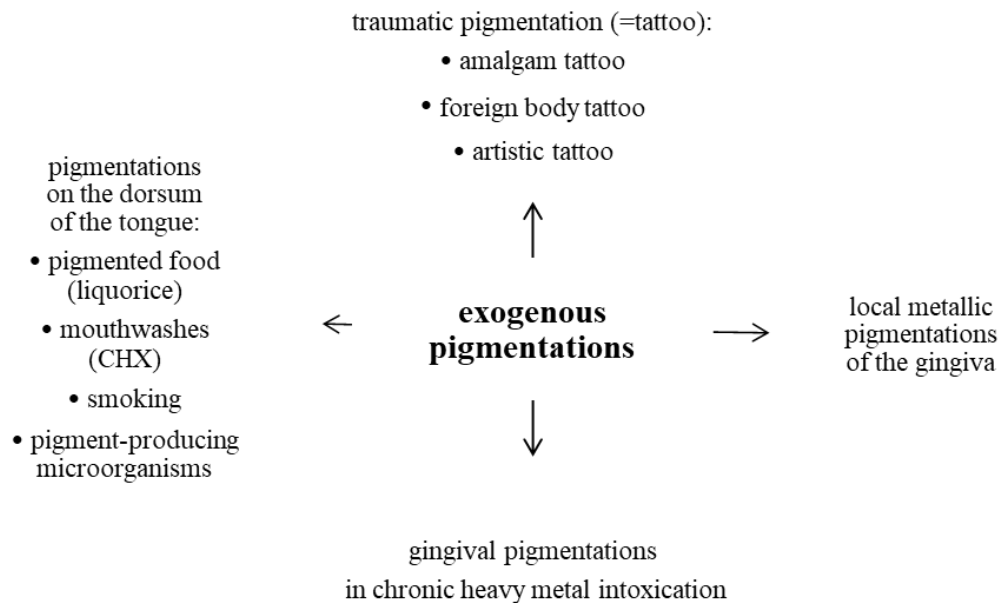


Fig. 8: Etiology of exogenous pigmentations

Amalgam tattoo

Amalgam tattoo is an exogenous pigmentation of grey-bluish-black colour developing after an injury of the oral mucosa (e.g. during tooth preparation with amalgam filling) leading to a subsequent incorporation of metallic particles into the tissue.

Metallic gingival pigmentations

Metallic gingival pigmentations result from corrosion of some metals used in dentistry in the region of the dento-gingival junction and they manifest as a grey-black line along the gingiva (in the cervical region), usually on the cervix of devitalized repaired teeth (metallic fillings, crowns, build-ups). A blue-greyish line along the gingiva is typical in chronic **heavy metal poisoning** (especially when associated with professional exposure due to the work without protective devices or due to the accumulation of drugs in the organism). During exposure to heavy metals, their derivatives are getting into the blood circulation and subsequently into the sulcular fluid. A site with a chronic inflammation (such as gingivitis) then represents a preferential site for precipitation of metal sulphides in the subepithelial connective tissues that in effect becomes pigmented.

Pigmentations caused by heavy metals and their salts

Heavy metals and their salts enter the organism and tissues most commonly orally, parenterally or traumatically.

Lead

Chronic lead poisoning is very characteristic. Lead binds to red blood cells (basophilic stippling of erythrocytes caused by lead (II) phosphate on their surface) and accumulates in all organs and particularly in bones. In the oral cavity, insoluble lead (II) sulphide forms a grey or blue-black margin on the gingiva which cannot be removed mechanically. Other symptoms include metallic taste in the mouth and increased salivation.

Bismuth

In the past, bismuth compounds were used in the treatment of syphilis. In the oral cavity, the chronic exposure manifested by the characteristic grey-blue discolouration of the marginal gingiva resembling mercury poisoning. Nowadays, bismuth intoxication is extremely rare.

Mercury

Mercury poisoning (mercurialism) also used to be relatively frequent during the syphilis treatment in the past. Nowadays, the exposure is typically due to inhalation of mercury vapours. In the oral cavity, stomatitis with increased salivation and a grey-blue discolouration of the gingiva is characteristic for this problem. Similar to lead, the patient may feel metallic taste.

Gold

Gold accumulates in tissues in particular where colloidal gold solutions have been applied parenterally for treatment of rheumatoid arthritis. A blue-violet discolouration of the gingival mucosa (chrysocyanosis) is typical of chronic gold exposure.

Silver

It enters the organism orally (e.g. when using colloidal silver) or as a component of amalgams or prosthetic metal alloys (Koldan, Aurix). Exposure to silver may result in argyrosis – a distinct grey discolouration of the skin and gingiva. Bluish hyperpigmentations also occur as a result of traumatic tattoo of the oral mucosa. The presence of the metallic material in the soft tissues can be proved by X-ray. It is important to emphasize that with the exception of completely clear and unambiguous cases of amalgam tattoo, any dark pigmentation of lips and oral mucosa must be histopathologically examined; this is especially true about the lesions present on the palate or the alveolar process of the maxilla.

5.3. Viral infections

5.3.1. Diseases caused by the „herpes simplex virus“

Herpes simplex virus is so common in the population that we can speak of an almost 100% rate of infection in the population. The primary infection usually occurs between the ages of 1 and 5 years. Two types of the virus are known – Type 1 (HSV-1) and Type 2 (HSV-2). The virus is transmitted through a direct contact with an infected person; Type 1 is usually transmitted via oral whereas Type 2 via genital secretions, the final distribution of the areas afflicted by both types

of viruses however is more or less the same. Following an infection with either HSV-1 or HSV-2 (whether manifesting clinically or not), the production of specific neutralizing and complement fixing antibodies begins within 1 week. Even so, the virus latently survives in the ganglia of sensory nerves and may cause recurrences in the skin and mucous membranes via the retrograde intra-axonal transport.

Primary herpetic gingivostomatitis

Herpetic stomatitis is the most common clinical manifestation of primary infection caused by HSV (particularly Type 1), particularly in children at the age of 1-5 years. The next wave occurs usually in adolescence and adulthood up to the age of 35 years. It is transmitted by direct contact or by airborne infectious droplets; the incubation period is approximately 7 days.

Clinical picture: The disease begins with the prodromal stage with non-characteristic flu-like general symptoms (fever, headache, cervical pain, backache, loss of appetite and fatigue). Within 2-3 days, those symptoms disappear and a generalized intraoral disease will develop, characterized with the typical eruption of multiple tiny intraepithelial blisters on the erythematous oral mucosa. Predilection sites include the gingiva (which becomes diffusely red and oedematous), the tongue dorsum and the mucosa of the hard palate. Changes in the palatal gingiva behind the upper incisors are very typical, major inflammatory hyperplasia of interdental papillae can be found.

Changes in the palatal mucosa in the region of molars can be observed in children with deciduous teeth. Blisters quickly merge and break to form very painful erosions and ulcerations. The tongue has heavy whitish coating – sometimes with a diagnostically valuable herpetic blisters or erosions on the tip and along the sides of the tongue. Hypersalivation is common as well as the indistinct mouth odour (foetor ex ore). The perioral affliction of the vermilion and facial skin is not a rule. Food intake, swallowing and sometimes pronunciation are impaired. Submandibular and superficial cervical lymph nodes are painful and swollen. The disease will usually disappear spontaneously in 7-10 days; erosions will heal completely (ad integrum). As an after-effect of the reduced oral hygiene during the outbreak (i.e. poorer oral hygiene due to the intense pain), plaque-induced gingivitis may persist. There are usually no early complications; patients with atopic eczema however may experience dissemination of the infection, with a clinical picture of eczema herpeticum Kaposi. Generalization of the complaints or neurological complications (meningoencephalitis) may pose a danger in immunodeficient individuals. The disease is recurrent in approx. 30% of patients, it however usually takes a form of herpes labialis (cold sores) or recurrent herpetic stomatitis.

Th.: The therapy is symptomatic – a diet of suitable consistency (pulpy, non-irritating) is recommended along with the sufficient intake of liquids. Before a meal, a mucosal anaesthetic can be applied, the oral cavity can be washed using herbal infusions, a 0.25 % solution of ZnSO₄ with virostatic and antiseptic effects (Zn²⁺ ions inhibit viral DNA-polymerase through a not yet been

fully elucidated mechanism) or 0.12 % aqueous solution of chlorhexidine. Antiseptics can only be used at prescribed concentrations and for a required period of time (otherwise, there is a risk of developing an undesirable dysmicrobia in the oral cavity). The frequency of washing varies (2-10x daily). The use of virostatics is usually not necessary, they are needed only in patients who are generally seriously ill. No surgical procedures can be performed in the mouth during the manifestation of the disease.

Dif. dg.: The following symptoms are very important for diagnosis: an acute diffuse gingivitis, usually with fibrin deposits and typical localization on the palatal gingiva behind the upper incisors; intense whitish coating of the tongue with tiny erosions along the sides and on the tip of the tongue; swelling of lymph nodes; and alteration of the general condition in the prodromal stage (which represents a difference from ulcerative gingivostomatitis). It is necessary to differentiate this disease from the first attack of erythema multiforme in the form of the Stevens-Johnson syndrome (which always affects the vermilion zone with symptoms including bleeding crevices and haemorrhagic crusts with the nasal apertures, conjunctivae, genitals and skin being also affected; general symptoms are however less expressed). Rarely, acute gingivostomatitis can occur during infectious mononucleosis (which however usually shows as a part of the general picture including pseudomembranous angina, hepatomegaly, typical changes in the blood count, and serological evidence of EBV). Enteroviral stomatitis does not affect the gingiva.

Pustulosis varioliformis (eczema herpeticum, Kaposi varicelliform eruption)

This serious form of primary infection caused by HSV can occur in atopic individuals (usually in infants) suffering with a generalized eruption of vesicles turning into pustules and subsequently in erosions or crusts. This is usually associated with the alteration of the general condition and accompanied by fever, fatigue or even affliction of internal organs (meningoencephalitis, pneumonia). Oral symptoms occur in 10-15% of patients who develop painful erosions in the mouth that are more severe than those associated with herpetic stomatitis.

Th.: General application of virostatic agents – acyclovir, symptomatic therapy, or gamma-globulin. Antibiotics can be administered for prophylaxis.

Dif. dg.: It is necessary to differentiate this disease from EEM that typically occurs at a different age and is usually associated with polymorphic cutaneous manifestations.

Recurrent herpetic stomatitis (intraoral herpes, stomatitis herpetica recidivans)

This collective term describes recurrent diseases of the oral mucosa after the formation of specific protective mechanisms – it is not a primary infection. It develops as a result of reactivation of a latent HSV infection; this form is a less common clinical manifestation than herpes simplex (labialis). The causes of reactivation are not usually established.

Local prodromal symptoms (burning, pain) may or may not precede the eruption of blisters; headache may occur in some cases. The disease usually affects the keratinized sections of the oral mucosa (gingiva, hard palate, tongue dorsum). The blisters are usually not detected since their roof peels off quickly and they turn into erosions that are very painful and tend to merge. The lips can also be affected. The surrounding mucosa is erythematous and swollen; regional lymph nodes are usually not affected. Spontaneous healing takes 5-10 days, complications usually only occur in predisposed individuals (oncological or immunodeficient patients) in whom a caudal propagation of the mucosal disease (pain during swallowing!), process dissemination and generalization are possible. The skin and mucous membranes of the genitals can also be affected. The frequency of recurrences varies.

Th.: The treatment is, just like in herpetic gingivostomatitis, local and symptomatic. In immunodeficient patients, acyclovir can be used. For prophylaxis of the recurrences, immunomodulators can be administered (transfer-factor, gamma-globulins – only after an immunological examination!).

Dif. dg.: Compared to the herpetic gingivostomatitis, the alteration of the general condition and a two-stage course of the disease are missing. Distinguishing this disease from the herpetiform type of recurrent aphthae can be difficult; those however do not have the tendency to combine and never affect the keratinized region of the oral mucosa (!). When suspecting an autoaggressive disease from the group of pemphigus/pemphigoid diseases, a biopsy and immunofluorescent examination are necessary.

Labial herpes simplex (herpes simplex labialis, herpes labialis)

This is the most common clinical form of activation of the latent HSV-infection in the orofacial region due to the virus persisting in the trigeminal ganglion (the Gasserian ganglion). It repeatedly affects the lips with a very variable frequency of recurrences. Many external and internal factors may be involved in the reactivation of the latent infection, such as UV-B radiation, trauma, fatigue, mental and/or physical stress, other viral infections or menstruation.

Clinical picture: In the majority of patients, the eruption of labial herpes is preceded by a short-lasting paresthesia at the site of the later manifestation of the disease. Shortly, an eruption of blister(s) appears in the vermilion zone of (usually) one lip. The erupted intraepithelial blisters merge and dry out to form tiny crusts, or break to form erosions. The affected part of the lip is red, oedematous and painful. Painful crevices can be formed in the region of mouth corners, causing difficulty while opening the mouth. The general alteration of the condition is absent. The affliction tends to heal spontaneously. Secondary impetiginization through the autoinoculation of streptococcal or staphylococcal infection of the herpetic manifestation may occur, particularly in children. The condition may deteriorate if the affected site is traumatized during dental examination.

Th.: Therapy should be initiated as soon as possible, ideally as soon as the prodromal stage! Local application of virostatics such as acyclovir (acyclic nukleosid inhibitor of viral DNA

polymerasis) is possible. The application can be associated with mild local irritation manifesting as erythema and paresthesis.

Dif. dg.: Differentiation from other lip-affecting diseases is usually not difficult. Recurrent aphthae do not affect the vermilion zone, pyoderma (folliculitis, furuncle) primarily affects the cutaneous part of the lip and their course and clinical picture are not interchangeable with HSV affliction.

5.3.2. Diseases of the „Varicella zoster virus“ group

Varicella (chicken pox)

Varicella is a very contagious disease caused by varicella-zoster virus (VZV) that also causes shingles. It affects predominantly children, with almost 100% manifestation in sensitive individuals, and is transmitted via the air-borne route or through direct contact. The clinical progression of the disease is usually mild (it can be more serious in adults), with symptoms including fever, eruption of blister exanthemas on the skin or enanthema on mucous membranes. The incubation period is 3 weeks. Since the eruption comes in waves, the picture is typically polymorphic; symptoms on mucous membranes usually precede the eruption of skin manifestations (morphoea) and usually prevail on the palate (hard and soft), lips and gingiva.

Dif. dg.: The presence of the blisters in the scalp is important for confirming the diagnosis. Intra intraoral efflorescences must be distinguished from all erosions-causing diseases. Especially in children, the disease is often of epidemic character – it is necessary to observe the epidemiological situation.

Th.: Therapy is only symptomatic.

Herpes zoster (shingles)

Herpes zoster virus is identical with varicella virus. Varicella is the primary infection, the virus (VZV) then persists in the spinal ganglions, maintaining the capability of reactivation. When spread via blood, it may induce a disease on the oral mucosa that closely resembles varicella, including the diseases of the skin of the head and body. The manifestations of herpes zoster at this stage are however less common on the head and neck and more common in the areas sensitively innervated by spinal nerves.

A secondary attack of the cerebrospinal ganglia of cephalic peripheral nerves is the starting point for a neurodermal viral disease. The disease manifests itself when the organism is weakened; symptoms include facial neuralgias with sensation disorders. Warning! The manifestation of zoster infection can be a paraneoplastic syndrome and may indicate the presence of malignancy!

In persons over 50 years of age, vaccination against the VZV reduces (by means of blocking the viral activation) the risk of both shingles and of post-herpetic neuralgias.

Herpes zoster of the trigeminal nerve (herpes zoster n. trigemini, zoster facialis)

This disease is caused by the reactivation of endogenous viral infection of varicella-zoster virus (VZV) persisting in the trigeminal ganglion (the Gasserian ganglion); the mucosa of the oral cavity can be affected if zoster symptoms are present in the cephalic region sensitively innervated with the 2nd or 3rd branch of the trigeminal nerve. Zoster facialis occurs in approx. 10-20 % of herpes zoster cases.

Clinical picture: Mild prodromes (fatigue, loss of appetite) are followed by neuralgic pain in the region of the affected nerve. In most patients, the oral mucosa is affected together with skin regions of the respective dermatome.

If the 2nd branch (maxillary nerve, n. maxillaris) is involved, herpetic efflorescences on the facial skin in the facial/cheek region (including the upper lip and the nasal wing) and in the temporal region occur. In the mouth, the vestibular mucosa (buccal, labial mucosa in the region of the upper lip and upper alveolus) and the hard palatine mucosa (the region of palatine nerves, nn. palati) are predominantly affected.

An affliction of the 3rd branch (the mandibular nerve, n. mandibularis) results in the eruption of blisters on the facial skin in the mental region including the lower lip, perimandibular and preauricular regions. The intraoral manifestations occur on the mucosa of the frontal two thirds of the tongue (along the lingual nerve, n. lingualis), the floor of the mouth, the lower lip and the alveolar process. Again, pain of various degrees of severity (or sensation disorders – hyperesthesia, paresthesia) occurs before the eruption of blisters. The skin shows dark red, maculopapular exanthema (enanthea on the mucosa), followed by the eruption of blisters that are covered with crusts when on skin or turning into erosions when on the mucosa. The affliction is usually unilateral and does not overreach the central line! After healing that usually takes 2-3 weeks, postherpetic pain refractory to therapy may persist.

Th.: Systemic application of virostatic drugs (acyclovir in sufficient doses!) Adjunctive painkiller therapy with local symptomatic treatment.

Dif. dg.: Herpetic stomatitis – frequent recurrences, mucosal manifestations do not reflect the innervation of individual areas of the oral cavity and cross the central line. The pain is usually less severe. Sometimes, it may be difficult to distinguish it from acute pain of odontogenic origin or from the essential trigeminal neuralgia; personal history, complex examination of the oral cavity including X-ray, neurological and ENT examinations help in differentiation).

Herpes zoster n. facialis (zoster oticus)

It occurs due to the reactivation of latent VZV infection persisting in the geniculate ganglion (ggl. geniculi) of the intermediate nerve (n. intermedius). Clinical symptoms are very variable, affecting skin and mucosal regions of the head, which are sensitively innervated by the facial nerve.

An affliction combining this disease with other cephalic nerves at the same time is called **Ramsay-Hunt syndrome**.

Zoster oticus occurs relatively rarely. Sometimes, it is preceded by prodromal symptoms such as otalgia with propagation into the regions of the neck, shoulder or chest, disorders of sensation in the area of the auricle and the external auditory canal. Intraoral symptoms are usually more extensive than skin symptoms, being localized in the frontal two thirds of the tongue (via chorda tympani) and on the soft palate. Mucosal symptoms (blisters or erosions) are very painful and make a food intake, swallowing and speech difficult.

The condition is often accompanied by facial plegia that causes additional problems such as motor disorders of mimic muscles and lagophthalmos. Symptoms disappear spontaneously in 14-28 days; the affliction of the facial nerve with motor disorders of facial muscles however often persists.

Th.: Same as the treatment of herpes zoster of the trigeminal nerve.

5.3.3. Epstein-Barr virus and cytomegaloviruses group diseases

Infectious mononucleosis (monocytic angina, Pfeiffer's disease)

The usual cause is EBV (the Epstein-Barr virus). It is most prevalent in younger people (teenagers). The infection is transmitted by saliva and is possible both from an infected individuals or from clinically healthy carriers. After the incubation period, the disease initially manifests through unspecific general symptoms (fever, loss of appetite, tiredness), followed rarely by an acute ulcerative gingivostomatitis (although some forms are clinically indistinguishable from the herpetic form) that can be accompanied by quickly disappearing petechiae on the soft palate (Holzer's sign) or by temporary facial oedemas (Bass/Hoagland sign). Subsequently, pseudomembranous angina develops, with coatings that may spread from tonsils into the surroundings. In some cases, only acute pharyngitis develops, accompanied by painful swallowing, oedema of the pharynx and larynx, and inspiratory stridor. Submandibular and painless cervical lymphadenopathy is always present. Some individuals also show enlarged lymph nodes in other parts of the body and/or hepatosplenomegalia. Neurological complications such as meningitis, meningoencephalitis, polyradiculoneuritis or organ-specific complications (hepatopathy, pancreatitis, nephritis) can also occur. The disease usually lasts relatively long and in some patients, it tends to chronicity.

Dg.: Blood count examination shows lymphocytosis with atypical lymphoid cells; the high count of monocytes (up to 50%) is typical as well as the positive Paul-Bunnell test and laboratory signs of hepatopathy. Virological examination is performed to detect antibodies against viral antigens VCA, EBNA; analysis of IgG and IgM antibodies against CMV-infection is sometimes also necessary.

Th.: The systemic therapy falls within the scope of specialists in infectious diseases; bed rest along with liver diet and intake of hepatoprotective products are of utmost importance. Only gradual return to normal activities is recommended. If an acute gingivostomatitis develops, local symptomatic therapy (anaesthetics, antiseptic mouthwashes) is recommended.

Dif. dg.: Streptococcal tonsillitis (angina lacunaris, lacunar tonsillitis) regresses after 2-3 days of ATB treatment and the enlarged tonsils are painful. Herpetic gingivostomatitis has a typical two-stage course of disease (the systemic complaints regress with onset of intraoral problems) and the pseudomembranous angina is absent. Herpangina is not accompanied by lymphadenopathy, the problems are usually less serious. Especially in children, it is necessary to differentiate with developing acute hemoblastosis with signs of acute pharyngitis or tonsillitis accompanied by the significant general alteration of the patient's condition (blood count!).

„Hairy“ leukoplakia

This manifestation of EBV infection is characterized by changes on the oral mucosa, most commonly on the tongue. It appears as fuzzy-looking white patches with an evenly arranged, folded mucous surface on the tongue's edges in the frontal two thirds of the tongue (pars oralis linguae). Leukoplakia can also manifest on the tongue's dorsum and apex. Sometimes, it can also occur on the labial, buccal or palatine mucosa where it however does not have the typical appearance (the folding of the mucous epithelium typical of the tongue is absent). The finding is usually permanent; it however may sometimes regress spontaneously or after therapy.

In HIV-positive patients, the occurrence of hairy leukoplakia indicates a poor prognosis and progression of HIV infection into the AIDS phase. In 80 % of HIV patients, this progression occurs within 30 months after the development of hairy leukoplakia.

Histopathology: Hyperkeratosis, acanthosis and ballooning degeneration of the epithelial cells of the mucosa with pycnotic nuclei in the stratum spinosum are observed. *Pseudohyphae* of *Candida* yeasts often grow into the superficial layers of the keratinized mucous epithelium. Eosinophilic inclusions (classified using PCR as the Epstein-Barr virus) can be seen in the epithelial cells.

Th.: Systemic virostatic treatment (acyclovir) is prescribed; where yeasts are found, antimycotic therapy should be also administered. Nowadays, however, the prevailing opinion is that it is not necessary to treat hairy leukoplakia unless the condition is causing the patient local subjective problems.

Dif. dg.: When developing on the sides of the tongue, it is necessary to distinguish it from relatively common changes caused by chronic trauma of the tongue (frictional keratosis), which usually bears signs of teeth impressions or changes caused by biting (the same can be true of buccal or labial mucosa). The tongue can be sensitive or even painful. The usual „smoker's“ leukoplakia can affect any part of the oral mucosa. Histopathologically, eosinophilic inclusions typical of hairy leukoplakia are absent. Lingua geographica in the stage of „healing“ of the epithelium can also resemble „hairy“ leukoplakia. Clinically, however, the picture quickly changes, typically within several days. The acute or pseudomembranous forms of oral candidosis can also resemble this condition; in candidosis, however, the symptoms are also present on other parts of the oral mucosa

and the vicinity of the white lesions is notably erythematous. Patients usually complain about burning sensation and pain.

Cytomegalovirus disease

The disease is caused by CMV; usually, it results from reactivation of a latent (endogenous) infection due to deficiency/failure of the immune system. It is therefore not a primary infection.

Clinical picture: Isolated or multiple defects sensitive to touch appear on erythematous mucosa – erosions to ulcerations of various diameters, usually only vaguely circumscribed. The most common site is the soft palate (including the uvula), followed by hard palate, gingiva, vestibular and lingual mucosa. They persist for several weeks and mostly, they heal spontaneously (albeit scars may sometimes remain). The disease can recur or be more extensive, affecting even the esophagus or more distal segments of the GIT.

Dg.: As neither the morphological picture nor localization are specific, the clinical diagnosis must be verified by histopathological examination (the presence of infected epithelium with „owl’s eye“ inclusions). Virological examination (a direct proof of viral DNA is preferred to that of specific antibodies).

Th.: Application of antiviral therapeutics is possible, it is however usually not necessary due to the high tendency to spontaneous healing. Local symptomatic treatment focused on relieving the complaints and supporting healing of the mucosal defects is recommended.

Dif. dg.: For therapeutic reasons, it is important to distinguish this disease from other mucosal defects such as erosions or ulcerations using targeted tests and examinations (histopathological, virological, bacteriological, mycological, etc.).

5.3.4. Enterovirus infections

Herpangina

This disease is caused by the Coxsackie A, Coxsackie B or ECHO virus. It usually affects children or young people, forming a kind of small seasonal (summer) epidemics disappearing within two weeks. The transmission of infection is possible both by a direct contact or via air-borne droplets. It usually presents as acute stomatitis with pharyngitis, usually with vague clinical problems (sore throat, headache, vomiting, diarrhoea, fever). In the oral cavity, small blisters or erosions are formed (usually well circumscribed, rarely merging) on the mucosa of the soft palate, tonsils and pharyngeal mucosa. Subjectively, the biggest discomfort is typically associated with swallowing.

Th.: Symptomatic local therapy focusing on reducing the subjective complaints – non-irritating food, sufficient hydration, antiseptic mouthwashes).

Dif. dg.: Hand, foot and mouth disease has skin symptoms in addition to the mucosal. Herpetic gingivostomatitis usually has a more serious course, the affected areas are bigger, affecting the gingiva and hard palate. In herpes zoster, the affliction is strictly unilateral (besides the skin and mucosal

symptoms, pain and sometimes neurological symptoms that may also occur are different) and it predominantly affects a different age category. Eruptions of petechiae on the soft palate in young individuals with tonsillitis that subsequently quickly disappear may indicate infectious mononucleosis.

Vesicular stomatitis with exanthema on hands and feet (hand, foot and mouth disease)

This disease is caused by enteroviruses, usually by Coxsackie A, Coxsackie B or ECHO-virus. Its etiopathogenesis and clinical manifestation are similar to those of herpangina, from which it differs by the presence of maculopapular and vesicular exanthema affecting the hands and feet (sometimes also skin of other parts of the body). The disease can affect any part of the oral mucosa and pharynx, except for the gingiva.

Th. and Dif. dg: It is identical with that treatment of herpangina.

5.3.5. Measles (morbilli)

This disease is caused by a virus of the paramyxoviruses group and affects predominantly children under 6 years of age.

Clinical picture: A gradually increasing body temperature is accompanied by catarrhal symptoms (coryza, dry cough, conjunctivitis). The temperature recedes after 2 days, only to return again, which is accompanied by an aggravation of the other symptoms and appearance of a maculopapular exanthema, the patches of which have a tendency to merge, typically progressing from the forehead, the region behind the ears and neck to the face, body and limbs.

In the oral cavity, enanthema develops, usually manifesting sooner than the exanthema. The buccal mucosa in the region of molars shows red round patches with small necroses known as Koplik's spots. Erythematic patches can also occur on the palate and labial mucosa.

Th.: Prevention – vaccination – is the key; if the disease still manifests, symptomatic therapy is administered.

5.3.6. Infections caused by the human papillomavirus (HPV)

Human papillomavirus is a DNA virus of the *Papillomaviridae* family. At present, more than 130 types of HPV are known. From the perspective of oncogenic potential, low-risk and high-risk types are being distinguished:

Low-risk HPVs (2, 4, 6, 11, 13 and 32) are the agents behind benign cutaneous and mucosal (oral, genital) acanthomas: **verruca vulgaris** on the skin, **mucosal viral papilloma** (common warts) on the oral mucosa, **condylomata accuminata** in the genital region as well as on the oral mucosa, or a rare focal epithelial hyperplasia – so-called Heck's disease.

The term *high-risk HPV* covers in particular types 16, 18, 31, 33 and 35 that may lead to the development of squamous cells carcinoma, which (in the region of the head and neck) means

almost exclusively oropharyngeal region. Approximately 90 % of HPV-positive oropharyngeal carcinomas is associated with the subtype 16. The prevalence of these tumours has grown recently. HPV-related oropharyngeal carcinomas possess, compared to those associated with smoking or other risk factors, different epidemiological, clinical and molecular characteristics and are characterized by a better prognosis and response to the therapy (Gurín et al., 2019).

HPV is considered to be an opportunistic infection more common among the patients with sexually transmitted diseases and in immunocompromised persons. The papillomavirus infects the basal epithelial cells (both of the skin and mucosa); it does not enter the bloodstream but leads to the production of antibodies (which is typically utilized for vaccination against HPV). The transmission of HPV occurs through both the direct and indirect routes (often by sexual intercourse, microinjuries of the skin or mucosa can act as gateways). The virus is relatively resilient and in a moist environment, it can remain infectious for up to several months. The incubation period is long, the infection is symptoms-free in 80-90% of cases (and disappears spontaneously) while in 10-20 % of infected persons, clinical manifestations can be observed.

Clinical picture: If benign lesions appear on the oral mucosa (manifestations on the soft palate are more common due to the transition from squamous to columnar epithelium), they usually form tiny (below 5 mm) painless, often whitish solitary (or multiple) structures of papillomatous appearance that can be both pedunculated or sessile. Usually, young individuals between 25-30 years of age develop such lesions. Tumours in the oral cavity can manifest as whitish or erythematous spots, non-healing ulcerations; in later stages, they can bleed. In the initial stages, the tumours of the oropharynx have no specific symptoms. They often mimic the symptoms of a chronic inflammation in the region such as sore throat or scraping in the neck, sensation of a foreign body, dysphagia, pain while swallowing (odynophagia), ear pain or rhinolalia. The progression of the tumour leads to accentuating the symptoms. The decomposition of the cancerous tissue is associated by bad breath (**foetor ex ore**), functional defects of the structures infiltrated by the tumorous process can also appear. Disease of the chewing muscles would manifest as a reduced motility of the lower jaw, infiltration of the muscles of the tongue, or as a reduced mobility manifesting as speech difficulties. If a nerve bundle is affected by an ingrowing tumour, we can observe a failure of its function (e.g. infiltration of the inferior alveolar nerve will cause a sensitivity defect on the skin in the lower lip region – Vincent's symptom). In general, we can observe that the patient loses weight. In some cases, the patient only comes when cervical resistance appears, which signifies the metastatic progression of the tumour into the cervical lymph nodes.

Dg: The diagnosis is based on results of the histopathological examination. When keratinocytes are infected by HPVs, the presence of koilocytes is a characteristic concomitant symptom. The overexpression of p16 protein, the surrogate marker of the presence of the high risk HPV 16, is used for immunohistological assessment of HPV-positive oropharyngeal squamous cell

carcinoma. A direct diagnosis based on the proof of particles of the HPV virus or of HPV DNA in the affected cells is also possible.

Th.: Benign lesions can be removed surgically (full excision), laser removal can be also used (especially where multiple eruptions are concerned; correct diagnosis prior to the laser removal is a must); where HPV or oropharyngeal carcinoma is concerned, a complex oncological treatment is necessary.

Dif. dg.: HPV papillomas must be differentiated from non-viral mucosal papillomas, fibropapillomas and fibromas on the one hand and squamous cell carcinoma on the other.

5.3.7. Manifestations of the primary HIV infection in the oral cavity

Following an infection by human immunodeficiency virus (HIV), 50-80 % of patients develop signs of acute HIV infection. These symptoms are however vague (fever, myalgia and arthralgia, fatigue, skin exanthema, lymphadenopathy – so-called mononucleosis-like syndrome). Acute pharyngitis is often present in the oral cavity at this stage as well as the eruption of superficial painful erosions on the hard palate that resemble aphthae (minor aphthae) but occur at unusual locations (recurrent aphthae never develop on the keratinized mucosa of the hard palate!). Erosions heal spontaneously within a week as well as the other symptoms of acute infection.

After the primary infection, a latency period follows (duration of this period is highly individual) during which the patient feels healthy and the CD4+ T-lymphocytes and macrophages that represent targets for the virus show normal values in the blood count. Later, however, when there is a notable drop in CD4 lymphocytes and the immunity breakdown, the patient ceases to be immune against infections and tumorous growth (see the Chapter 6.1.4.)

5.4. Bacterial infections

Some pathogens can cause a local infection (e.g. *Mycobacterium tuberculosis* can rarely initiate the development of primary tuberculosis – TBC of the oral cavity), others just participate in local diseases of the oral mucosa during systemic diseases. Of the systemic infections, we can find oral manifestations in bacillar (typhus, diphtheria, whooping cough) and coccal infections (scarlet fever).

5.4.1. Necrotizing diseases of the periodontium

Ulcerative gingivitis and ulcerative stomatitis fall according to the classification of the American Dental Association (both 1999 and 2018 issues) into the category of the „necrotizing periodontal diseases“.

Acute necrotizing ulcerative gingivitis

Anaerobic microflora of the subgingival plaque is generally considered to be the provoking cause of the disease. In particular, the oral spirochete of the *Treponema*, *Borrelia (Vincenti)* genuses and other periodontal bacteria (rod-shaped gram-negative bacteria of the *Tanarella*, *Prevotella*, *Porphyromonas*, *Fusobacterium*, *Aggregatibacter*, *Parvimonas* genuses). Proliferation of these bacteria most likely occurs in predisposed individuals when several local (insufficient oral hygiene, tartar, poorly made fillings, semi-retained teeth, smoking) and systemic factors (physical and psychological stress, tiredness, physical exertion, insufficient nutrition, hormonal changes, immune dysbalance, acute respiratory infection) combine.

The primary form occurs suddenly in generally healthy young individuals (17-25 years). The disease is acute and extremely painful, always preceded by the plaque-induced gingivitis. When proper treatment is administered and the patient cooperates, the healing is without complications.

The secondary form assumes immunodeficiency in the organism caused by a systemic disease (HIV, haemoblastosis). The course of the disease in such cases is protracted, atypical, the destruction of the periodontium is quick and the disease responds only slowly to therapy, often recurring.

Clinical picture of the primary form: The disease is not associated with any systemic symptoms. From full health, a sudden onset of catarrhal gingivitis occurs without any prodromal symptoms (which is important for differentiation from herpetic gingivostomatitis!). The catarrhal gingivitis is localized in a certain region of the dentition only, typically in the frontal section of the dentition around incisors and canines, or in the region of lower third molars. Sites with local irritation of gingiva are usually the most affected. Initially, the gingiva is erythematous, very painful (spontaneously as well as to touch) and bleeds slightly. Later, the picture changes, showing greyish necrotic areas on the tips of interdental papillae that may progress circumdentally into the whole marginal gingiva. After separation of the necrotic tissue, ulcerated margins with typical “bevelled” interdental papillae can be found. The process is usually limited to the gingiva but it can also spread to the alveolar mucosa, buccal, lingual and palatine mucosa – **ulcerative gingivostomatitis**. If proper therapy is not initiated, the disease can recede spontaneously (albeit with a risk of recurrence) or become chronic – either as a painless ulcerative gingivostomatitis or as a very painful **ulcerative gingivoperiodontitis** associated with rapid destruction of the alveolar bone. Swelling of submandibular nodes, hypersalivation and bad breath are typical concomitant symptoms. Major subjective difficulties occur while eating or when performing oral hygiene (that becomes very difficult or even impossible, thus potentially further deteriorating the condition).

Dg.: The diagnosis can be established on the basis of the clinical findings (changes on the papillae occur as soon as the 2nd or 3rd day).

Dif. dg.: For differential diagnosis, it is necessary to check the blood count (leukaemia, agranulocytosis, etc.) and anti-HIV antibodies (secondary form)!

Th.: Depending on the intensity, extent and duration of the disease, local or systemic therapy may be needed. Local therapy is based on the effect of aerial oxygen on anaerobic bacteria. At the clinic, the necrotic tissue is carefully removed using cotton swabs soaked with 30 % hydrogen peroxide and the patches bearing signs of early development of the disease are washed by the same solution using a syringe with a blunt cannula. Such treatment shall be repeated every day for 2-5 days. In the acute phase of the disease, any surgical procedures (including tartar removal) are contraindicated. At home, a gentle but proper oral hygiene (a single tufted brush) is recommended, along with application of 6 % H₂O₂ on the patches. Treatment can also include antiseptic washes (hexetidine, chlorhexidine) and the application of a local anaesthetic spray before a meal. A pulpy and non-irritating diet is recommended. When subjective difficulties disappear, local irritating factors such as dental crowns and overhanging fillings are removed, aiming at reducing the subgingival plaque.

In the chronic form of the disease, it is beneficial to complement the local therapy with systemic administration of ATBs (metronidazole, tetracycline) in the usual dosage and symptomatic therapy (painkillers).

Necrotizing ulcerative periodontitis

This rapidly progressing disease leads to premature loss of teeth within a very short period (approx. 6 months from diagnosis). Only some (groups of) teeth can be affected but affliction of the entire dentition is not uncommon.

Clinical picture: The periodontium is not affected evenly; a purulent exudation from the periodontal pockets is common. Soft alveoli-covering tissues are prone to the necrosis as well. Severe gingivitis with necrotic disintegration of the papillae is always present. The disease is very painful. X-ray examination will prove an uneven loss of bone, sometimes even osteonecrosis with a formation of sequestrers.

Th.: Initially, analgesia is necessary (approximately for 2 weeks). Systemic antimicrobial therapy needs to be administered (nitroimidazol, TTC – be careful about the possibility of development of secondary oral candidiasis due to dysmicrobia in the GIT). Surgical treatment is not indicated.

5.4.2. Contagious impetigo (impetigo contagiosa)

Contagious impetigo counts among pyodermas, often affecting the perioral region and vermilion zone. Impetigo contagiosa streptogenes is a highly contagious disease caused by beta-haemolytic streptococci and affects predominantly children in groups. It occurs seasonally with a maximum in the summer and autumn months. Primarily, tiny blisters erupt, the roof of which soon breaks and erosions appear, covered by honey yellow crusts. Regional lymphatic nodes are usually swollen. Impetigo can spread continuously further to the facial skin. In adolescence, both

conscious and unconscious mechanical trauma to the corners of the mouth often occurs, resulting in the development of **angular cheilitis**. Atopic eczema represents a significant predisposition for **contagious staphylococcal impetigo** (*impetigo contagiosa staphylogenes*) as *Staphylococcus aureus* is present on the skin in approximately 90% of patients with atopic eczema (compared to 10% in healthy population), which can facilitate the invasion. The primary manifestation of this disease is a small blister that soon becomes purulent and once the roof is torn down, dirty greenish crusts are formed. After healing, pigmentation may persist on the affected area for some time.

Th.: The local therapy is managed by a dermatologist; the prevention of underlying factors is however of utmost importance.

5.4.3. Syphilis

The causative agent of this disease is a spirochaete bacterium *Treponema pallidum*. The clinical picture of syphilis in the oral cavity is varied and can resemble many afflictions of various etiologies. The oral mucosa can be affected in all stages of acquired syphilis and many of such manifestations can be highly contagious! In the congenital forms of syphilis, intraoral manifestations can be also present but do not affect the oral mucosa – rather, teeth and bones of the jaws can be affected (keratitis, labyrinthitis and Hutchinson's teeth constitute a typical Hutchinson's triad).

The disease is transmitted almost exclusively through a direct contact with an infected person. The most common route is sexual intercourse (oral cavity can be affected after oral sex). When the infection manifests in the oral cavity, other forms of the contact such as kissing can lead to the transmission, indirect transmission is uncommon but possible. The oral cavity is the most common site of the extragenital localization of the primary infection (10 % of cases!) – if the primary route of entry of the infection into the body is in the oral cavity (including lips), the primary manifestation (chancre) occurs there. It appears approximately three weeks after an oral sex as a shallow ulcer with rolled margin. Initially, it is a flat, erythematous papule approx. 1 cm in diameter, gradually turning into a pink, lard-like, glossy ulcer with rolled borders or an erosion with a mushy surface that can be coated with a tissue detritus and precipitated blood proteins. On the vermillion, it can manifest as a crust. A noticeable oedema surrounds the ulcer – so-called initial sclerosis. A complete painlessness of the defect and the hardness of the floor of the erosion when examined by palpation (in gloves!) are typical. The discrepancy between the clinical finding and appearance of the lesion and the subjective problems reported by the patient is striking. The chancre heals spontaneously in 6-8 weeks after the infection. While the chancre persists, lymphangitis and regional lymphadenitis develop. The lymph nodes are mobile, elastic, painless and together with the chancre, they form so-called primary complex.

The disease enters the early latency period, after which the secondary stage follows. At this stage, the disease is already generalized and manifests after 8-10 weeks from the infection by mild

non-specific prodromes resembling a viral infection, followed by general lymphadenopathy associated with spleen enlargement, specific laryngitis and tonsillitis. The non-specific prodromes may include fatigue, elevated temperature, headache, loss of appetite and weight loss, polyarthralgia and polymyalgia. Macular exanthema (roseola syphilitica) develops. Other skin symptoms may be varied, it is however unusual for more than one type of lesions to be present on the skin or mucosa at the same time (monomorphic exanthema). In the oral cavity, enanthema (red spots) can be found, other types of lesions include smooth patches in the physiological coating of the tongue (plaques lisses), yellow-white, slightly elevated patches with an opalescent surface on the dark red base (plaques opalines) that later transform into erosive plaques (plaques muqueuses).

In the mouth corners, macerated mucosa can be found, similar to that of the primary stage (i.e., painless bilateral angular cheilitis with crevices) or warts resembling condylomas on the outer genital or in the perianal region can appear in the oral region, which are highly infectious. About of strikingly painless tonsillitis can appear (syphilitic tonsillitis) Tonsils are red, oedematous, coated or not, sometimes accompanied by hoarseness (syphilitic laryngitis). Systemic symptoms are usually missing in this stage! It is necessary to emphasize again that all the above-described syphilitic lesions are painless and can vary in appearance. The manifestations of the second stage syphilis in the oral cavity are frequent and very contagious! After the second stage, the duration of which can vary (2-5 years), the disease enters so-called late latency period that may take many years (at least 3 years). After that, the third stage (non-infectious) with localized organ impairment follows. In the early third stage, the dermal manifestation of the facial skin can propagate into the oral cavity in syphilis tubero-serpiginosa or ulcero-serpiginosa, forming infiltrations of various extents that tend to necrosis and scarring. Both circumscribed (gummas) and non-circumscribed infiltrations of soft tissues can develop, as can also non-circumscribed infiltrations of soft tissues or even jaw bones with decays resembling benign tumours.

Syphilitic gummas of the tongue result in its enlargement. The enlargement is usually irregular and lobed (lingua lobata) with hyperplastic growths of cauliflower-like character. The mucosa of the dorsum of the tongue is smooth, without papillae (clinical picture resembles atrophic glossitis).

The colliquation and decomposition of the infiltrates leads to a development of fistulas and scars. Oronasal communication can form when the hard palate is affected. **Syphilitic glossitis** represents another manifestation of the tertiary syphilis in the oral cavity. Its symptoms include leukoplakic changes in the atrophic epithelium of the tongue dorsum that can succumb to malignant transformation. Two types of **syphilitic interstitial glossitis** (glossitis interstitialisluetica) can be distinguished – **superficial** (with protruding infiltrations, mucosal hyperkeratosis/leukoplakia and occurrence of atrophic patches) and **deep** (glossitis interstitialisluetica profunda). The latter affects the entire tongue, which grows stiff and limits its mobility. Atrophy of lingual muscles or even scarring can occur, which can eventually lead to development of squamous cell carcinoma.

In the past, the terminal stage of the disease was associated with cardiovascular and nervous systems (tabes dorsalis, progressive paralysis).

Examination: To be able to confirm the primary infection in the oral cavity, dark field microscopy of the native material must be performed (the mucosal lesion must be free of antiseptic/antimicrobial agents for at least two days prior to the sample collection; repeated examinations are necessary). At this stage, the serological examination would still return negative results. A suspicion on the secondary stage of syphilis can be verified (or disproved) by serological tests for the presence of specific antibodies. Serological and histopathological tests can be used to confirm the third stage of syphilis.

Th.: The treatment is managed by department of dermatology/venereology; various schemes and algorithms with precisely defined criteria for successful treatment can be used. Reporting patients with this disease to the regional health administration is mandatory!

Dif. dg.: All three stages of syphilis may pose difficulties in establishing the correct diagnosis as there are multiple diseases that can be misdiagnosed for syphilis. In the first stage, a **traumatic ulcer** of the oral mucosa can be mistaken for syphilis. It can be differentiated from the primary stage of syphilis on the basis of being painful and short-term, of patient-provided information about a trauma and missing (or only mild) induration of the floor of the ulcer. So-called **neurodystrophic ulcer** is caused by damage to the oral mucosa insensitive due to the application of a local anaesthetic (and occurs mostly in children where acquired syphilis is not a typical diagnosis). **Recurrent aphthae major** are usually associated with multiple lesions, very painful and (as the name suggest) recur. Similarly, **labial herpes** (herpes labialis, usually associated with prodromes) or **skin pyoderma** (boils on the cutaneous side of the lips) are very painful, show tendency to colliquation, are reflected in the regional lymph nodes and often come with fever.

The differential diagnosis of the secondary stage does not need to be difficult if the physician considers it a possibility. A proper case history taking and detailed examination of the oral mucosa with subsequent serological verification are usually sufficient for diagnosis. The lesions can resemble many congenital mucosal disorders such as geographic tongue (lingua geographica; usually known from the patient history), recurrent aphthae, herpetic stomatitis, EEM or autoaggressive diseases.

Manifestations of the third stage of syphilis in the oral cavity must be in particular distinguished from the tubercular symptoms (at this stage, the diagnosis is usually already established), lingual tumours and cysts, leukoplakia and carcinoma.

5.4.4. Tuberculosis

Tuberculosis is caused by *Mycobacterium tuberculosis* or, rarely, *M. bovis*. The prevalence of this systemic disease has grown again over the last years. Malnutrition, immunosuppression and cachexia of various origins (HIV, drug addiction) constitute predisposing factors. The oral cavity is only rarely affected but there are three scenarios of possible occurrence: if the primary route of entry

of mycobacteria into the organism was through a damaged oral mucosa, secondarily as a result of autoinoculation during active TBC (usually pulmonary) or during spreading of cutaneous TBC into the oral mucosa.

Clinical picture: In case of a primary infection, a painless ulcer develops anywhere on the oral mucosa in two weeks. Regional lymph nodes are affected (enlarged and painless, may be subject to colligation) and a so-called primary complex (of the ulcer and a regional node) is formed. Subsequently, the primary complex either heals with only negligible systemic manifestations, or a generalized miliary TBC develops. If secondary inoculation of mycobacteria into mucosal defects occurs during active pulmonary tuberculosis (the dorsum of the tongue, buccal mucosa, or gingiva are most commonly affected), a single, deep and painful ulcer with rolled margins (tuberculoma) develops. The standard therapy with neutral substances has no effect and the ulcer can spread slowly into the surroundings (acting like a carcinoma – it cannot be distinguished clinically). If such an ulcer develops deep in the muscles, a fistula may form. If the gingiva is affected, bleeding granulations and growths can be present. Diagnosis of active TBC is usually known – patients are cachectic, weak and have distinct general symptoms. There is a risk of occupational TBC infection in health professionals! The cutaneous form of TBC (tuberculosis cutis luposa, lupus vulgaris) is very rare nowadays. It presents in the oral cavity as erythematous patches, sometimes with greyish nodes that tend to break down and bleed. Lupus vulgaris is generally considered a precancerous lesion.

Th.: Therapy is managed by specialized clinics of pulmonary medicine.

So-called atypical mycobacteria (*M. avium*, *M. kansasii*, *M. scrofulaceum*, *M. ulcerans*) can also cause mucosal defects with the appearance of ulcers in the oral cavity; this type of lesions is usually only found in HIV-positive patients.

5.5. Fungal (mycotic) infections

5.5.1. Oral candidosis (formerly moniliasis, thrush)

This inflammatory disease is caused by yeasts with predilection to the oral cavity from where it can further spread into the mucosa of the pharynx, esophagus or even respiratory pathways. The responsible yeasts are most commonly of the *Candida* genus (*C. albicans*, *C. glabrata*, *C. tropicalis*), i.e., saprophytic organisms normally present in the oral cavity (in our population, these species can be found in 40-50 % of healthy individuals).

The proliferation of these occurs in predisposed individuals following a local or systemic disruption of the immune system. Multiple predilection factors can lead to the development of the disease (physiological – pregnancy; pathophysiological – trauma, chemical trauma to the mucosa; serious infections; endocrine disruptions such as diabetes, malabsorption; haematological diseases such as leukaemia, agranulocytosis, aplastic anaemia; some medications such as immunosuppressants, corticoids, cytostatics or broad-spectrum antibiotics that can suppress many physiological microorganisms and thus aid the development of the yeast infection).

An important role in the disease development is attributed to certain properties of the yeasts, particularly to their capability to stick to the surface of the oral mucosa (and to the surface of plastics including dental prosthetic devices) and to grow through the epithelial wall of the oral mucosa, which in turn leads to a change in the character from saprophytic to the parasitic. The combined action of multiple local or general factors, the number of which increases due to the modern way of life, highly increases the susceptibility to this affliction and the number of individuals at risk of this disease therefore keeps increasing.

Clinical picture can be varied. The “white” (pseudomembranous and hyperplastic) and a “red” (erythematous) form without coating represent the most typical forms.

Dg.: Diagnosis of both pseudomembranous and erythematous forms of candidosis is based on the clinical appearance, mycological examination (microscopy, cultivation) and, if need be, histopathological, serological and/or immunological proof of the presence of yeasts. The patient’s history is also important for differentiation (systemic diseases, recent ATB treatment, immunosuppressants).

Th.: Where possible, antimycotic therapy (both local and systemic) should be combined with the treatment of the predisposing illnesses. The therapy must be driven by the severity of problems, patient’s health condition and, if applicable, sensitivity of the yeasts to the applied antimycotic therapy. Local treatment is always sufficient in angular candidosis and mostly in acute candidosis. In chronic forms of the disease, however, a complex antimycotic therapy (ideally using the 3rd generation of azol antimycotics, so-called triazoles) should augment the local therapy. One must however bear in mind the relatively large number of potential drug interactions and risk of liver damage due to the long-term usage of triazoles.

In atrophic candidosis (see below), the optimum solution lies in constructing a new denture (or a laboratory rebase) and maintaining a proper hygiene of the denture (i.e., mechanical cleaning every day after food, washing with soap/disinfectant and brush under running water every evening, and submerging the denture into a cleaning antibacterial solution overnight; such a cleaning solution is to be prepared by dissolving special cleaning tablets in the water). Supplementary measures may include general introduction of good hygiene to the oral cavity, management of carious teeth, treatment of the periodontium and extraction of destructed teeth and radices (elimination of the yeast reservoirs). The treatment of predisposing illnesses, if possible, is important, as is smoking cessation or at least reduction. The therapy should not be interrupted before a full regression of the clinical manifestations and/or negative mycological examination. In patients with a systemic disease predisposing to the development of oral candidosis, a long-term prophylaxis (general or local) is recommended.

Dif. dg.: It is necessary to distinguish this disease from other mucosal diseases with keratinization disorders in the sense of hyperkeratosis and parakeratosis that also lead to the development of „white areas“.

Acute pseudomembranous candidosis

This is the most common, typical form of candidosis with sudden onset and formation of whitish partially removable coatings (pseudomembranes) resembling curdled milk – colonies of yeasts. These pseudomembranes have no predilection for a particular location in the oral cavity, it is however uncommon for them to occur on the gingiva. Due to the pseudohyphae penetrating the surface layers of the mucosal epithelium, the coating is firmly attached to the mucosa and if forcibly removed, the mucosa bleeds or erosions appear. In the surroundings of the coatings, the mucosa is markedly erythematous. Subjective complaints may range from burning or increased sensitivity to painfulness of the affected mucosa and disorders of taste perception. Painful swallowing should lead us to suspect the spreading of the infection into the GIT. If the inflammation does not heal spontaneously or after therapy, it can turn into a chronic disease, to the process dissemination or generalization of the process.

Acute erythematous candidosis

The disease typically develops as a result of dysmicrobia in the oral cavity or the entire GIT, mostly due to treatment with broad-spectrum ATBs. Clinically, it manifests only through a formation of diffuse erythema on the mucosa (without pseudomembranes) associated with pain, burning and sensation of dryness in the mouth. Corners of the mouth can be inflamed as well. If correct therapy is administered and the intestinal microflora restored, the disease regression is quick.

Chronic pseudomembranous candidosis

This disease represents a serious affliction of the oral mucosa, bearing a risk of dissemination and generalization of the process. It especially affects immunodeficient or oncological patients. The candidosis is usually extensive and progresses into the oropharynx and other parts of the gastrointestinal and respiratory tracts. The patient often only complains about problems swallowing. Spontaneous regression of the disease is rare; the success of the therapy however depends on the overall condition of the patient and effectiveness of the antimycotic therapy.

Chronic hyperplastic candidosis

This form of oral candidosis is relatively rare. The affliction is always a long-term one (months to years). It can appear as a part of so-called chronic mucocutaneous candidosis, especially in individuals with congenital immunological disorders. It first manifests in childhood and is frequently associated with certain endocrine disorders such as a hypofunction of adrenal medulla and parathyroid glands or myasthenia. Subjective complaints are usually minimal, sometimes even absent, which is however in a direct contrast to the extent of the defect (white non-removable lesions, most commonly on the buccal mucosa and tongue, the immediate vicinity of which is normal, without any erythema. The treatment is very difficult.

Chronic erythematous atrophic candidosis

Most commonly, this disease develops as a so-called „prosthetic stomatitis“ in patients with removable dentures. It particularly affects the mucosa of the denture bed, where either massive induration and papillomatous, hypertrophic mucosa or, contrary, erythematous atrophic surface can be found. This form has a high tendency to recur – most likely, such recurrences are repeated reinfections as the prosthesis serves as a yeast reservoir. Making a new denture and a meticulous hygienic care for it is an optimal solution for preventing the oral candidosis. The mucosa of the dorsum of the tongue is another common site of the chronic atrophic candidosis. Here, it is without pseudomembranes, markedly erythematous, sometimes with papillomatous hypertrophy and normal surroundings of the lesion.

Angular candidosis

This disease (usually caused by *C. albicans*) affects the skin and mucosa solely of the corners of mouth but can also be associated with more extensive lesions of the oral cavity. Typical appearance includes crevices and erythematous patches with indistinct whitish margins of the labial mucosa, often bilaterally. Deeper defects such as fissures, bleeding or formation of suppurative discharges and crusts are uncommon. In patients suffering with this disease, we often observe a reduced height of bite due to defective dentition with unsuitable dentures. The corners of the mouth become macerated with saliva, which leads to further aggravation of the complaints. In children, a secondary streptococcal infection (impetigo) can develop and spread further on the surrounding facial skin.

Dg.: Of the examination methods, bacteriological and mycological examinations are the most important; where the disease persists, haematological and biochemical examinations (glycaemia) should be employed, along with sialometry and assessment of the quality of the dentures. The presence of *Staphylococcus aureus* is often detected during such examinations.

Th.: Firstly, removal of the provoking cause should be attempted (reconstruction of the height of bite – rebase, new denture, replacement of the supporting zones). The treatment varies according to the etiology. Antimycotics (nystatin,azole antimycotics), should be administered; if bacterial infection is proved, local ATBs should be also used (neomycin). In adult patients, combined preparations containing anti-inflammatory corticosteroids may be applied (the application of those however must be well thought through and remain short-term!).

Dif. dg.: Herpes simplex (labialis) in the area of the corners of mouth is usually one-sided, the eruption is preceded by prodromes (paresthesia), the vicinity of the lesion is usually erythematous and oedematous, sometimes painful. The syphilitic primary chancre is one-sided, painless erosion or crevice with hard bottom; painless swelling of lymphatic nodes is also common. Another disease that can be mistaken for angular candidosis is a squamous cell (or, less commonly, other) carcinoma of the lip, which is usually painless, irresponsive to treatment and usually is larger (hence, if the lesion

does not respond to therapy within 1-2 weeks, a surgical excision at a specialized department is necessary!).

Median rhomboid glossitis (glossitis rhombica mediana, Brocque-Pautrier's glossitis)

This glossitis manifests as an erythematous smooth oval, rectangular or diamond-shaped patch on the mucosa in the central third of the dorsum of the tongue (in front of the circumvalate papillae). The surface is markedly smooth, glossy and red, the physiological surface formed by the filiform and fungiform papillae is missing in the lesion. In some cases, however, bumps may occur on the surface, which can lead to cancerophobia in the patient. The mucosa can be more sensitive or even painful, especially during tactile perception or speech. The disease only affects adults, the etiology is not completely clear. In the past, the condition was considered congenital (rest of the median tongue bud). At present, it is, due to the typical coincidence with yeast infection, classified as a candida-associated lesion. The smear cultivation usually proves the presence of yeasts.

Th.: Therapy is difficult – elimination of smoking and mechanical irritation, antimycotic therapy (particularly local antimycotics but if need be, systemic administration is possible).

Dg.: In differential diagnosis, simple mechanical irritation of the dorsum of the tongue, geographic tongue, acute erythematous candidosis, herpetic glossitis and haemangioma must be considered.

Black hairy tongue (lingua villosa nigra)

Hyperplasia and hyperkeratosis of the filiform papillae with the appearance as if combed down towards the tip of the tongue are typical of this disease. The hyperplasia is most prominent around the median sulcus in the distal and central thirds of the dorsum of the tongue. The discoloration can be caused by chromogenic bacteria, smoking, poor oral hygiene, use of broad spectrum antibiotics or some oral antiseptics such as chlorhexidine (CHX) or hydrogen peroxide, in particular when using them for longer periods of time and/or at increased concentrations. Due to its coexistence with yeast infection, this affliction of the tongue is currently counted among candida-associated lesions. It is therefore associated with dysmicrobia in GIT or just the oral cavity followed by the proliferation of the yeasts. Over the course of several days, a massive yellow to blackish-brown coating of the central third of the tongue develops as a result of hyperkeratosis, hypertrophy and hyperpigmentation of filiform papillae. The patients usually do not suffer with any subjective complaints. The disease mostly affects adults, only rarely children.

Th.: Local antimycotic treatment combined with mechanical removal of the coating using large spoon excavators, toothbrushes (or using swabs, which can however be unpleasant or even painful). Systemic administration of nicotinamide is also possible (when its deficiency due to the disruption of its synthesis by GIT microorganisms is suspected), elimination of smoking is also beneficial.

Dif. dg.: acanthosis nigricans „maligna“

5.5.2. Systemic (deeply invasive) mycoses

These invasive opportunistic fungal infections (aspergillosis, zygomycosis, cryptococcosis, histoplasmosis) affect mostly seriously immunosuppressed individuals. The invasion of such microorganisms into the vascular bed and the subsequent formation of thrombi leads to a necrosis of the surrounding tissues.

Clinical picture: Non-healing ulcers and necroses affecting in particular the hard palate and alveolar process of the upper jaw. The disease progresses rapidly, spreading into the entire organism and often leading to death of the patient.

Th.: Therapy is very difficult, it includes intravenous antimycotics and surgical removal of necroses and ulcers.

5.6. Manifestations of deficiency of vitamins of the A and B groups and Fe on the oral mucosa

<i>Vitamin:</i>	<i>Role in metabolism:</i>	<i>Findings:</i>
A	Participates in the synthesis of dehydrogenases	Hyperkeratinization of the epithelium (+ retina)
B ₁ (aneurin)	Carbohydrate cleavage	Dryness, lip desquamation, erythema and induration of the tongue
B ₂ (riboflavin)	Part of coenzymes involved in oxidative metabolism	Exfoliative cheilitis, angular stomatitis, glossitis (magenta), stomatitis
B ₃ (PP, niacin)	Part of dehydrases	Stomatitis, glossitis (erythema, induration)
B ₆ (pyridoxin)	Part of transaminases, carboxylases, decarboxylases	Inflammations of the corners of the mouth, tongue, oral mucosa
B ₉ (folic acid)	Synthesis of nucleic acids	Atrophic glossitis, sensitivity and painfulness of the tongue and the oral mucosa
B ₁₂ (cyanocobalamin) (Castle's extrinsic factor)		Hunter's glossitis (pernicious anaemia)
Fe	Part of haemoglobin, cytochrome-oxidases, myoglobin and others	Angular stomatitis, atrophic glossitis (Plummer-Vinson's syndrome)

6. Internal causes

Predisposition to certain diseases may also be caused by „intrinsic“ factors such as the age, sex, race and congenital individual specifics (genetic influences), the sum of which contributes to the constitution of the organism.

Many diseases of the oral mucosa manifest predominantly in patients of certain age groups (herpetic gingivostomatitis in children, ulcerative gingivostomatitis during adolescence, etc.), which may be helpful in establishing the correct diagnosis. In general, we can say that certain periods in life are associated, due to the immunological and hormonal changes, with a higher risk of developing an oral mucosal disease. At the newborn and infant age, the immunity passively acquired through the transport of IgG antibodies through the placental barrier drops steeply in the first weeks of life. Only after several weeks, the production of own immunoglobulins begins and cellular immunity is being established. Oral candidosis is a typical disease associated with this age. Another important period is the puberty, characterized by major hormonal changes in the organism, which is associated with the highest prevalence of ulcerative gingivitis (maximum between 16 and 21 years of age), infectious mononucleosis or EEM. At the old age, physiological reserves grow smaller and the number and intensity of pathological processes grows. A general decline of immune response and of the so-called immunological surveillance can be observed, which leads to an increase in the occurrence of autoimmune diseases (pemphigus, Sjögren syndrome) and cancer. Hormonal dysfunction, especially in women, is associated with atrophy of the skin and mucosa, vasomotor disorders and emotional lability. Deficiency states and metabolic diseases (diabetes) develop more commonly, which may lay grounds for the development of the mucosal pathology (oral candidosis, stomatodynia). The loss of own teeth and use of dentures represent another risk factor due to the local irritation (prosthetic stomatitis, painful corners of the mouth).

6.1. Immunopathological diseases of the oral mucosa

The defence from the foreign agents (in particular from microbial antigens) is a necessary prerequisite for the existence of any individual. The first encounter with the antigen activates the innate non-specific immune mechanisms capable of reacting very quickly (within minutes to hours). This **non-specific immunity** is predominantly mediated by the complement system and phagocytes (phagocytosis) and manifests as an inflammatory reaction. This encounter of the organism with a foreign protein leaves a permanent information “stored” in the organism, which allows this agent to be recognized and deactivated at any future contact. Specific antibodies are produced – **specific immunity**, reaching a maximum after 2-3 weeks and then declining. The above-described process represents the so-called primary immune response. With every subsequent contact with the antigen, the antibodies are produced sooner and in greater quantities, which is called secondary immune response. The result of such immune response may however not be

always positive as it can lead (if pathological reactions occur) to development of a disease. As far as mucosal diseases are concerned, the pathological manifestations may include the immune system oversensitivity (allergies), autoimmune damage of the tissues and/or states of immunodeficiency.

6.1.1. Allergic reactions, hypersensitivity of the oral mucosa

Over the last decades, the number of individuals with allergic reaction to various substances they encounter over the course of their lives grows. Allergy represents overreaction of the immune mechanisms. That oversensitivity may be humoral (anaphylactic type reaction, cytotoxic type and oversensitivity of immune complexes) or cellular (cell-mediated oversensitivity).

Type 1 – anaphylaxis: this term describes a reaction between an antigen and an IgE antibody. Degranulation of phagocytes and basophils occurs, followed by a release of vasoactive histamine-like substances, SRS. IgG antibodies also participate in the reaction with the antigen – this complex activates the complement, anaphylactogenic components of which, namely C3a and C5a, facilitate/support the release of histamine. Anaphylactic shock then represents an example of such a reaction (in dentistry, this most commonly occurs after administration of anaesthetics, ATBs or other substances).

Type 2 – cytotoxic type: Formation of the bond between the antibodies and cellular antigen leads to activation of the complement, disruption of the cellular membrane and cytolysis. This mechanism leads to autoimmune haemolytic anaemia or drug-induced purpura.

Typ 3 – oversensitivity of immune complexes: the antigen-antibody bond leads to formation of pathological complement-activating immune complexes. The result of the reaction depends on the ratio between the antigen and antibodies. If the antibodies are in excess, an Arthus type reaction (necrosis) occurs on the site of the antigen entry into the organism. If the antigen is in excess, the circulating immune complexes penetrate the vascular wall and result in vasculitis (e.g. in systemic lupus erythematoses).

Typ 4 – cellular: this reaction is sometimes called tuberculin-type reaction (as the TBC-Mantoux reaction represents this type). It sets in later, the antigen first binds to so-called antigen-presenting cells (APC) and sensitizes the T-lymphocytes. They proliferate and differentiate into subpopulations of regulatory (suppressor and helper T-cells) and executive (cytotoxic T-lymphocytes), capable of killing the target cells. The regulatory subpopulation of the helper T-cells produces lymphokines that can damage the tissue by themselves (an example of such reaction is contact dermatitis).

Allergic reactions on the oral mucosa develop after sensitization with an antigen suddenly, manifesting as erythema, oedema, blisters or erosions. Epithelial desquamation, crevices or fissures (sometimes even haemorrhagic) appear in the vermilion zone. Those changes are clinically variable

and non-specific, the patient subjectively complains about burning or pain. The oral symptoms can be accompanied by lesions on the skin in the adjacent areas.

Typical manifestations of the allergic reaction of the 1st type include the allergic drug-induced stomatitis and allergic angioedema. The allergic reaction of the 4th type results in the development of a contact allergic reaction (allergic eczema).

Drug-induced allergic stomatitis (stomatitis medicamentosa)

The clinical picture of drug-induced stomatitis with allergic etiopathogenesis can be polymorphic (and similar to stomatitides of other etiologies such as EEM or herpetic gingivostomatitis). The inflammation is usually turbulent with a lot of exudate and usually affects larger areas of the oral mucosa in various locations (the gingiva is however only rarely affected). In the forefront of the clinical picture, there is an acute inflammation with infiltration of the oral mucosa, which may be catarrhal and/or accompanied by blisters and by a subsequent development of erosions or even ulcerations. The coating of the tongue is typically thickened, moist and whitish, the discoloration can however be modified by previous treatment (it may be e.g. whitish to brown due to ATB treatment). Drug-induced stomatitis can also have the clinical picture of anaphylactic reaction with urticaria-like skin manifestations; oedema with infiltration of lips, macroglossia and possibly inspiratory stridor (laryngeal oedema) can appear on the face, in the oral cavity and/or on the larynx. In the field of dentistry, the biggest role in this respect is played by anaesthetics and antibiotics, which can bring about even a systemic reaction (anaphylactic shock). A targeted and meticulous taking of the patient history is usually crucial for establishing the correct diagnosis.

Many drug-induced stomatitides are however not caused by allergic reactions but result from other pathogenic mechanisms (toxic or non-allergic immunopathological reaction, microbial dysbalance, etc.).

Th.: In stomatitis of allergic etiology, the short-term use of antihistamines or corticosteroids is indicated. Local therapy is limited to washing the mouth with herbal infusions.

Angioedema

Allergic angioedema results from an allergic reaction of the 1st type, usually in association with hypersensitivity to a certain food or drug. It usually develops rapidly, the tissue is soft, non-inflammatory, the site of the reaction is painless and well-circumscribed, regressing spontaneously within several hours to days. The face, especially eyelids and lips, are typically affected, other regions include the oral mucosa (angioedema of the oropharynx can lead to suffocation!), the GIT, limbs or genitals. Typically, swelling of the skin and subcutaneous tissues or mucosa and submucosal tissues is observed.

Congenital (hereditary) angioedema is similar in appearance, the underlying cause is however conditioned by the disruption of the complement system. A C1 inhibitor defect leads to an unregulated

activation of the components of the complement, to the release of anti-inflammatory substances and development of an oedema. Drug-induced angioedema can develop in patients using ACE inhibitors.

Allergic contact stomatitis (stomatitis venenata)

Contact allergies developing on the lips and oral mucosa after a direct contact of the mucosa with certain substances are relatively commonplace. They can be induced by some components of food (nuts, fruits, additives, preservatives), cosmetic products (lipsticks) or materials used during dental procedures (eugenol, acrylic and epoxy resins, silicone and eugenol impression materials, some metals used in dentistry, in particular nickel). Such allergies can also result from the use of oral hygiene preparations (toothpastes, mouthwashes), some local treatment agents (propolis) and mucosal antiseptics. A contact allergic reaction can also appear after a contact of the oral cavity with latex (gloves, dental dam), which can be prevented by the use of unsaturated latex materials (containing vinyl and nitrile rubber). Clinically and histologically, mucosal oedema with intraepithelial blisters and a marked leukocyte infiltration is observed.

Th.: Elimination of the allergen, short-term administration of antihistamines or corticosteroids. Local therapy could, if an unsuitable preparative is used, lead to an aggravation of the condition and is therefore not recommended.

6.1.2. Manifestations of autoimmune diseases on the oral mucosa

Normally, the immune system can distinguish between „its own“ and „foreign“ antigens. It has a broad capacity and spectrum and can react basically against any molecule or cell. Although the capability of react to its own antigens exists in most people, they usually induce no reaction (anergy or tolerance), which implies the participation of mechanisms capable of preventing or suppressing autoimmune responses. Besides, the autoreactive T and B lymphocytes (just like auto-antibodies) are relatively often found also in people who are not suffering with any autoimmune disease, which suggests that the immunological reactivity is not a sufficient condition for development of an autoimmune disease on itself (we speak of autoimmune disease only if the disease leads to tissue damage). Mechanisms that are assumed to participate in prevention/suppression of the autoimmune response include inactivation or deletion (a type of chromosomal aberration) of autoreactive T and B cells (the forbidden clone theory), active suppression of the cells or cytokines, idiotypic/anti-idiotypic interactions and immunosuppressive adrenal hormones (glucocorticoids).

If, however, the suppressive mechanisms prove insufficient, a reactivity against organism's own antigens can appear and lead up to the development of autoimmune diseases that can be either organ-specific (diabetes, thyroiditis, pemphigus, pemphigoid) or systemic (non-specific) such as the systemic lupus erythematosus (SLE) or rheumatoid arthritis (RA) that can result in multiorgan damage. The pathogenesis of the autoimmune diseases can primarily involve autoantibodies (e.g.

haemolytic anaemia), immunocomplexes (SLE), cellular immunity (e.g. multiple sclerosis) or a combination of humoral and cellular immunity (e.g. RA). Joint action of several co-factors playing important roles in development of such diseases are assumed: genetics (e.g. HLA associations), gender and age. Properties of the individual antigens and the way in which they are presented to the immune system are also important. Some infections, e.g. EB virus (Epstein-Barr virus) or mycoplasma infections, can induce the production of autoantibodies in otherwise healthy patients. Some medications such as procainamide (used e.g. in treatment of some types of cardiac arrhythmias) or toxic substances such as mercury(II)chloride or polyvinylchloride can induce autoimmune reactions. Various such diseases can manifest in the oral cavity, in particular pemphigus, pemphigoid, SLE, Sjögren syndrome, etc.

Diseases of the pemphigus group

Pemphigus is a chronic autoimmune blistering disease affecting skin and mucosa. Based on the clinical, histopathological and immunological criteria, four basic forms of the disease can be distinguished: pemphigus vulgaris, p. vegetans, p. foliaceus ap. erythematosus (Senear-Usher's syndrome).

Pemphigus vulgaris

This, the most common, disease in this group is characterized by the production of antibodies against membrane antigens of keratocytes and their intercellular substance, which leads to a disruption of intercellular junctions, acantholysis and formation of intraepithelial blisters. It affects both sexes evenly, mostly between 50 and 60 years of life but it can develop at any age. In most patients (approx. 90 %), the oral mucosa is affected and in approximately 50 % of all patients with this disease, it begins in the mouth! The manifestations can remain limited to the oral mucosa for many months to years. In addition to the oral mucosa, however, mucosa in the genital region and conjunctiva can be also affected.

Clinical picture: The disease can begin at any spot of the healthy, non-inflamed skin or mucosa by formation of blisters with clear fluid. The contents of the blister gradually grow turbid, becoming yellowish to haemorrhagic. The blisters are of varying sizes, often merging and when breaking, painful erosions develop that can spread into the adjacent areas. The eruptions often manifest in waves and after a time (of various duration), the process can become systemic. The generalized form of the disease affecting organs is a very serious disease with a high risk of mortality, often due to complications associated with the immunosuppressive therapy. On the oral mucosa, erosions are more commonly found than blisters, which is caused by the fact that the roof of the blister is easily torn down and on examination, only the erosion remains. The mucosa is usually oedematous but bears no signs of inflammation (the lower degree of inflammatory symptoms is an important sign for differential diagnosis). The erosions can develop anywhere in the oral cavity but they are most

commonly found on the mucosa of the soft palate, buccal mucosa and mucosa of the lower lip. In the vermilion zone, yellowish crusts formed by drying of the exudate on the surface of the erosions can be observed. A typical sign of pemphigus is the way it spreads, i.e., intraepithelial spreading into the periphery; a pressure applied by a finger followed by pulling the finger along the normal skin, the surface layer of epidermis gets separated (Nikolski's sign I). When applying pressure of the finger on the surface of the bulla, its content is pushed under the surface layer of the adjacent epidermis and the blister increases (Nikolski's sign II). The erosions heal very slowly, the epithelised areas may be slightly atrophic with hyperpigmentation.

Dg.: Discovery of an acantholytic intraepithelial blister during histological examination. Immunofluorescence examination (IF) revealing IgG antibodies and the C3 component of the complement in the intercellular space or circulating antibodies in the serum. An assay for desmoglein 3 can be also performed using ELISA; the presence of desmoglein is specific for pemphigus vulgaris. In the smear from the blister floor, acantholytic cells can be found (Tzanck's test).

Th.: Systemic administration of corticosteroids in high doses, potentially combined with other immunosuppressants. The therapy and treatment itself including follow-ups must be done in specialized departments of dermatology-venereal diseases. The treatment requires frequent clinical and laboratory follow-ups.

Locally: corticosteroids in orabase or mouthwash, local ATBs.

Dif. dg.: Bullous pemphigoid, EEM, bullous drug-induced eruptions. In the oral cavity, erosive lichen planus, persisting aphthae, Behçet disease, benign familial chronic pemphigus (Hailey-Hailey, a histologically identical hereditary form with a chronic course, which is however significantly less aggressive).

Pemphigus vegetans

This subtype of pemphigus vulgaris forms soft, moist, dark red wart-like vegetations, on the periphery of which isolated blisters are almost always found. Those vegetations represent a major proliferation of some excoriations. In the oral cavity, they predominantly appear in the area of the corners of the mouth. They are frequently invaded by *C. albicans* as a secondary infection.

Dg., dif. dg. and th.: Same as in p. vulgaris.

Pemphigus foliaceus

This disease represents a superficial, less serious form, which however has a prolonged course. It appears only rarely. It is characterized by subcorneal localization of acantholytic blisters. Due to this localization, we can only rarely see the intact blisters but rather eroded and crust-covered patches. The lesions can be most commonly found in the hair, face, trunk and in the seborrhoeic areas of the body. Oral mucosa is only rarely affected (small, superficial erosions).

Pemphigus erythematosus

This superficial type of pemphigus is also rare, has a mild course and usually a good prognosis. The disease is characterized by erythematous eruption similar to lupus erythematosus, with which it can coexist (as well as with myasthenia gravis or thymoma). Oral mucosa is only very rarely involved, if so, we can see only superficial erosions.

Paraneoplastic pemphigus

This rare autoimmune disease has been only recently described. This type of pemphigus manifests by lesions on both skin and mucosa in individuals with cancer, most commonly leukaemia and lymphomas. The clinical picture is characterized by a) polymorphic skin lesions, often manifesting as papulosquamous eruptions b) painful erosions resistant to treatment, often affecting the lower lip, c) persisting erosions of the conjunctiva.

Diseases of the pemphigoid group

Benign scarring mucosal pemphigoid (cicatricial pemphigoid, mucous membrane pemphigoid)

This chronic autoimmune disease affects predominantly the mucosa and results in epithelial atrophy. It usually affects middle-aged and older individuals. A genetic predilection with participation of the HLA complex gene (a greater frequency of the HLA-B12 antigen) has been proposed as a possible etiology.

Clinical picture: Most commonly, the oral mucosa and conjunctiva are affected, followed by nasopharyngeal and esophageal mucosa and the anal region. Skin lesions appear only in 20-40 % of patients. In the oral cavity, the disease mostly affects the gingiva, offering the clinical picture of desquamative gingivitis; other parts of the mucosa can however be affected. Similar to pemphigus, intact blisters can be only rarely found and only the erosions or secondary scarring are usually observed! If eyes are affected, the cornea can be damaged, which can result in blindness. Lesions on GIT mucosa often lead to the formation of strictures.

Dg.: Histological examinations will reveal non-specific ulcerations with chronic inflammatory cellularization. Immunohistochemistry will prove the presence of deposits of IgG, IgA, IgM and C3 component of the complement in the basal membrane. BP 180 and BP 230 proteins, laminin 5, integrin and Type VII collagen can be detected using immunoblotting, which helps differentiate the benign mucosal pemphigoid from the bullous pemphigoid, epidermolysis bullosa acquisita and systemic bullous lupus erythematosus. In the case of benign mucosal pemphigoid, BP 180, BP 230 protein and Type VII collagen are detected.

Dif. dg.: pemphigus, erosive OLP, recurrent aphthae, Behçet disease

Th.: Systemic administration of corticosteroids that can be supplemented with other immunosuppressives. In mild forms, a local therapy with topical steroids may be sufficient.

Bullous pemphigoid (parapemphigus)

Bullous pemphigoid is probably the most common blistering disease affecting elderly individuals, usually over 60 years of age. The circulating antibodies in this autoimmune disease attack the antigens of the stratum lucidum of the basal membrane, which triggers the complement cascade and formation of subepidermal blisters.

Clinical picture: The blisters begin to form on only vaguely circumscribed erythematous patches or (less often) on the normal skin. After the blisters burst, erosions with a tendency of spreading into the periphery appear. The oral mucosa is affected only rarely, usually only secondarily, after the cutaneous manifestations. The course of the disease is prolonged, with spontaneous remissions and good prognosis. Nikolski's sign is absent, the Tzanck's test is negative.

Dif. dg.: Pemphigus vulgaris, dermatitis herpetiformis Duhring, EEM. Unlike in the benign mucosal pemphigoid, Type VII collagen is not detected in immunoblotting; BP 180 and BP 230 are however present.

Th.: Systemic administration of corticosteroids.

Dermatitis herpetiformis (Duhring-Brocque disease)

This disease is a chronic dermatitis associated with gluten-sensitive enteropathy, which can however remain asymptomatic. An association with HLA antigens (HLA-B8, DR3 and DR7) has been proved in up to 90 % of patients. It can occur at any age (even in children), it however manifests mostly between 20-50 years of age with men being affected more often.

Etiopathogenetically, the disease is caused by an incorrect response of the immune system on gluten antigens (gluten Ags); of the complex of antigens, gliadin appears to be the most important. A chronic inflammatory reaction with production of IgA antibodies against gliadin occurs in the small intestine. Through an alternative pathway, the complement cascade is activated, the chemotactic factors are produced and leukocytes immigrate into the papillae of corium. After the death of these cells, their enzymes are released, epidermal cells separate from the corium and a subepidermal blister is formed.

Clinical picture: Symmetrical papulovesicular eruptions appear on the skin – most commonly, above limb extensor muscles and in the sacral region. The manifestations are profoundly itching, their intense scratching often leads to the formation of excoriations or crusts. The oral cavity is affected in 10-20 % of patients, usually only secondarily, after the primary manifestations on the skin appeared. The most common structure in the oral cavity are macropapules; vesicles or erosions similar to aphthous ulcers can however also appear. The palate, tongue and buccal mucosa are more commonly affected than gingiva, lips or tonsils. In 10-20 % of patients, the enteropathy manifests clinically.

Dg.: Histological proof of subepidermal blister, a direct proof of IgA antibodies against smooth muscle reticulin by immunofluorescence.

Th.: Gluten-free diet, sulfones and sulfapyridines.

Epidermolysis bullosa

This term describes a group of rare diseases causing easy formation of intra- and subepidermal blisters on the skin and oral mucosa.

Congenital epidermolysis bullosa (epidermolysis bullosa congenita, EBC)

The disease, also known as the “butterfly disease”, is a rare congenital disease further dividing into several subtypes.

Clinical picture: The blisters on the skin as well as on mucosa arise spontaneously or only upon application of slight pressure or friction. After the blisters break, painful open lesions appear. During healing, scars and contractures appear.

Acquired epidermolysis bullosa (epidermolysis bullosa acquisita, EBA)

This rare blistering disease causing subepidermal blisters usually affects adults over 50 years of age. The pathogenesis may include both inflammatory and non-inflammatory mechanisms, including immune ones.

Clinical picture: The manifestations of the disease are very diverse, especially in the first stages when they can mimic almost any other blistering disease. Gradually, however, the typical picture with extreme skin fragility develops, which is combined with traumatic formation of blisters and erosions healing by scars. Most commonly, the manifestations affect the dorsum of the hands and extensor surfaces of the limbs. In one third of patients, erosions with subsequent scarring appear in the oral cavity as well, rarely also in the larynx and in the esophagus.

Dg.: It is very difficult to distinguish it from pemphigoid – both diseases form subepidermal blisters and in the region of the basal membrane, they accumulate IgG and C3 component of the complement. Indirect immunofluorescence assay can help distinguish those diseases – in EBA, the circulating immunocomplexes bind to the sublamina densa while in pemphigoid, they bind to the lamina lucida of the basal membrane. In differential diagnosis, immunoblotting can be used and if Type VII collagen is found but not BP 180 and BP 230 proteins, EBA can be distinguished from both the bullous and benign mucosal pemphigoids.

Th.: Difficult; a combination of corticosteroids and cytostatics is used (however, resistance to therapy is a typical characteristic of the disease).

Lupus erythematosus (LE)

Lupus erythematosus is a chronic inflammatory autoimmune disease with a variable spectrum of clinical manifestations, from isolated mucocutaneous lesions to their combination with systemic manifestations. The etiopathogenesis remains poorly understood, the most likely explanation involves a failure of regulatory mechanisms responsible for autotolerance.

Discoid lupus erythematosus (DLE)

DLE is the most common chronic form of the disease. Its course is slow, manifestations are in particular in the orofacial region, on the scalp and/or external ears but can also appear elsewhere on the skin. The cutaneous manifestations are especially apparent on the exposed parts of the body and typically include livid papules and patches with a marked follicular hyperkeratosis. In the centres of the foci, firmly adherent scales are formed. When the scales are removed, keratin plugs reaching down to the mouths of the follicles can be found on their bottom. The patches are well circumscribed and separated from the surrounding healthy skin; where the disease is advanced, skin atrophy and teleangiectasia may develop (clown's face).

Erythema centrifugum is a characteristic symptom, typically localized above the root of the nose where it forms a well-known butterfly-like pattern with itching and burning. The oral mucosa in DLE is affected in approximately 15-25% of patients, usually together with skin lesions, although rare cases where only the oral mucosa is affected can also occur. LE manifests on the oral mucosa as discoid atrophic plaques, which are red in the centre. The lesions are well circumscribed with whitish edges, slightly elevated above the surrounding mucosa. In the centre of the enanthema, teleangiectasia, erosions or even ulcerations may occur. The buccal mucosa is most commonly affected, followed by lower lip, palate, gingiva and tongue. Intraoral manifestations are very similar to lesions occurring in oral lichen planus. A sign that may help in distinguishing LE from oral lichen planus is a netlike pattern of the edges of LE lesions (while the whitish colour of lichen lesions is rather continuous).

Laboratory testing: Various antibodies can be detected in the serum (antibodies against DNA, histons, non-histon RNA-bound proteins or against the nuclear membrane antigens). Immunofluorescence methods can help detect subepidermally deposited immunoglobulins.

Th.: For treatment of oral lesions, local application of steroids in orabase paste. Systemic treatment includes steroids and antimalarial drugs.

Systemic lupus erythematoses (SLE)

SLE is a typical example of a multisystemic autoimmune disease affecting internal organs. Skin symptoms may or may not be present. The disease can be acute, with rapid onset, or chronic, initially latent disease with tendency to recur. Many internal organs can be affected, including those of cardiovascular and gastrointestinal system, followed by lungs, kidneys, joints and nervous system. The disease is often accompanied with general symptoms such as fever, loss of weight and lymphadenopathy. The presence of butterfly-like exanthema (butterfly rash) in the face, affliction of kidneys (glomerulonephritis) and presence of antinuclear factors are important for diagnosis. The oral mucosa is affected in 30-45 % of patients. Extensive painful erosions or ulcers, surrounded by a white or red zone are observed. Petechiae, haemorrhages (due to thrombocytopenia) and xerostomia are often present. A less common manifestation is represented by white hyperkeratotic lesions that may be

difficult to distinguish from other white lesions in the oral cavity. This is especially true in subacute stages when the systemic symptoms may be missing or only slightly expressed. The palate, lips and buccal mucosa are the most commonly affected sites.

Laboratory proof: See DLE.

Th.: Due to the serious nature of the disease, systemic steroids, antimalarial drugs, immunosuppressants or, if necessary, plasmapheresis.

Psoriasis (psoriasis vulgaris)

Psoriasis is a relatively common chronic disease affecting mostly the skin – it only rarely affects the oral mucosa. If oral symptoms are present, it is almost exclusively accompanied by parallel serious skin problems, which makes the diagnosis, to a certain degree, easier. The pathogenesis of psoriasis has not yet been fully explained, it is assumed that disorders of the normal epidermal development play a role, leading to epidermal hyperproliferation, alterations in skin cells maturation, vascular and inflammatory changes. Psoriasis is genetically determined, polygenic heritability has been suggested. Various provoking factors may trigger the onset of the disease, including various infections, mechanical or chemical injury to the skin, stress, smoking and many others.

The skin lesions are most commonly present in the areas of extensor muscles over joints (particularly elbows and knees), in the lumbar region, scalp and nails. The skin is thickened, dry, scaly, silvery white. Several types of psoriasis (annular, circinate, guttate, nummular and pustular) can be distinguished according to the morphology of skin lesions. On the oral mucosa, the clinical picture of psoriasis is both rare and variable. Whitish, dry desquamating patches can be observed in the vermilion zone that can lead to pinpoint bleeding. Whitish round patches can be found on the buccal mucosa where the desquamation is obviously not present due to maceration. The tongue often shows smooth patches lined with whitish hyperkeratotic filiform papillae. Ring-like lesions on the sides and bottom of the tongue may resemble the annular form of cutaneous psoriasis. The changes on the oral mucosa do not cause any subjective problems. Interestingly, the clinical and histopathological picture of psoriasis and geographic tongue are similar, which leads some authors to a conclusion that the geographic tongue is in fact a mucosal manifestation of psoriasis.

Th.: Mucosal problems of psoriasis do not need any treatment, they regress spontaneously and faster than changes on the skin that are subject to a complex therapy by dermatologists (PUVA, steroids, methotrexate, cyclosporine, retinoids).

Sjögren syndrome

A significant role in pathogenesis of this chronic disease is probably played by HTLV-1 viruses affecting lacrimal, salivary and other exocrine glands, reducing the secretion of these glands. This disease predominantly affects women in their 4th to 5th decades of life and is characterized by xerostomia and dry keratoconjunctivitis. New clinical, serological and genetic criteria are applied to

distinguish two forms of the disease: primary and secondary. The Sjögren syndrome (SS) is considered primary if it is not accompanied by disorders of the connective tissue (collagenosis) and secondary if it coexists with a disease of the connective tissue such as rheumatoid arthritis, SLE, polymyositis, primary biliary cirrhosis, thyroiditis or vasculitis. Besides symptoms of the eye (keratoconjunctivis sicca) and joints (progressive polyarthritis often develops), symptoms can also occur in the oral cavity – in particular insufficient salivation, making swallowing of solid foods and speaking difficult. The xerostomia manifests especially on the lingual mucosa where atrophy of both filiform and fungiform papillae can be observed, which may lead up to the clinical picture of smooth tongue. The oral mucosa can be erythematous, dry with desquamation of the superficial epithelial layers, often accompanied by angular cheilitis and increased tendency to developing caries of teeth. Parotic glands may be enlarged in some patients. The prognosis is uncertain, Sjögren syndrome is (along with helicobacter-associated gastritis and Hashimoto's thyroiditis) considered a precancerosis of the B-MALT lymphoma (mucosa-associated lymphoid tissue lymphoma).

Dg.: Sialometry (Škach's test) is used for determining the production of saliva. Ultrasound, scintigraphy and sialography can also be employed, as well as lab tests for various antibodies. Biopsy of minor salivary glands from the lower lip should be performed to search for signs of mononuclear infiltrate with periductal distribution in patients with primary SS and with perivascular distribution in patients with secondary SS. Reduced secretion of salivary glands can be also determined by an ophthalmologist using Schirmer's test or using specific staining (Bengal red). See Fig. 9 for overview of criteria for establishing diagnosis of the Sjögren syndrome.

Th.: Treatment is symptomatic, includes receiving of every piece of food along with liquid (in particular dry foods), maintaining a strict oral hygiene (prevention of the increased tendency to caries) stimulation or substitution of saliva production and protection of conjunctiva with artificial tears. If the Sjögren syndrome represents a manifestation of a systemic disease, its treatment forms a part of the complex therapy.

Dif. dg.: Chronic interstitial sialoadenitis, affecting the submandibular salivary gland, can have similar symptoms in the oral cavity. It is associated with parenchymal sclerotization with a marked lymphocytic infiltration (it is often misdiagnosed as neoplasia – so-called. Küttner's tumour).

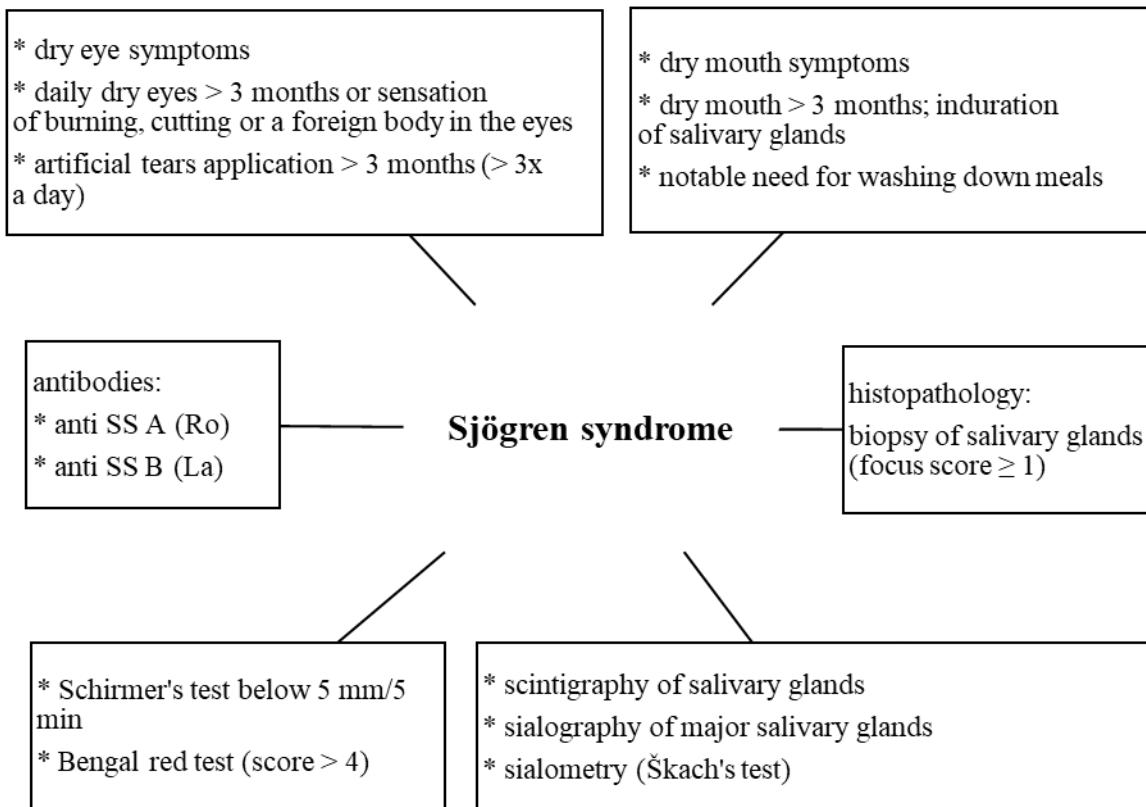


Fig. 9: To establish the diagnosis of Sjögren syndrome, at least 4 criteria must be met, one of which must be a positive biopsy or positive detection of antibodies (diagram acc. to Ciferská et al., 2000; Slezák et al., 2003)

6.1.3. Immune system-associated stomatitides

Oral lichen planus

Lichen planus is a chronic inflammatory disease of unclear etiology with a likely immunopathological etiology. It occurs as lichen ruber planus on the skin, as oral lichen planus in the oral cavity and it can also manifest on other mucosal surfaces. So-called „lichenoid lesions“ (or „lichenoid reactions“) are very similar in appearance and can be either of contact origin (dental materials) or represent manifestation of induced reactions (antidiabetic, antihypertensive drugs or NSAIDs). The chronic form of the chronic graft versus host disease (GVHD) is of similar appearance, it is also possible to consider chronic hepatitis.

To distinguish a typical oral lichen planus (OLP) from an oral lichenoid lesion (OLL), clinical and histopathological criteria were set by WHO (1973, further modified in 2003). The clinical criteria for OLP require a presence of bilateral lesions that can be more or less symmetrical and the presence of lacy, reticulated structure. Erosive, atrophic, bullous and plaque-like lesions are only accepted as a subtype providing the reticulated lesions are present. Histopathological criteria for establishing OLP

diagnosis require the presence of a band-like lymphocytic infiltrate below the basal membrane (hydropic degeneration of basal layer cells) and the absence of epithelial dysplasia. If either clinical or histopathological criteria are not met, the changes on the mucosa are termed as OLL.

OLP is associated with disorders of epithelial keratinization (hyperkeratosis) causing the whitish discoloration of the mucosa. Mucosal changes often (in about 25 % of cases) constitute the only manifestation of this disease. Oral mucosal manifestations occur in 50 % of patients with skin lesions. Individuals of all races can be affected, the disease is more common in females and the highest prevalence (approx. 70 %) falls within the age category of 30-60 years. The etiopathogenesis is not fully explained, although more recent findings suggest the role of autoimmune mechanisms. This theory is supported by the occurrence of OLP as a disease associated with various autoimmune conditions as well as by the presence of cytotoxic lymphocytes, Langerhans cells and expression of HLA class II antigens (DR) or by increased expression of some adhesion molecules (ICAM-1 or VCAM-1) by keratinocytes or squamous epithelial cells.

Clinical picture: small, flat polygonal papules form on the skin, initially red (hence the term lichen ruber planus) and gradually turning into purplish colour. Sites of predilection include the skin on flexors of the forearm and wrist, sacral region, back, lateral sides of the neck, less commonly distal thirds of the lower leg.

The basic structure on the oral mucosa is a shiny, flat, whitish papule. The papules can be isolated or form groups, thus creating whitish oval patches (lichen annularis). On the buccal mucosa, porcelain-like whitish reticulated patches that can be also arranged in a garland-like pattern (lichen reticularis) are more common. Whitish bands radially project from white lesions on the vermilion zone. Besides the most common reticular form, papular and plaque form of the disease (also with a character of white lesion), atrophic, erosive, ulcerative or bullous (erythematous appearance or form ulcers covered with white fibrin pseudomembrane. Occurrence of lesions in the oral cavity can be associated with lesions in the genital area (vulvo-vagino-gingival syndrome).

The course of the disease can be asymptomatic, a chronic course with remissions and exacerbations is however more common. On the skin, patients mostly complain about itching of various intensity while on the oral mucosa, the complaints are rather about burning sensation and irritation after contact with usual diet. Erosive and bullous forms can be painful. Diagnosis of lichen is relatively simple if the lesions have their typical appearance, it can be however (and often is) mistaken for leukoplakia in clinical practice (especially if the lesions form continuous whitish plaques).

Histology: Hyperkeratosis, hypergranulosis, irregular acanthosis, hydropic degeneration of basal cells and the presence of apoptotic Civatte bodies can be found. The lichenoid band-like inflammatory infiltrate below the basal membrane is formed by lymphocytes and histiocytes. Immunofluorescence can reveal predominantly linear deposits of fibrinogen along the dermoepidermal junction. The Civatte bodies are usually positive for IgM.

Th.: No causal therapy is available, symptomatic (usually local) treatment can bring relief – administration of corticoids in an oral paste/mucoadhesive patch; if need be, depot injections of corticoids can be applied. Corticoid treatment can be augmented with levamisole; levamisole monotherapy is also a suitable option in patients who cannot use corticoids (Won et al., 2009). If lesions are asymptomatic, the therapy is not necessary. Non-irritating food is recommended, along with inert (baby) toothpastes; the use of alcohol containing mouthwashes should be avoided. Washing the mouth with lukewarm sage infusions is often soothing.

Dif. dg.: The presence of isolated lichen papules on the edge of the patches is a sign important for differential diagnosis (immunohistological methods provide reliable diagnosis). Similar manifestations include so-called lichenoid allergic reactions, graft versus host reaction, or mucosal reaction to formaldehyde-releasing substances. Lesions with whitish margins can develop in lupus erythematoses; the rare manifestations of psoriasis in the oral cavity can resemble the annular form of lichen. The prognosis with a view of survival is relatively favourable (malignant transformation occurs in only approx. 2 % of patients, usually those with more serious, erosive forms of disease, the prognosis toward full recovery is however unfavourable).

Oral lichenoid lesions (lichenoid reactions of the oral mucosa)

This kind of lesions is probably the most common type of manifestations of intolerance of both metallic and non-metallic dental materials. Whitish lesions of reticular appearance are typical, mostly occurring on the buccal mucosa, less commonly on other sites (labial, lingual mucosa), always on the site of contact with the dental material (note that when the mouth is open during examination, points of contact differ from those when the mouth is closed!). The edges are indistinct, the surrounding mucosa is often intensely erythematous, the mucosa can be sensitive (but not painful).

Drug-induced lichenoid reactions of the oral mucosa occur most commonly during treatment with antihypertensives, non-steroidal antirheumatic drugs and antidiabetic drugs (so-called Grinspan's syndrome, i.e., combination of diabetes mellitus, lichen planus and essential hypertension). In HIV-positive individuals, such lesions can occur during treatment with zidovudine and ketoconazole. The chronic form of the graft versus host disease can be of similar appearance, as well as some chronic hepatopathies.

Erythema multiforme (erythema exsudativum multiforme Hebrae, EEM)

EEM is a systemic chronic inflammatory disease of the skin and mucosa with acute exacerbations. The term is considered rather as a descriptive term unrelated to the etiology and nature of the affliction. EEM develops in genetically predisposed individuals as a result of an immune reaction to external factors. The etiology includes an allergic component (although the disease is not considered allergy) and manifests as eruption of papules or pustules on the skin and changes on the mucosa of the oral cavity (only skin, only mucosa, or both can be affected). EEM is often associated

with the use of some drugs (ATBs, barbiturates), local cosmetic products (toothpastes, mouthwashes lipsticks), or can be associated with a post-infection reaction (herpes, streptococci). A seasonal occurrence with maxima in spring and autumn is typical, as well as the predilection to young people (particularly men). EEM starts usually with brick-red sharply circumscribed spots on the skin, later developing into blisters, usually arranged in (often concentric) circles. The itching exanthema is often notably symmetrical, blisters can be large and covered (after bursting) with a thick haemorrhagic crust. Extensive mucosal erosions covered with fibrin pseudomembranes can manifest suddenly anywhere in the oral cavity. In the vermilion zone, haemorrhagic crusts can develop. They are accompanied by major subjective complaints and worsening of the patient's overall condition (in particular idiopathic forms can be fatal). The disease has a tendency to recur and deeper defects are associated with risk of developing secondary infections. It is often associated with hypersalivation, bad breath and heavy coating of the tongue.

Apart from changes in the peripheral blood count (leukocytosis and lymphopenia), other internal and immunological examinations usually reveal only minimum deviations from normal.

Histology: mucosal necroses, vacuolar degeneration of the basal layer and/or subepithelial blisters are found.

Th.: Therapy is based on the use of (non-steroidal) anti-inflammatory drugs that can be combined with ATB mouthwashes. If the disease progresses to a serious condition, short-term application of corticoids is recommended, ideally with patient hospitalization.

Stevens-Johnson's syndrome

One of the clinical forms of the erythema multiforme is Stevens-Johnson's syndrome, manifesting on the mucosa more than on the skin. This serious bullous form of the disease has a particular predilection for the vermilion, which is combined with complaints of conjunctiva, urethra, perianal region and genitals. The syndrome is most commonly drug-induced (ATBs – sulfonamides, antiepileptics, carbamazepine), or resulting from a post-infection reaction (herpes).

Recurrent aphthous stomatitis

Recurrent aphthae (stomatitis aphtosa, habitual aphthae, benign aphthae, recurrent aphthous ulcers, RAS) are the most common stomatitis, affecting a quarter to a fifth of worldwide population, without a predilection to a certain age or sex. Many theories about the origin of the disease have been developed, none of which has however been confirmed so far and the cause of the disease has therefore not been satisfactorily explained. At present, we rather speak of predisposing factors than about etiological factors, such as:

a) heredity – the theory about involvement of genetic factors is backed by the familial occurrence with an incidence rate of 50 % in first degree relatives. Some associations between the development of aphthae and some HLA molecules have also been suggested.

b) age – the disease mostly occurs in childhood and puberty; a first manifestation after 35 years of age is relatively rare, the disease is almost non-existent in elderly, toothless patients.

c) immunopathological conditions – it is currently assumed that disorders and dysregulations of the immune system play a significant role in the development of the disease. Immunological studies report that the destruction of the epithelial cells of the oral cavity during recurrent aphthae appears to be a terminal stage of an immunopathological process, the course of which is known but reasons are not. The immune system is probably activated through production of activating cytokines (such as TNF- α , IL-1, IL-6) by keratinocytes of the oral mucosa as well as by Langerhans cells, dendritic cells and lymphocytes. Chemotactic stimulation leads to a transfer of immunocompetent cells to the site of the lesion-to-be where lytic enzymes are released, which leads to the necrosis. The reason for marking some epithelial cells for destruction by the local immune reaction is however not known.

d) infections – the autoimmune cross-reaction theory based on the similarity of oral streptococcal antigens with mucous structures has been rejected. However, it is generally assumed that some conditionally pathogenic oral microorganisms that contaminate existing mucosal defects have a secondary effect and may deteriorate the progression of the disease.

e) endocrine effects – hormonal imbalance during the menstrual cycle is expected to play a major role (exacerbation of aphthae during the menstrual cycle), unambiguous results are however not available.

f) psychological effects – aphthae may possibly recur through the neuroendocrine pathway

g) local factors – aphthae often develop on the previously injured oral mucosa (cheek biting, injury caused by food or tools). The assumption of traumatic etiology is supported by the facts that the aphthae form at sites of frequent injuries to the oral mucosa and that aphthae are almost non-existent in toothless patients or at sites with continuous keratinization (gingiva, hard palate).

h) systemic diseases (including GIT diseases, hypovitaminoses, sideropenic anaemia, neutropenia) – when lesions resembling recurrent aphthae are found in patients with systemic diseases, it is better to use the terms “aphthous-like ulcers” or “aphthoid ulcerations”.

Classification: Aphthae can be counted among a group of diseases characterized by a loss of tissue by erosion/ulceration. Depending on the course of the disease, they can be classified as transient (spontaneously healing within approx. 3 weeks) and persisting form (healing longer than 3 weeks). The disease occurs in three principal clinical forms:

1) minor aphthous ulcers – the most common form of the disease (approx. 80 % of all cases). The first manifestation is usually in the childhood, predominantly in women. Familial occurrence is common,

2) major aphthous ulcers (peradenitis mucosa necrotica recurrens) – a less common form (approx. 10-15 % of cases), always preceded in the patient’s history by the occurrence of minor aphthae. The appearance is atypical, it is usually a larger (over 1 cm) and deeper (can penetrate up to the submucosa) solitary defect with marked inflammatory changes in the surroundings of the ulcer. It

occurs most commonly on the sides of the tongue, in some cases on the buccal or labial mucosa. Healing takes a long time (months) and often results in scarring.

3) herpetiform type – the rarest form (less than 10 %). Clinically, it is similar to the herpetic gingivostomatitis, but the affliction of gingiva and systemic symptoms are absent. Recurrences are rare, remissions often last for many years.

The common finding in all forms is the primary mucosal defect – the aphthous ulcer. Macroscopically, it presents as an oval or round erosion with the base covered with a yellowish-grey fibrin coating and a distinct red margin. The size can be anywhere from a couple of millimetres up to several centimetres. In larger defects, a collateral oedema of adjacent soft tissues and regional lymphadenitis can be observed. Alteration of the patient's general condition is rare. Hyperesthesia can occur during the process of developing of the aphthous ulcer, replaced with intense pain in the erosion stage (possibly caused by the irritation of the nerve endings by released inflammatory mediators – IL-1, PGE2). Aphthae are mostly formed sporadically with various time intervals between exacerbations (sometimes even several years), they can however also present as multiple ulcers (several unhealed ulcers are present at any given moment).

Dif. dg.: The site of the ulcers helps distinguish them, especially from herpetic infections.

Most commonly, aphthae develop in the non-keratinizing parts of the oral mucosa, in particular on the labial and buccal mucosa in the vestibulum, on the sides of the tongue, on the oral floor, soft palatine mucosa and palatine arches. Recurrent aphthae are usually well circumscribed, with an inflammatory margin (unlike herpetic efflorescences that occur in groups and have irregular margins).

Distinguishing minor aphthous stomatitis from other diseases of the oral cavity is usually not difficult due to its typical appearance, localization of the manifestations and typical course of the disease with remissions and recurrences.

Major aphthosis can be clinically misdiagnosed as various other diseases that manifest in the oral cavity by forming deeper defects.

Herpetiform aphthae are probably the one form of recurrent aphthous stomatitis that is the most difficult to diagnose correctly. It must be especially distinguished from: viral stomatitis, autoaggressive diseases such as pemphigus or pemphigoid, secondary stage of syphilis, and toxic/allergic reactions.

Laboratory examination: Routine and specific immunological lab tests (such as ASCA IgA, ASCA IgG and ANCA antibodies) are performed to exclude celiac disease, Crohn's disease, ulcerative colitis, Behçet's syndrome, clinical neutropenia, vitamin B12 deficiency and EEM. To exclude herpetic etiology, serological tests detecting anti-herpes simplex virus antibodies (IgM and IgG) can be used.

Th.: No specific therapy is available. Establishing the correct diagnosis followed by treatment of the disease rather than of other similar diseases is of utmost importance. The treatment is largely symptomatic and aims at reducing patient's subjective discomfort, acceleration of the healing of the mucosal defects, reduces the development of new manifestations; moreover, it can help prolong the period between exacerbations.

Local therapy: It is indicated in patients at the time of the acute manifestations, aiming to reduce the patient's discomfort and speeding up the healing of efflorescences that have already developed. Local therapy can be administered in every patient with any form of recurrent aphthae. Local anaesthetics, antiseptics. ATBs, anti-inflammatory drugs, bioadhesives, mucoprotectives and other substances non-specifically supporting healing and epithelisation of the lesions (as well as their combinations) can be used.

Local anaesthetics: For topical superficial application, both ester (procaine derivatives – 1 % tetracaine, 20 % benzocaine) and amide type (2-10 % lidocaine) anaesthetics in the form of sprays, gels or solutions are used. Lauromacrogol – a drug with anaesthetic and sclerotizing effect – can be also applied. When prescribing local anaesthetics, it is necessary to inform the patients about the possible toxicity (hence, it is necessary to use them only when necessary, especially before meals) and about the risk of injury of the insensitive mucosa by mechanical or thermal irritation.

Antiseptics: CHX or hexetidine, triclosan, benzydamine. Usually, a short-term application (5-10 days) in the form of solutions or gels is prescribed. Care must be taken regarding possible interaction with lauryl sulphate (present in most toothpastes) and to apply the anaesthetic only for 30-60 minutes after cleaning the teeth. A long-lasting adhesion to the oral mucosa is a significant advantage of chlorhexidine (possessing marked antibacterial, antiviral and antifungal effects) as it allows rinsing the mouth only twice a day. Hexetidine blocks, by means of competitive inhibition, the synthesis of thiamid diphosphate – a coenzyme necessary for life processes of microorganisms – and such disruption of glycolytic processes helps reduce microbial decay of remnants of food in the oral cavity. It is used in the form of solution or oral spray three times a day.

NSAIDs (non-steroidal anti-inflammatory drugs): benzydamine and preparations containing salicylic acid. Benzydamine has anti-inflammatory, analgesic, anaesthetic and antimicrobial effects. In the oral cavity, it is applied at a 0.15 % concentration, 4-6 times a day. Salicylic acid: the mechanism of action lies in blocking cyclooxygenase – an enzyme participating in the synthesis of prostaglandin and other derivatives of arachidonic acid. It can be applied locally as a gel. It is less effective than benzydamine.

Corticosteroids: their use is limited to the treatment of defects that have already developed – in particular in the case of major aphthae (both systemic and local contraindications including viral, bacterial and fungal stomatitides must be considered). Prior to the application of the gel with corticosteroids (2-4 times per day), it is necessary to blot up the lesion and the surrounding mucosa. Depot injection of corticosteroids into the soft tissues surrounding the lesion can be considered in

some cases, in particular in major aphthae (aphthosis major). This therapy must be however limited to specialized departments due to the possible local and systemic side effects.

Bioadhesives and mucoprotectives: cellulose hydrogels and polyacrylates are used to cover the lesion with a film, which relieves the pain. They can also serve as carriers of various treatment agents, which facilitates a longer exposure of the lesion to the active substances. A mucoprotective medication sucralfate has the capability to stick to the damaged mucosa and protect it, which accelerates epithelial regeneration, improves microcirculation and locally stimulates the GIT mucosa. Besides the therapy of erosive lesions of the esophagus, stomach or duodenum, it is also used in therapy of frequently recurring aphthae.

Other medications that can be individually used at specialized departments are preparations containing cyclosporine A, recombinant interferon alpha or prostaglandin E2.

Systemic therapy: It is only administered in some patients with aphthosis major, with herpetiform recurrent aphthae and with recurrent minor aphthae with severe attacks and many ulcers. The aim of the therapy is to relieve patients' discomfort and to prevent recurrences. Substances for systemic administration include B vitamins (B₁, B₂, B₃, B₅, B₆, B₉, B₁₂), for example so-called Škach's vitamin therapy. This treatment method is based on bolus administration of preparations containing vitamins B₆, B₉ and B₁₂ with intervals between treatments, for example using a scheme 3 weeks of bolus treatment – 3 weeks of no intervention – 3 weeks of bolus treatment – 6 weeks without intervention – 3 weeks of treatment. Vitamin B₁₂ is administered intramuscularly (300 µg on alternate days), Pyridoxin 3x20 mg + folic acid 1x10 mg a day (active folate is preferred because the enzyme methylenetetrahydrofolate reductase is defective in a high percentage of the population). Other drugs may be prescribed, including antihistamines, vasodilators, corticoids, immunosuppressants or immunostimulants, lysine and Fe-containing preparations. Most remedies for systemic administration (usually long-term use) are reserved for specialized departments and therefore do not need to be listed here.

Preventive measures and other therapy: Prevention of local trauma to the oral mucosa, modification of the diet, elimination of known allergens, avoiding stressful situations, laser or ultrasound therapy.

Behçet's syndrome

Some authors count Behçet's syndrome (aphthosis maligna) among recurrent aphthae. Unlike the "normal" aphthae, however, Behçet's syndrome is a serious systemic disease of unknown etiology. It develops from vasculitis and is associated, besides ulcerations in the oral cavity, with many extraoral manifestations. Similar to many other diseases, major criteria (recurrent ulceration in the oral cavity) and minor criteria (recurrent genital ulcerations, skin and eye lesions and formation of a pustule – pathergy – on the site of a puncture) apply. Some authors divide the disease according to the clinical picture into 3 types: mucocutaneous form (affecting the oral cavity, genitals, conjunctiva and

skin), arthritic form and neuro-ocular form (affecting eyes and/or nervous system along with mucocutaneous or rheumatic complaints).

Th.: Combined (corticoids, cytostatics).

Touraine's aphthosis

This disease counts among the so-called chronic aphthoses. In this disease, ulcerations similar to those observed in the oral cavity develop also in the stomach, bowels, in the genital area and respiratory tract. In addition, eyes or central nervous system can be affected. This disease is also one of systemic multiorgan diseases with only symptomatic treatment.

6.1.4. Immunodeficient conditions

Any component of specific and/or non-specific immunity can be missing in the organism, only present in abnormally small amounts or not function properly. Common manifestations of immunodeficient disorders is lowering of the immune barrier resulting in increased susceptibility to infections with serious course reacting only to a limited degree to the usual antimicrobial therapy. If humoral immunity is compromised, suppurative (pyogenic) infections predominantly appear; if cellular immunity is affected, viral, fungal or parasitic infections are more common. Specific immunodeficiency conditions are categorized into primary and secondary types. Primary ones include for example DiGeorge syndrome (limited development of the thymus and parathyroid glands, resulting in T-cells deficiency and other disorders) or congenital (Bruton's) X-linked agammaglobulinemia associated with an inability of the organism to produce immunoglobulins.

Secondary immunodeficiency conditions occur in some diseases (AIDS, malignant lymphomas), after intensive immunosuppressive, cytostatic or radiation therapy. Both humoral and cellular immunity are usually affected. From the dentist's perspective, chronic mucocutaneous candidosis representing a combined disorder of both humoral and cellular immunity must be mentioned.

Changes in the oral cavity in patients with HIV infection/AIDS (Acquired Immune Deficiency Syndrome)

The Acquired Immune Deficiency Syndrome was first described in 1981. The HIV virus attacks especially CD4+ T-cells and macrophages. It multiplies inside them, destroys them and thus significantly reduces their levels in the body of the infected person. This decline gradually leads to the immune system failure, which manifests by recurrent infections and reduced anticancer immune response, which results in higher susceptibility to some types of tumours. The range of HIV manifestations is extremely wide and can coincide with many diseases of the oral mucosa of other etiologies. Infectious diseases of the oral cavity often appear already in the ARC (AIDS related complex) stage and are common once the full scale AIDS sets in. None of these manifestations

however count among clinical criteria for diagnosing HIV infection. From both the diagnostic and epidemiological perspectives, the fact that the afflictions of the oral mucosa can clinically manifest months before other HIV symptoms poses a problem. The oral manifestations thus can represent the first clinical symptoms of the disease but none of those is specific for the HIV infection! Diseases of various etiologies can occur simultaneously in a single patient but this is usually only the case when the CD4+ T-cell count is below 200/mm³; in patients with higher values of the CD4+ T-cells (200-400/mm³), only one type of intraoral affliction is usually found.

Infectious diseases/complications of the oral mucosa in HIV positive patients can be categorized into viral, bacterial and fungal infections. The course of the diseases is usually atypical, prolonged, with frequent recurrences and often with coincidence of multiple infections (e.g. herpetic and fungal at the same time); their treatment is difficult.

Viral infections in the oral cavity in HIV/AIDS patients

Herpes viruses are the most common etiology of such diseases; papovaviruses or poxviruses can however also affect the mucosa. In HIV patients, the infections typically last longer and have a more serious course than in HIV negative individuals.

Herpetic gingivostomatitis (gingivostomatitis herpetica)

This disease is often more extensive with serious course. The healing takes usually longer, even if systemic antiviral therapy is administered.

Herpetic stomatitis (stomatitis herpetica)

Similar to the above, the disease is also usually more serious with longer duration, is always very painful and recurs more frequently. The disease can turn chronic. Acyclovir can be administered to prevent possible recurrences.

Herpes simplex (labialis)

Herpes simplex often spreads from the vermilion zone onto the facial skin, which can be affected to various degrees. The lesions can persist for a long time despite the therapy.

Herpes zoster facialis

This disease also recurs frequently and in the oral cavity, it can lead even to osteonecrosis of the alveolar bone. Sometimes, multiple sensitive nerves can be affected or the lesions can be bilateral, which is extremely rare in HIV negative patients.

Cytomegalovirus-associated ulcerations

They can develop in patients with seriously reduced immunity and are considered a sign of imminent organ complications (e.g. CMV-retinitis). If they are among the first clinical signs of the immunodeficiency, they can be difficult to diagnose (histopathological verification is needed).

Benign epithelial lesions associated with human papillomavirus (HPV)

Formation of multiple mucosal papillomas with chronic course are relatively common in the oral cavity. The most common ones are the focal epithelial hyperplasia (HPV 13, 32) or condylomata (HPV 6, 11). The genitalia and perianal region are usually also affected (condylomata acuminata).

„Hairy“ leukoplakia

This manifestation of EBV infection manifests on the oral mucosa, most commonly on the tongue. The development of the hairy leukoplakia signifies a poor prognosis and progression of HIV-positivity into the AIDS stage. In more than 80 % of HIV patients who develop hairy leukoplakia, this progression occurs within 30 months of its development.

Bacterial infections of the oral cavity in HIV/AIDS patients

Those are usually infections with mixed flora, mostly anaerobic rods or cocci (*Tanarella*, *Fusobacterium*, *Prevotella*, *Aggregatibacter* a *Parvimonas*) and oral spirochetes (*Treponema* genus).

Linear marginal erythema (HIV-gingivitis)

This gingival lesions are characterized by an intensive 2-3 mm wide erythematous band on the marginal gingiva accompanied by bleeding and formation of petechiae. Etiologically, this inflammation is associated with the presence of the microbial plaque in the oral cavity.

Th.: The therapy is based on a proper and thorough maintaining of the oral hygiene; chlorhexidine type antiseptics can also be used.

Dif. dg.: It histologically differs from the “normal” plaque-induced gingivitis in the absence of inflammatory infiltrate and multiplication of blood vessels in the submucosal connective tissue. The linear marginal erythema must also be distinguished from desquamative gingivitis present as a part of OLP or pemphigoid manifestation

Necrotizing periodontal disease

This disease is described in detail in the chapter devoted to bacterial infections (see Chapter 5.4.1.).

“Bacterial” ulcerations of the oral mucosa

In HIV-positive individuals, deep painful mucosal defects appearing as ulcers often develop (histopathological and microscopic examination is necessary). It is not completely clear whether such ulcers develop as a result of microbial activity or if the microorganisms only secondarily colonize the defects of another etiology.

Th.: Local and systemic ATBs, mucosal anaesthetics before meals.

Specific inflammations

The oral manifestations of TBC in HIV-positive patients have not been sufficiently studied so far. They are however often associated with „multiple-drug resistant“ TBC. Syphilis is relatively frequent among HIV patients (coincidence due to identical routes of transmission). The overall clinical

picture including mucosal changes can be in these patients modified by the immune disorder (lues maligna).

Bacillary angiomatosis

The agent responsible for development of this disease occurring probably only in HIV-positive patients, is *Rochalimaea henselae* (genus *Rickettsia*). It affects in particular the endothelial cells of the capillaries, smaller vessels in the skin and mucosa, or in the internal organs. In the oral cavity, those manifest as erythematous, soft knot-like indurations, which can appear in various sites. On the skins, the disease manifests as maculopapular exanthema that can be accompanied by ulcerations.

Th.: macrolide or tetracycline antibiotics.

Dif. dg.: This disease can be easily mistaken for Kaposi's sarcoma (can only be distinguished done using histopathological examination or by immunofluorescence examination).

Fungal infections in the oral cavity in HIV/AIDS patients

Recurrent candidosis is probably the most common pathology in the oral cavity in HIV patients. The spectrum of the fungal diseases is however wider and even deep, systemic mycoses can manifest there. In the countries with high numbers of HIV positive individuals and AIDS patients, the clinical spectrum of oral candidosis is much wider. The oral candidosis is a typical AIDS symptom of the oral cavity, with whitish margins and pseudomembranes that can develop on the gingiva as well. Symptoms of yeast infection can combine with other infectious and non-infectious pathological manifestations. Other yeasts that can be responsible for the fungal infections include *Cryptococcus neoformans*, *Histoplasma capsulatum*, *Blastomyces dermatidis*, *Rhizopus oryzae* or *R. arrhizus*. We can also consider some other diseases of the oral cavity to represent manifestations of oral candidosis. These so-called „Candida-associated lesions” include besides prosthetic stomatitis also glossitis rhombica mediana a lingua villosa nigra.

Oral candidosis

Practically any of the above-mentioned forms of oral candidosis can manifest in HIV positive individuals. The candidosis often represents a part of a much broader affliction of the GIT and respiratory systems (esophageal candidosis is considered as a diagnostic criterion of the HIV infection). Pseudomembranous forms of candidosis can occur practically on any site of the oral mucosa including gingiva. The chronic atrophic, hyperplastic and erythematous form often lead to superficial but very painful ulcerations that are difficult to diagnose. In HIV-positive individuals, both nodular and papillary forms of the candida infections can occur, which are never present in HIV-negative patients.

Glossitis rhombica mediana (one of the candida-associated lesions) is also often present.

Th.: In particular, 3rd generation azole antimycotics (fluconazole etc.) are used. A combination of systemic fluconazole administration with local application of nystatin or CHX can be administered. After successful treatment, a long-term preventive therapy with fluconazole is recommended.

Dif. dg.: Hairy leukoplakia.

Manifestations of systemic mycoses in the oral mucosa

Systemic mycoses usually manifest as solitary, painful ulcers with oedematous surroundings. Histoplasmosis, cryptococcosis, mucormycosis, geotrichosis and aspergillosis can all occur and usually signify poor prognosis. *Candida dubliniensis* has been recently shown to be also capable to cause oral candidosis in HIV-positive individuals.

Tumours in the oral cavity in HIV/AIDS patients

The collapse of the cellular immunity, which is among other things responsible for anti-cancer defence, leads to a more common development of tumours in HIV-positive patients. The typical tumours include the Kaposi's sarcoma, non-Hodgkin malign lymphomas and squamous cell carcinoma of the oral mucosa, in particular the tongue.

Kaposi's sarcoma

This is the most common tumour in AIDS patients, occurring in approximately 20 % of them. Currently, it is considered a disease of infectious origin caused by human herpes virus HHV-8. It affects primarily the skin, lymph nodes, organs and oral mucosa, with predilection to males (male:female ratio of approx. 8:1). Many papules, nodules and tumorous lesions with purple or livid discoloration appear on the skin. Oral mucosa is affected only in some patients, usually only after cutaneous manifestations of Kaposi's sarcoma. It can however, in rare cases, primarily affect the oral mucosa. Lesions in the mouth can be solitary as well as multiple, usually forming red or red-brown macules or papules, later elevated plaques or small tumours that can ulcerate. Most commonly, gingiva and the oral floor are affected, followed by the tongue, lips and buccal mucosa.

Th.: Radiotherapy, interferon alpha, chemotherapy, surgical excision of small lesions is also possible.

Dif. dg.: Pyogenic granuloma, haemangioma, pigmented moles, malignant melanoma.

Malignant non-Hodgkin lymphomas

These represent the second most common malignant disease in HIV-positive individuals. Most lymphomas originate from B-cells and clinically manifest as inflammatory swelling that can ulcerate. Usually, it affects the gingiva and the palate.

Mucosal afflictions of uncertain etiology in HIV patients

This group includes many afflictions, the most common of which are lesions similar to aphthae (so-called aphthoid ulcerations), drug-induced reactions (ulcerative, lichenoid, toxic epidermolysis) and diseases of the salivary glands.

AIDS-related cystic lymphoid hyperplasia

This disease affects salivary glands (parotid gland in particular). Its symptoms are similar to those of the Sjögren syndrome.

6.2. Changes in the oral cavity associated with systemic diseases

A dentist must bear in mind that some changes in the oral cavity including oral mucosal defects may represent early symptoms of systemic diseases. It is not uncommon that a dentist is the first to suspect a systemic disease. For this reason, it is necessary to know what diseases can represent such first signs and what are the systemic diseases those symptoms can point to, including some diseases of the GIT, endocrine glands, haemorrhagic diseases and metabolic disorders.

The living organism and metabolism consist of a multitude of complex biochemical reactions necessary for energetic supply of the cells and for creating new matter. Undesirable changes can affect any constituents of the metabolism such as the basic substances including sugars, lipids and proteins, as well as other substances such as vitamins, minerals, enzymes and hormones. Metabolic changes are closely related with nutrition disorders – they are associated with the food intake, composition, its processing in the GIT and use in the tissues. The metabolism is also influenced by the endocrine glands, the functional changes of which can lead to mucosal manifestations. Sex hormones also directly influence the morphology of the mucosa and can lead to changes in the oral mucosa both under physiological (puberty, gravidity) and pathological conditions, often in interaction with nervous and immune system.

6.2.1. Changes in the oral cavity associated with diseases of haematopoiesis and vessels

The first symptoms of some blood diseases may manifest in the oral cavity. This is especially true about myeloproliferative diseases, causing excessive growth of immature blood cells. Such cells are functionally impaired and the complications that arise are actually due to the lack of normal blood elements. In addition, these patients are usually treated with a number of drugs that can also have a toxic effect on the oral mucosa.

Diseases associated with the red blood cells

Anaemia

Of many anaemias, the etiology of which can be completely different, only some will be mentioned here, specifically those that are practically always accompanied by manifestations in the oral cavity.

Pernicious anaemia (Addison-Biermer anaemia)

Etiologically, it is caused by a lack of Castle intrinsic factor in irreversible atrophic gastritis. The disease usually manifests around the fiftieth year of age.

Clinical picture: General symptoms result from the anaemic syndrome associated with paleness, exhaustion, weakness and exertion dyspnoea, which is accompanied by tachycardia and systolic murmur. Cardiac hypoxia leads to myocardial steatosis with yellow stripes (so-called tiger heart). Clinically, tongue afflictions (**Hunter glossitis**, Möller-Hunter glossitis) manifest by paraesthesia and burning of the tongue, taste perception can be altered. The disease has three stages. In the first, acute, stage, fissures, erosions and macular efflorescences develop on the lingual mucosa. In the second, subchronic, atrophic changes of the filiform papillae appear and in the third, chronic, stage, atrophy of the mucosa occurs.

Similar changes can be observed in megaloblastic anaemia, the etiology of which is different. Such etiologies may include partial or total gastrectomy, malabsorption syndrome, Crohn's disease, extensive lesions of the intestines by diverticulosis or resection of the bowel where vitamin B12 absorption normally occurs; it can also develop in full vegetarians and in pregnancy in cases of insufficient intake of the folic acid. Atrophic glossitis may be also induced by some drugs such as cytostatics.

People suffering with a relatively common neuroanemic syndrome may develop, in addition to the anaemic symptoms, also neurologic ones. Such symptoms include tendon hyporeflexia, reduced muscular strength and unsteady walking. Mental performance of such patients is often also affected, sometimes to the degree of loss of consciousness. Histologically, signs of demyelination can be found in the lateral and posterior grey columns of the spinal cord, more rarely in spinal ganglions and peripheral nerves.

Th.: Vitamin B₁₂, the treatment is managed by departments of (internal) medicine.

Sideropenic anaemia

It results from Fe deficiency; it is a typical hypochromic anaemia. Mostly, it develops as a "loss-induced" anaemia after chronic bleeding (after menorrhagia in women, after GIT or other organ bleeding in both sexes). Other etiological factors include reduced content of Fe in the diet, Fe absorption disorders or combination of both.

Clinical picture: Anaemic symptomatology (dyspnoea, exhaustion, weakness, faintness, sensitiveness to cold, impaired capability of concentration, irritability, reduced performance, GIT symptoms, loss of appetite). In the oral cavity, atrophic glossitis with absence of papillae is observed. Subjectively, the patients complain about tongue burning or pain (in particular after intake of irritating foods). Fissures and atrophy of the oral mucosa or painful corners of the mouth can also develop. Sometimes, changes on the esophageal mucosa can appear, which can result in dysphagia.

The complex of symptoms occurring on the mucosa of the upper GIT, is summarily termed **sideropenic dysphagia** (*Patterson–Kelly syndrome, Plummer-Vinson syndrome*). This disease is characterized by a combination of hypochromic anaemia, dysphagia (if stenosing esophagitis of the upper esophagus is present), koilonychia (spoon nails), changes in the oral cavity and achlorhydria. Lesions in the oral cavity are the same as those found in sideropenic anaemia with the characteristic atrophic oral mucosa with furrows, possibly also of the oral cavity and esophagus with fissures or erosions of the corners of the mouth. Xerostomia is often present. Based on these defects, leukoplakia and squamous cell carcinoma often develop, which is the reason that this syndrome is considered precancerous. Middle-aged women are the most commonly affected population group.

Th.: Increasing dietary intake of Fe is the key to treatment of this disease. Fe can be administered orally or parenterally.

Aplastic anaemia

The cause of this disease is impaired haematopoiesis in the bone marrow. Both the general and local symptoms are similar to those observed in agranulocytosis.

Polyglobulia (polycythaemia vera, Vaquez-Osler disease)

This disease is the opposite of anaemia. In particular, the deep red to cyanotic colour of the lips, face and oral mucosa is conspicuous. The affected patients suffer with epistaxis and gum bleeding. The tongue is usually smooth, the filiform papillae atrophic. The patient can suffer major bleeding after surgical interventions (e.g. after tooth extraction).

Diseases associated with white blood cells

Leukemia and lymphomas

It is not uncommon for a patient with acute haemoblastosis to visit his dentist due to the problems in the oral cavity first. The most common manifestations include a major induration of the gingiva, which is oedematous, enlarged and hyperplastic (due to inflammatory changes and infiltration of the connective tissue with non-mature blood elements). It can be of livid colour, have a tendency to bleed and it often partially or even completely overgrows the dental crowns. Other manifestations include ulcers with undermined margins, accompanied with bad breath. Necroses can affect the gingiva as well as the tongue and tonsils that may be enlarged so much as to cause respiratory difficulties. Such conditions contraindicate any surgical procedures in the oral cavity. The picture can be modified by the development of opportunistic infections (typically candidosis).

Dg.: Complete blood count must be taken, examination of the medulla and biopsy are necessary for confirming the diagnosis.

Plasmocytoma

Extramedullary forms of plasmocytoma can (albeit very rarely) manifest in the oral cavity (although the manifestations are much more common in the upper respiratory tract – nasal or maxillary sinuses and epipharynx). Knots of greyish discoloration can form on the mucosa and there is a tendency to ulcerate.

Amyloidosis

Primary amyloidosis is a systemic or organ-specific disease belonging into the group of monoclonal gammopathies. Rarely, amyloid may be formed in the tongue, either in the muscles or in the vascular walls. Sometimes, protruding tumour-like deposits can be formed (besides the oral cavity, such deposits can be formed also in the skin, eye and bladder). The mucosa of the dorsum of the tongue is smooth, practically without papillae, with a marked yellowish-grey discoloration. When amyloidosis develops, it is always necessary to anticipate the affliction of the oral mucosa.

Agranulocytosis

This haematologic disease is characterized by a significantly reduced count or complete absence of granulocytes. It can be of idiopathic etiology (primary agranulocytosis) or the causes can be known (secondary agranulocytosis); it is associated with altered immunoallergic reactions to some drugs (some analgesics, antidiabetics, antiepileptics, antirheumatics, antibiotics, etc.). In predisposed patients, such reaction leads after a certain time (a week to several years) to haematopoiesis disorders. Other causes may include some infections of bacterial (TBC, typhus, septicaemia), viral (hepatitis, rubeola, flu), or protozoan (malaria) origin, ionizing radiation, benzene and its derivatives, etc. It is typically associated with marked systemic symptoms such as fever, exhaustion, pain in the throat and/or dyspnoea.

Petechiae and necroses of various extents form in the oral cavity – on the mucosa of the gingiva, soft and hard palate, esophagus, tonsils, sometimes even on the tongue, lips and buccal mucosa. Oral lesions are often associated with increased salivation, mastication can be painful. The necroses can afflict the bone, lead to its sequestration and to loose teeth. When making the diagnosis, it is always beneficial to keep in mind that any time a therapy-resistant ulcerative necrotic gingivostomatitis is detected, haematopoiesis disorders must be suspected. Similar changes are also common in AIDS and other diseases of the immune system. In agranulocytosis, local manifestations in the oral mucosa are almost a rule.

Th.: Treatment of lesions in the oral cavity is local and symptomatic, the systemic therapy is managed by a haematologist.

Dif. dg.: The finding of ulcerative disintegration on the pale background (without erythematous margins and surroundings) is crucial.

Haemorrhagic disorders (bleeding diathesis)

Haemorrhagic diseases manifest by excessive bleeding that can be spontaneous, posttraumatic or following surgical procedures. Such disorders can be congenital (haemophilia, von Willebrand disease, Osler-Weber-Rendu disease) or acquired. Bleeding disorders can be provoked by some drugs (analgesics, antipyretics), infections (increase in the susceptibility of the vascular wall), autoantibodies, etc. In the orofacial region, the symptoms of bleeding disorders are often especially obvious and often represent the first symptom that can bring attention to the possible disorder. Bleeding disorders can be divided into the following groups: disorders of the platelets and vascular wall disorders (both count among primary haemostasis disorders) and coagulopathies (secondary haemostasis disorders).

Thrombocytopenia and thrombocytopathy

The term thrombocytopenia means quantitative changes in the number of thrombocytes while the term thrombocytopathy denotes qualitative defect of the platelets. These defects can be (rarely) congenital but usually, they are acquired. The degree of bleeding depends on the number of functional platelets. Bleeding into the skin and mucosa associated with the development of small petechiae usually occurs (which is never the case in haemophilia!) as well as bleeding into internal organs. The most widely known thrombocytopenia is the idiopathic autoimmune thrombocytopenic purpura (morbus maculosus Werlhof); the clinical picture is characterized by bleeding with formation of petechiae, suffusions and haematomas at various sites including the oral mucosa. Laboratory tests show reduced thrombocyte count and pathological result of the Quick's test, the PTT is normal.

Th.: Therapy is managed by haematologists; local therapy is similar to that in haemophilia.

Coagulopathy

Coagulopathies are caused by a lack of one of the plasmatic factors. Haemophilias are the most common coagulopathies. Haemophilia A is a congenital defect of the pro-coagulation activity of the low-molecular component of the factor VIII while in haemophilia B, the lack of factor IX (Christmas factor) is observed. Both diseases affect males while females are the carriers. A fraction of the diseases can be caused by a new mutation so this disease must be considered even if the patient has no family history of the disease. Haemophilia C is characterized by a defect of the Factor XI (both males and females are equally affected).

Clinical picture: The severity of clinical manifestations is directly proportional to the activity of the coagulation factors in the plasma. Bleeding into the GIT is one of the first symptoms, together with bleeding into the joints and muscles. In the oral cavity, bleeding into the mucosa and muscles occurs, especially into the tongue and the oral floor (especially haematoma formation), and bleeding from the gums. Petechiae do not occur (neither on the skin nor on the mucosa). Bleeding after tooth

extraction can be very dangerous (in these patients, the dentist must not perform any surgical procedure without a previous haematologic examination and patient conditioning).

Dg.: Activity of coagulation factors VIII, IX (XI) is to be tested; PTT is prolonged, Quick test is normal.

Th.: The systemic therapy is managed by haematologists. Dental procedures that can be expected to bleed should be always consulted with a haematologist in these patients. Tooth extraction and other surgical procedures requiring haematological conditioning are usually performed with hospitalization. Such conditioning of the patient may include administration of the missing coagulation factor (or antifibrinolytics). After the procedure, the wound is to be locally treated to reduce bleeding (suture, tissue adhesives).

Intramuscular injections as well as coagulation-affecting drugs (aspirin, NSAIDs) should be avoided.

Acquired coagulopathies are associated with the anticoagulation treatment with coumarins (vitamin K inhibitors), they can occur in disorders of the vitamin K absorption and in serious damage to the liver (disruption of synthesis of coagulation factors).

Vasculopathies

Disorders of the vascular wall can arise as a result of bacterial or viral infection (sepsis), after the use of certain drugs and in the lack of vitamin C (scurvy). These diseases affect in particular capillaries. A typical symptom of vasculopathies is the formation of haematomas of various extent, from dot-like petechiae to extensive ecchymoses. Besides, bleeding from various tissues and organs occurs. Of the congenital vasculopathies, the **hereditary haemorrhagic telangiectasia** (teleangiectasia hereditaria hemorrhagica, Osler-Weber-Rendu disease) with dysplasia of the supportive tissue of the tiny vessels is the most common. Clinically, teleangiectasias of various sizes can be found on the skin and mucosa. In the oral mucosa, they develop in particular on the lips, tongue and soft palate. It bleeds easily after small injuries or even spontaneously.

Th.: Symptomatic – coagulation of the teleangiectasias.

Systemic vasculitis affecting small vessels occur relatively commonly in the children age – an “allergic-toxic” Henoch-Schönlein purpura. It usually develops after a catarrh of the upper respiratory tract, first as a rash, turning later into a haemorrhagic maculopapular exanthema (enantheme). In the oral cavity, it predominantly affects the tongue and oral floor, developing petechiae or haemorrhages. The exclusion of the allergen is crucial, corticoids are used in severe cases.

Vascular anomalies

A group of vascular anomalies includes, according to the currently used classification, vascular malformations and benign vasoformative tissue tumours, which are formed by growths of blood vessel (hemangioma) or lymph vessel (lymphangioma) cell types.

Predilection sites of those growths are in the head and neck region. They can be congenital (can regress spontaneously or, on the contrary, grow) or represent trauma-induced reactive lesions. **Hemangiomas** can occur both on the surface and deep in the body (in the muscles or even bones). If the tongue is affected, they can lead to macroglossia. Cavernous haemangiomas usually appear as a painless, soft bluish growth with negligible palpation resistance. A multiple occurrence in a single patient is called haemangiomatosis. Capillary haemangioma is red and can be a part of congenital syndromes such as Sturge-Weber syndrome – an encephalotrigeminal angiomas that develops due to the persistence of embryonic vessels and affects the skin of the face, oral mucosa, meninges and brain. The manifestations are unilateral in the region of the trigeminal nerve (especially the 1st and 2nd branches). Accompanying symptoms may include congenital glaucoma, ocular angiomas, epileptiform cramps, hemiparesis and oligophrenia.

Lymphangiomas usually appear in the infant age. The lesions often affect the tongue, with the appearance of small blisters (lymphangioma simplex) or multiple whitish and red small cysts (lymphangioma cavernosum). Cystic lymphangioma is usually located in the submaxillary region and on the neck and has a hemispheric or ovoid shape.

Th: Many haemangiomas and lymphangiomas require only observation. If they grow, are subject to repeated injuries or bleeding, they can be removed by sclerotization (aethoxysclerol application), laser, cryodestruction or surgically (extensive angiomas must be first examined using angiography).

6.2.2. Changes in the oral cavity associated with diseases of heart and circulatory system

There are two reasons why the attending dentist must consider cardiac and circulatory diseases. One is that people with such problems (e.g. hypertension, congenital or acquired cardiac defects, chronic cardiac failure, etc.) require special attention and must be prepared before dental treatment (e.g. to prevent bacterial endocarditis in patients with cardiac defects). The other reason is associated with changes manifesting in the oral cavity that can be caused by cardiovascular diseases. Such changes mostly include disorders of the terminal vascular bed, manifesting in the mouth in particular by changes of the lingual mucosal relief. Such changes result from the development of varices and rarely, they can be associated with complications (thrombotization, bleeding). The underside of the tongue is most commonly affected. In the right heart cardiac failure, the tongue can be enlarged and the mucosa can be of purplish-blue colour. In left-sided insufficiency, carmine red discoloration can be observed, usually without any changes in the size of the tongue. Advanced arteriosclerotic changes in the oral mucosa can manifest by mucosal atrophy.

6.2.3. Changes in the oral cavity associated with respiratory diseases

In diseases of the upper respiratory tract (rhinitis, pharyngitis, tonsillitis, tracheitis), bad breath can occur if fever is present. Such diseases are also often associated with the development of acute exacerbation of chronic gingivitis (or with acute gingivitis as such) as a result of the pain and discomfort in the mouth that lead to limited hygiene and plaque development. The mucosa can be dry, lips dry and cracked. In pneumonia, besides aforementioned gingivitis, thickened coating of the tongue can be observed, as well as eruptions of **herpes labialis** (also called herpes febrilis). In bronchiectasis and pulmonary abscess, foetus ex ore is usually present. Secondary ulceration on the oral mucosa is a rare complication of pulmonary TBC.

6.2.4. Changes in the oral cavity associated with diseases of the GIT

Lesions similar to aphthae (aphthoid ulcers) often appear in patients with GIT problems. In deficiency of vitamins and some elements (Fe), the typical deficiency manifestations include smooth tongue and painful corners of the mouth. If esophagus is affected together with the oral cavity, dysphagia can occur. Acute inflammations of the gastric mucosa can be associated with thick whitish moist coating of the tongue. On the other hand, disappearance of the coating and atrophic mucosa can be found in chronic inflammations of the gastric mucosa. In sudden GIT colics (especially if the peritoneum is irritated), the coating of the tongue can be thick with brownish discoloration and the tongue is dry.

In diseases of the liver, atrophic changes of the lingual mucosa can occur, especially atrophy of the filiform papillae. At first, this is particularly apparent on the tip of the tongue; later on, the whole surface can be affected. The tongue is dark red, moist, almost without coating but with slight hyperkeratosis.

Pigmentation of lips and oral mucosa can represent a diagnostically valuable symptom in intestinal polyposis (Peutz-Jeghers syndrome).

Changes on the oral mucosa are also often observed in inflammatory bowel diseases; besides mucosal lesions, in more advanced stages of the disease, manifestations of malabsorption (i.e. of deficiency of some nutrients) are also likely to appear.

Crohn's disease (morbus Crohn)

Crohn's disease is a chronic inflammatory granulomatous disease that can manifest in any part of the GIT but most commonly affects the junction of the small and large intestine (with the inflammation penetrating the entire intestinal wall). Mostly, young individuals are affected. The etiology is not yet fully understood, it is most likely an autoimmune inflammation.

Clinical picture: Changes in the oral mucosa appear in approx. 20 % of patients and may precede the intestinal manifestations; they are however more common in later stages of progression of the disease. The lesions (aphthoid ulcers) are similar to aphthae and appear on the lining mucosa.

Mucosal induration (in particular of labial and buccal mucosa) can be observed, as well as granulomatous gingivitis, angular cheilitis, in some cases even atrophic glossitis.

Th: The diagnosis is to be established and treatment managed by a gastroenterologist. Locally, the use of antiseptics can be recommended to prevent or suppress secondary bacterial infections.

Ulcerative colitis (colitis ulcerosa)

This chronic inflammatory disease mostly affects the colonic mucosa.

Clinical picture: In some patients, aphthoid ulcers can be found in the oral cavity along with small superficial necroses, pustules and vegetations on an erythematous mucosa with belt-like arrangement (pyostomatitis vegetans).

Th: The diagnosis is to be established and treatment managed by a gastroenterologist. Locally, the use of antiseptics can be recommended to prevent or suppress secondary bacterial infections.

Celiac disease (gluten enteropathy)

This immune system-associated systemic disease characterized by reaction to the presence of gluten in the diet and damage to the intestinal mucosa is diagnosed by proving the presence of anti-gluten antibodies. The oral mucosa is affected approximately in 10 % of patients in whom aphthous lesions occur.

6.2.5. Changes in the oral cavity associated with diseases of the kidney

Uremic stomatitis

In the oral cavity, it only manifests at the late stage of the disease by a painful erythema or ulcerations with pseudomembranous coatings. The tongue can be dry, brownish coated, lips are chapped. Xerostomia is present. Gingival bleeding and bleeding into the submucosal tissues is common as it is caused by dysfunction of thrombocytes (either due to the renal disease as such or as a secondary result of repeated dialysis). Candidosis and other opportunistic infections can appear. In the terminal stage of the chronic renal failure, in uremia, **bad breath** is a typical finding.

6.2.6. Changes in the oral cavity associated with metabolic and endocrine disorders

Glycogenoses and mucopolysaccharidoses

These disorders of glycogen synthesis or degradation are caused by a hereditary lack of enzymes, which leads to an increased deposition of glycogen into the tissues. Depending on the type and location of the enzymatic defect, several subtypes of this disease can be distinguished, in one of which, Pompe disease (glycogen storage disease type II, autosomal recessive hereditary disease with a deficiency of lysosomal acid 1,4-glucosidase) glycogen storage into the muscles of the tongue can be observed.

Mucopolysaccharidoses are diseases with congenital disorders of the metabolism of mucopolysaccharides; the lack of some of the lysosomal enzymes involved in glycosaminoglycans cleavage causes their deposition in various tissues, including those of the oral cavity.

Diabetes mellitus

Changes on the oral mucosa in diabetes are variable and usually secondary. They depend on the type of diabetes, its duration, compensation, and the presence of systemic complications. Bright red smooth tongue (atrophic glossitis) is a typical finding in the oral cavity. Diabetes patients are also significantly more susceptible to infectious diseases. Therefore, they suffer more often with inflammatory changes and complications caused by bacteria; similarly, fungal infections are more common (denture stomatitis, stomatitis angularis), many diabetic patients also complain about insufficient saliva production and resulting xerostomia. Burning of the mucosa and taste perception disorders (**stomatodynia, glossodynia**) are also common. A non-inflammatory hypertrophy of the glandular parenchyma of the parotid glands – sialoadenitis in the form of a bilateral induration of parotid glands, Charvat's sign – is also more commonly found in diabetics. A combination of diabetes and hypertension with the affliction of the oral cavity in the form of the oral lichen is called **Grinspan syndrome**. In diabetics (in particular in the non-compensated ones), **gingivitis and periodontitis** are more common than in the general population; they also progress more rapidly than in healthy individuals. Multiple periodontal abscesses can also be present.

Insufficient function of the thyroid gland (hypothyroidism)

In adults, the general symptoms of hypothyroidism include exhaustion, sleepiness, sensitivity to cold, constipation, anaemia, dry pale skin, etc. In the region of the mouth and face, mucoprotein and mucopolysaccharide infiltrations (myxoedema) occur, in particular in the tongue (macroglossia) and eyes (lid oedema). Xerostomia is also often present.

Congenital hypothyroidism (endemic cretinism) is a developmental disorder caused usually by lack of iodine in the mother's diet during pregnancy. Children are born with a severe mental handicap, suffer with delayed growth and other impairments. In the oral cavity, the disease manifests through delayed growth of teeth, enamel dysplasia and **macroglossia**.

Increased function of the thyroid gland (hyperthyroidism)

Principal symptoms include enlargement of the thyroid gland (goitre), palpitations, increased blood pressure, sometimes arrhythmia, and intolerance of heat, trembling at rest, exophthalmos (in Graves-Basedow disease) and moist warm skin. It is usually not associated with any symptoms in the oral cavity (although trembling of the tongue can be present in some cases). When treating a patient with hyperthyroidism, however, the dentist must be careful with administering anaesthetics with adrenalin (risk of thyrotoxic crisis).

Increased function of the parathyroid glands (hyperparathyroidism)

Increased production of parathormone (mostly due to adenoma of the parathyroid glands) leads to hypercalcemia and hypophosphatemia, which determines the systemic symptoms. In the oral cavity, so-called **brown tumour** (giant cell reparative granuloma) can develop, which is a benign tumour of resorptive character. If this tumour is found, the calcium-phosphate metabolism must always be examined.

Primary hypofunction of the adrenal cortex (Addison's disease)

If the adrenal cortex is damaged (infection, autoimmune processes, tumours), the lack of adrenal hormones stimulates the pituitary gland and production of ACTH and MSH increases, leading to the development of **melanin hyperpigmentations** on the skin (bronze skin) and on the oral mucosa (graphite-like spots). See Chapter 6.3.1 for more information.

Acromegaly

Acromegaly occurs if the growth hormone (somatotropin) is produced in large amounts even after the normal growth is terminated. This is mostly caused by an eosinophilic adenoma of the pituitary, more common in women (2nd to 3rd decade of life, can follow gravidity but can also later follow the menopause). Changes in configuration of the acral parts are typical – dysmorphic changes of the face, enlargement of the distal parts. Enlargement of the tongue (**macroglossia**) is often associated with development of the plicated tongue.

6.2.7. Paraneoplastic processes

Paraneoplastic processes (paraneoplasia) are symptoms or diseases accompanying tumorous growth in another location. The reasons for paraneoplastic changes are not always clear, reasons may include substances released by the tumour or other mechanisms. In the oral cavity, paraneoplastic processes include e.g. **acanthosis nigricans** (can indicate a malignant disease of the stomach and colon) or **pemphigoid** that can also signal the development of a malignant tumour in the organism.

6.3. Endogenous pigmentations

Pigmented lesions of the oral mucosa caused by exogenous pigmentations were described in the Chapter 5.2.4. In endogenous pigmentations, the pigment is formed in the organism itself; such pigments include in particular melanin, hemosiderin, ferritin, porphyrin precursors and discolorations of vascular origin (Fig. 10).

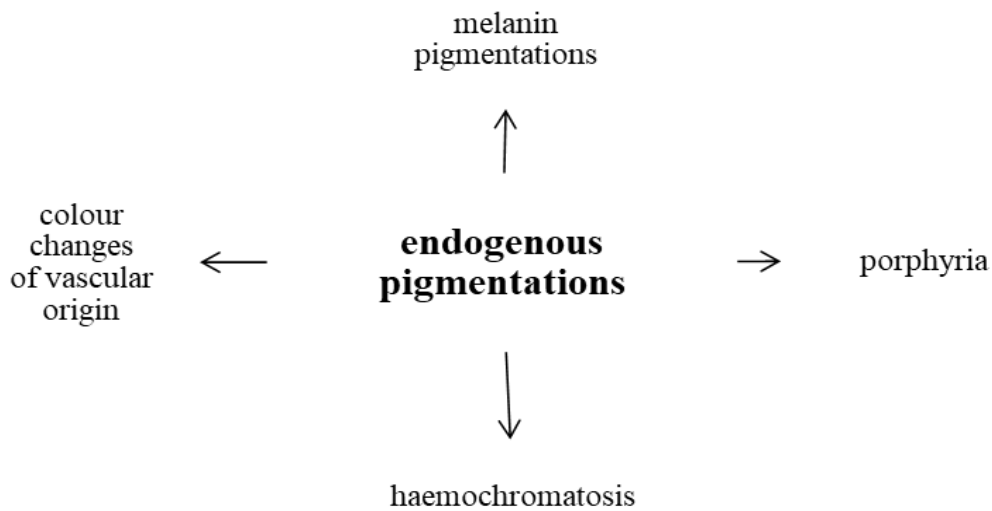


Fig. 10: Etiology of endogenous pigmentations

6.3.1. Melanin pigmentations

Melanocytes of the oral mucosa usually do not produce melanin as their activity is stimulated by the exposure to UV irradiation; other stimulants of their activity include oestrogens (manifestations on the skin and lips such as **chloasma gravidarum** during pregnancy), mechanical or chemical irritation (reactive posttraumatic or postinflammatory hyperpigmentation), smoking (smoker's melanosis) and some drugs. Melanin pigmentations of the oral cavity can be physiological (racial, freckles - ephelides) or pathological that may clinically manifest as solitary, diffuse or multiple. They are most commonly formed as a result of increased melanin production by melanocytes. Other possibilities include local proliferation of melanocytes and nevus cells; malignant proliferation of abnormal melanocytes is the worst scenario (Fig. 11).

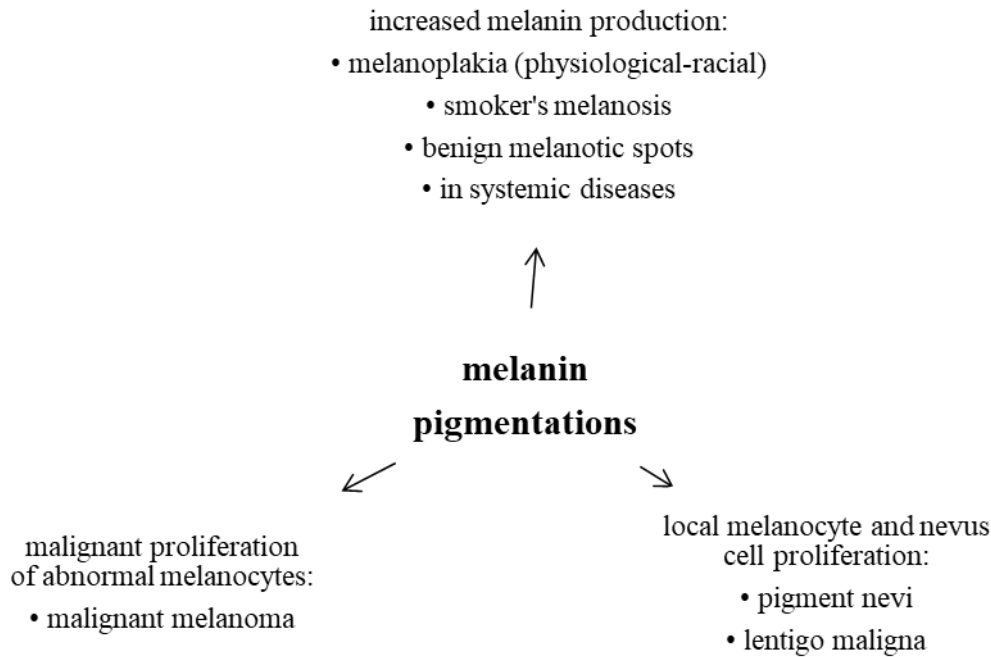


Fig. 11: Classification of melanin pigmentations according to the etiopathogenesis

Melanin pigmentations caused by increased melanin production

Smoker's melanosis

It occurs in some smokers, probably as a defensive reaction of the organism against smoking. Chemical and thermal irritation stimulate the production of melanin that can protect the mucosa by binding the toxic compounds and prevent their penetration into deeper layers. It is especially common on the gingival, buccal and palatal mucosa. After smoking cessation, it can regress spontaneously.

Benign melanotic macules

Oral and labial melanotic macules are caused by hyperproduction of melanin in the basal layer of the mucosa. They are usually solitary but can be multiple, usually well circumscribed, they can develop suddenly and remain stable and stationary. They can be found in adults, most commonly in the vermilion zone, gingiva, buccal and labial mucosa (but they can develop even on genitals).

Oral melanoacanthoma

Oral melanoacanthoma is a reactive hyperpigmentation developing as a result of a mild injury or chronic irritation.

Melanin pigmentations in systemic diseases

Melanin pigmentations appear in Addison's disease, Peutz-Jeghers syndrome, bronchogenic pulmonary carcinoma and other tumours, or in acanthosis nigricans.

Addison's disease

In the primary form of the adrenal hypofunction caused by a damage to the adrenal cortex, the systemic symptoms (hypotension, disorders in electrolyte metabolism) can be accompanied by diffuse hyperpigmentation (so-called "bronze skin" or hyperpigmentations in the genital region and in the areolas) and/or by greyish-black focal pigmentations (so-called graphite stains) on the oral mucosa, especially on the buccal mucosa in the region of the molars and on the sides of the tongue. The increased pigmentation, especially in the areas of increased mechanical irritation, are caused by an increased pituitary production of the adrenocorticotrophic hormone (ACTH) and melanocyte stimulating hormone (MSH) or, rather, of their common precursor, pro-opiomelanocortin. In secondary insufficiency of the adrenals (i.e., if hypothalamus or pituitary gland are affected), such hyperpigmentation does not occur.

Bronchogenic pulmonary carcinoma (and some other malignancies)

Some malignancies can result in melanotic changes on the palate that arise by a mechanism similar to that found in Addison's disease, i.e., as an effect of the formation of a common precursor of ACTH and MSH.

Peutz-Jeghers syndrome (Peutz-Tourain-Jeghers-Klostermann)

This autosomal dominant hereditary disease counting among hereditary tumour syndromes affects both sexes with the same frequency. It is a hamartomatous polyposis of the gastrointestinal tract (most commonly affecting the colon), accompanied with mucocutaneous, in particular oral, hyperpigmentations. Those melanotic (dark brown) spots are well circumscribed and located most commonly near the body openings – in the face, it is in particular on the lids, around the nostrils, circumorally, sometimes on the vermillion, or on the labial, buccal, lingual or palatal mucosa. Polyps in the GIT can cause sudden gastric/abdominal colics or GIT bleeding. An increased tendency to developing carcinomas of the GIT, uterus, ovaries, breasts and testicles are the reason for classifying this syndrome as precancerosis and mucocutaneous paraneoplasia.

Acanthosis nigricans

This papillomatous-verrucous focal, melanin-pigmented disease of the skin or mucosa can occur either in a benign or malignant form.

The benign form can be categorized as follows:

- 1) the genetic type manifesting in childhood or early adulthood that only rarely affects the oral cavity
- 2) acanthosis nigricans as a part of syndromes (Prader-Willi, Bloom) that also manifests in childhood and does not affect the oral cavity
- 3) pseudoacanthosis – often affecting obese persons with darker complexion, manifesting only on the skin.

Malignant acanthosis nigricans has a character of a paraneoplastic process and can occur with tumours of the stomach and colon. For diagnostic purposes, it is necessary to note that it can precede the manifestation of the tumour by up to a year. Lesions on the face are usually symmetrical, lips are often affected as well as the tongue (macroglossia can be present) and the buccal mucosa. Lesions have indistinct edges, mostly flat with rough surface. Similar lesions can occur on other mucosal surfaces (e.g. on the conjunctiva or rectum).

Melanin pigmentations caused by a local proliferation of melanocytes and nevus cells

Pigment nevi

Pigment nevi are not common on the lips and oral mucosa. They can occur in children but their peak is in the 3rd-4th decades of life. They can be of various colours (blue, brown, black; even the amelanotic form is possible). They are usually solitary, well circumscribed, flat or elevated, several millimetres large and do not change over time. A pigment nevus goes through several stages of development: junctional, compound and intramucosal. Unlike melanin pigmentations caused by an elevated production of melanin, pigment nevi arise as a result of melanocyte proliferation and their transformation into nevus cells. Some types of pigment nevi can be potential precursors of the development of the malignant melanoma.

Dg.: Verification by histology

Th.: Surgical

Lentigo maligna (melanosis circumscripta praeblastomatosa Dubreuilh, Hutchinson's melanotic freckle)

This special type of pigmented nevus always transforms into malignant melanoma. It only rarely develops in the area of the lips and oral mucosa. If so, a typical manifestation (usually on the palate or lower alveolus) is a dark, central melanotic spot with smaller satellite lesions that can be sometimes of a different colour, with diffuse edges and quickly changing appearance.

Dg.: Like in the case of the malignant melanoma, can only be verified histologically.

Th.: Surgical.

Melanin pigmentations with malignant proliferation of abnormal melanocytes

Malignant melanoma

Occurrence of the melanoma in the oral cavity is rare (approx. 1 % of all malignant tumours of the oral cavity). It almost always occurs on the palate or the alveolar ridge of the maxilla in patients of higher age, it is more common in males. It develops either by malignant transformation of a pre-existing pigmented lesion or „de novo“. Typical symptoms include a sudden development, rapid growth (weeks to months), invasion into the surrounding tissues, tough consistence and, frequently, ulcerations of the existing melanocytic lesion.

Dg.: Must be made by a pathologist based on morphological characteristic of a bioptic sample.

Th.: Surgical, the excision must have a sufficiently wide resection margin.

6.3.2. Haemochromatosis

This rare autosomal recessive disease is characterised by excessive absorption and pathological deposition of Fe in the organism. It affects in particular middle-aged males. The clinical picture includes cutaneous and oral mucosal hyperpigmentations with dark bronze-reddish-brownish hue resulting from deposition of the haemosiderin and haemofuscin pigments. Hepatomegaly is often present, as well as hepatic cirrhosis (leading to development of a hepatoma in about 25 % of patients) and diabetes mellitus (so-called „bronze diabetes“).

6.3.3. Porphyrrias

This term refers to a group of disorders associated with porphyrin metabolism, namely with excessive production of porphyrins and their precursors (haemoglobin, biliverdin, bilirubin). Each type of the disease is characterized by a defect of a specific enzyme involved in the haem synthesis. According to the tissue where the abnormal synthesis of porphyrins takes place, porphyrias can be classified into 3 categories (with many subcategories): erythropoietic, hepatic and mixed. Typically, the skin is very photosensitive and abnormally fragile with erythema, vesicles or even bullae, erosions, hyperpigmentation and hypertrichosis. The oral mucosa is affected less often; cinnabar-coloured lesions can form on the lips, corners of the mouth, vestibular and gingival mucosa.

6.3.4. Discolorations of vascular origins

Such discolorations are caused by small dot-like (petechiae, purpura) or larger (ecchymoses, haematomas) bleeding into the tissues caused by injury (e.g. biting), bleeding disorders or due to multiplication/dilation of vessels/capillaries (teleangiectasia, sublingual venectasia, haemangioma). Rarely, such discolorations can be also caused by malignant vascular proliferation (angiosarcoma-Kaposi's sarcoma). Unlike the melanin-associated pigmentation, pigmentations of vascular origin are of red-blue-Bordeaux colour.

7. Potentially malignant lesions of the oral mucosa

Potentially malignant lesions of the oral mucosa (precancerous lesions, premalignant lesions, oral potentially malignant disorders – OPMD) are clinical manifestations bearing risk of turning into malignant proliferation in the oral cavity. The current WHO classification from 2017 classifies all types of such lesions into a single group (Table 1) and thus disregards the former attempts to classify the diseases according to their susceptibility towards malignant transformation or relationship to systemic diseases (Slootweg et al., 2017). A separate class was created for proliferative verrucous leukoplakia, which is a particularly aggressive type of OPMD and has an especially high potential to malignant transformation and capability to recur.

Leukoplakia
Erythroplakia
Erythroleukoplakia
Oral submucous fibrosis
Dyskeratosis congenita
Chronic hyperplastic candidosis
Oral lichen planus – atrophic and erosive forms
Discoid lupus erythematosus - atrophic and erosive form
Epidermolysis bullosa
Syphilitic glossitis
Actinic cheilitis
Sideropenic dysphagia (Patterson-Kelly, Plummer-Vinson syndromes)

Tab. 1: Potentially malignant diseases of the oral mucosa

Epidemiology

The prevalence of oral leukoplakia in the western countries ranges from 1 % do 4 %; in some parts of Southeast Asia, even higher prevalence is reported (Napier a Speight, 2008). Oral erythroplakia is, on the other hand, a rare lesion with prevalence between 0.02 % and 0.83 % (Reichart, 2005). Males are affected more often than females.

Etiology

OPMDs arise due to various etiologies. The tobacco abuse (smoking and/or chewing) and alcohol consumption are among the most prominent factors associated with the development of leukoplakia (Napier a Speight, 2008). For most OPMDs, however, etiological factors are unknown.

The influence of human papillomavirus (HPV) infection on the development of OPMDs is discussed in the Chapter 5.3.6.

Site

OPMDs can occur anywhere on the oral mucosa. The site of the lesions usually depends on the particular etiological factor (Napier a Speight, 2008). Erythroplakia is more common on the soft palate, oral floor and buccal mucosa (Reichart a Philipsen, 2005).

Clinical symptoms

Most high-risk OPMDs are represented by white, red or spotted oral lesions. They can be homogenously white or mostly white with a nodular, verrucous or erythematous area.

Genetic predisposition

OPMDs occur in rare syndromes such as Fanconi anaemia (Cavalcanti et al., 2015) or dyskeratosis congenita (Handley et al., 2006); nevertheless, most cases develop without any known genetic predisposition.

Prognosis and prediction factors

Although the presence of dysplasia in the lesion correlates with the probability of development of the squamous cell (spinocellular, squamocellular) carcinoma, most OEDs never turn malignant. A general rule is that a higher degree of dysplasia correlates with a higher probability of developing carcinoma (Mehanna et al., 2009, Silverman et al., 1984).

Oral epithelial dysplasia (OED)

The term OPMD describes all pathological processes that do not represent carcinoma on themselves but under certain circumstances, they can turn malignant. Such lesions can show a wide range of changes in the cytology and architecture of the epithelium and be associated with an increased risk of malignant transformation. Those changes are termed oral epithelial dysplasia (OED). Dysplastic changes are found in most erythroplakias and erythroleukoplakias while in leukoplakia, the rate of dysplasia is significantly smaller. Histological changes associated with histological criteria of epithelial dysplasia are summarized in the Table 2.

Changes in the tissue architecture	Cytological changes
Irregular epithelial stratification, loss of normal epithelial maturation	Nuclear and cellular pleomorphism (anisocaryosis, anisocytosis)
Loss of basal cell polarity Teardrop-shaped rete ridges Higher frequency of mitosis	Increased nuclei with irregular contours
Mitosis outside the basal epithelial layer, i.e, in the upper layers of the epithelium	Increase of the N/C ratio
Dyskeratosis – premature keratinization in individual cells Keratin pearls in the rete ridges	Atypical mitoses Increased number and size of the nucleoli
Loss of cohesion of the epithelial cells	Hyperchromasia of the nuclei, coarser chromatin structure

Table 2: Diagnostic criteria for epithelial dysplasia. The N/C rate (nuclear:cytoplasmic ratio, the ratio of the volume of the nucleus and the cytoplasm) relates to the cell maturity.

OED is classified according to the severity into three tiers, taking into account the number of the “thirds” of the affected epithelium. In mild dysplasia, the atypical cells are limited to the basal membrane, moderate dysplasia affects also the medium third and severe dysplasia also the uppermost third of the epithelium (Slootweg et al., 2017), see Table 3. Recently, a binary two-tier grading system, distinguishing only between low-grade and high-grade dysplasia, is becoming preferred.

WHO classification 2017	Binary classification
Mild dysplasia	Low-grade dysplasia
Moderate dysplasia	
Severe dysplasia	High-grade dysplasia

Table 3: Classification systems for the oral epithelial dysplasia

Mucosal lesions of the character of carcinoma *in situ* of the oral mucosa (i.e., intraepithelial carcinoma) that is limited to the epithelium only and does not extend beyond the basal membrane) is at present classified as severe dysplasia (Slootweg et al., 2017).

7.1. Leukoplakia

The clinical descriptive term leukoplakia can, according to the macroscopic picture, encompass various clinical conditions, the common feature of which is a “white area“ (leukos = white). Several definitions of the term leukoplakia have been proposed, corresponding to the state of knowledge at the time of creating the definition. The World Health Organization (WHO) originally defined leukoplakia as a white area that cannot be characterized clinically or histopathologically as another disease. The next step was the exclusion of keratoses (frictional keratosis and smoker’s leukokeratosis) that generally count among benign lesions and have a tendency to regress after removal of the source of local irritation. The clinical differentiation of such lesions is however difficult and can only be reliably established based on histopathological examination. One of the most recent leukoplakia definition proposals reads: leukoplakia is a predominantly white lesion of the oral mucosa that cannot be histologically or histopathologically classified as another lesion and that is associated with the increased risk of the development of carcinoma in the region of the lesion, elsewhere in the oral cavity or in the region of the head and neck (Isaac van der Waal, 2015).

A definite diagnosis of oral leukoplakia can be only established after an evaluation of the macroscopic finding, considering possible etiological factors, and, in particular, histological examination. Leukoplakia in a more general sense relates to increased keratinization of the mucosa that are under normal circumstances covered by a non-keratinizing squamous epithelium. White spots can develop anywhere on the mucosa with predilection towards buccal mucosa. Generally, several types of leukoplakia can be distinguished: **homogenous** – lesions are white, with a smooth or furrowed surface, and **non-homogenous** – with verrucous, nodular, ulcerative character or characteristics of erythroplakia/erythroleukoplakia.

Various possible etiologies of leukoplakia are known, the etiological factors in particular include various irritant factors inducing a chronic inflammation and potentially participating in the development of carcinoma that the leukoplakia can turn into. Such factors include mechanical effects (cariou teeth, unsuitable prosthetic devices, traumatising the buccal mucosa by biting, etc.), chemical, eletrogalvanic and actinic factors. Those include in particular tobacco abuse – effects of smoking. Males between 40 and 60 years of age are the most affected group. The malignant transformation of leukoplakia occurs in 3-6 % of cases. For initiation of the tumour growth, a serious accumulation of factors is needed, such as a combination of local irritation, systemic factors, and the susceptibility of the organism. Non-homogenous leukoplakias are more associated with malignant transformation than homogenous ones, in particular verrucous and erosive leukoplakias (up to 30 % of erosive form turns malignant).

Histology: Keratosis, hyperkeratosis and/or acanthosis are often found. In some leukoplakias, dysplastic changes are present, see Table 2.

Th.: Any leukoplakia needs histopathological verification. The ways of treatment differ according to the clinical and histopathological picture. In simple hyperkeratosis (frictional keratosis,

smoker's leukokeratosis), simple removal of the irritant factors and smoking cessation are often sufficient and the lesion regresses spontaneously over time. It is however still necessary to perform regular (half-year) follow-ups of the leukoplakia lesions and if the lesion persists, to perform biopsy. A radical surgery is indicated in non-homogeneous forms with a high risk of malignant transformation, in particular where epithelial dysplasia is present in the tissue removed during (incisional or excisional) biopsy.

Dif. dg.: Oral leukoplakia must be distinguished from so-called „hairy leukoplakia“, which is a manifestation of EBV, affects in particular HIV-positive patients and occurs in particular on the sides of the tongue.

7.1.1. Proliferative verrucous leukoplakia

This exophytic proliferative leukoplakia with papillomatous or cauliflower-like appearance affects in particular the buccal mucosa, palate and lingual mucosa. Histopathologically, a hyperkeratosis without or only with minimum representation of dysplasia is observed. The definitive diagnosis is established based on both the clinical appearance and histopathological examination. It has a marked tendency to recur (up to 70 %) and to transformation into verrucous carcinoma (Slootweg et al., 2017).

7.2. Erythroplakia (erythroplasia)

The appearance of erythroplakia is that of a fiery red area on the oral mucosa. Usually, it is well circumscribed with satin appearance and without indurations. In histological examination, high grade dysplasia is often present, indicating a high risk of possible tumour development.

Th.: Radical surgical therapy.

Dif. dg.: Differential diagnosis from chronic erythematous candidosis is sometimes difficult. In candidosis, the erythematous area of the mucosa (usually on the palatal or lingual dorsal mucosa) is on the same level as the surrounding mucosa. Erythroplakia however usually does not occur at those sites. Atrophic OLP is also difficult to differentiate from erythroplakia – up to 1 % of OLP cases are associated with simultaneous erythroplakia (it is necessary to perform biopsy!).

7.3. Erythroleukoplakia

White lesions with red patches are called erythroleukoplakia (also erosive or speckled leukoplakia). Histological examination often reveals the presence of dysplasia. The risk of its development is increased by alcohol and tobacco abuse (both smoking and chewing).

Th.: Radical surgical therapy

7.4. Oral submucosal fibrosis

This disease occurs in South Asia but can also develop in Asians living in Europe. It is caused by chewing tobacco and areca nuts (often in combination with betel leaves). The alkaloids contained in these materials stimulate the production of collagen fibres that are relatively resistant to collagenase action. The generalized fibrosis of soft tissues can cause trismus, lip rigidity and limited mobility of the tongue. Reports indicate that 7-13 % of the oral submucosal fibrosis turns malignant. Treatment relies on cessation of betel and areca nuts chewing, rehabilitation of mouth opening and application of corticoids into the affected area. Tissue changes are however irreversible.

7.5. Dyskeratosis congenita

This rare congenital disease is characterised by a triad of symptoms: pigmentations on the skin, nail dystrophy, and leukoplakia lesions in the oral cavity. In extensive lesions where the surgical treatment is contraindicated, corticoids can be locally administered.

7.6. Chronic hyperplastic candidosis

This relatively rare form of oral candidosis occurs in particular in immunodeficient patients, especially in middle-aged or elderly. Most patients are smokers. Chronic lesions of this disease gradually change from translucent, palpable white areas into large, lustreless, dense plaques. The homogenous form is characterized by the presence of continuous white plaque while the nodular form forms multiple white “knots” under which erythematous lesions develop; the “knots” can however be neither brushed away nor torn down. The buccal mucosa, palate and tongue are most commonly affected. This candidosis represents an invasive form, with hyphae invading deep into the mucosa. Its appearance is similar to that of leukoplakia, it can progress and undergo malignant transformation. (Fidel et al., 2005).

7.7. Oral lichen planus – atrophic and erosive forms

See Chapter 6.1.3. Malignant transformation in these forms are observed approximately in 3 % of patients.

7.8. Discoid lupus erythematosus (DLE) – atrophic and erosive forms

See Chapter 6.1.2. Development of carcinoma has been reported in the atrophic epithelium (especially of the lower lip).

7.9. Epidermolysis bullosa

See Chapter 6.1.2. It is a well-known fact that individuals suffering with some forms of this rare blister-forming diseases bear higher risk of development of spinocellular carcinoma.

7.10. Syphilitic glossitis

See Chapter 5.4.3.

7.11. Actinic cheilitis (cheilitis actinica, solaris, abrasiva)

See Chapter 5.1.4.

7.12. Sideropenic dysphagia (Patterson-Kelly, Plummer-Vinson syndrome)

It affects in particular middle-aged women with lack of Fe in the blood serum (See Chapter 6.2.1). The entire oral mucosa is glossy, red and atrophic. Development of leukoplakias is quite common and may lay a base for malignant transformation (in particular in the rear part of the oral cavity and in the orolarynx).

8. Notes on differential diagnosis of oral mucosal lesions

In this chapter, the individual diseases are sorted according to their appearance in a way facilitating their differential diagnosis. The subchapters focus on the change of colour and surface of the oral cavity in the following manner: pigmented lesions, white/red lesions, erosions/blisters/bullae and ulcers. The character of those lesions is varied, with individual diseases differing in their etiology, pathophysiology and seriousness. The benefit of this sorting lies however in facilitating the differential diagnosis and the decision making – among other things because some lesions are very close to each other in appearance and cannot be reliably distinguished without a detailed examination.

In the areas of the lips and the tongue, we can also encounter similar manifestations of diseases with completely different etiopathogenesis; for this reason, the following sub-chapters include differential diagnostic remarks and schematic diagrams/overviews.

8.1 Pigmented lesions

Pigmentations are less common on the oral mucosa than on the skin and usually found only incidentally. They are usually not associated with any subjective complaints, they can however represent an aesthetic problem if present in a visible area. Usually, they are represented by accumulation of a coloured substance in the epithelium or the tissue; some changes of vascular origin can however also have the appearance of pigmentations. The pigmented lesions can be of various colour and appearance and can differ in their severity, seriousness, prognosis and therapeutic approach. In establishing diagnosis, it is necessary to distinguish between physiological pigmentations (see Chapter 3.4) from the pathological ones (Chapters 5.2.4. and 6.3.). On the one hand, these can represent completely benign conditions (physiological racial pigmentations, metallic pigmentations, smoker's melanosis) but on the other, they can indicate serious diseases (lentigo maligna, malignant melanoma) or oral manifestations of some systemic diseases (Peutz-Jeghers syndrome, Addison's disease).

8.2. White lesions of the oral mucosa

This term encompasses a group of diseases, the most characteristic clinical symptom of which are white areas on the oral mucosa. The origin of these lesions varies – it can be caused by colonies of microorganisms (most commonly yeasts), by thickened epithelium with excessive keratinization or by a congenital disease.

The character of these lesions also varies. Using a single term to describe so many individual diseases differing both in etiology and pathophysiology can be however justified by the need to describe the differences among them necessary for diagnostic purposes and by the facts that their clinical appearance is almost identical and that they are very difficult to distinguish without a detailed

examination. This group of diseases with white lesions includes in particular keratoses, stomatitis caused by cheek biting, leukoplakia, oral candidosis, oral lichen planus and mucosal changes of the lichenoid type. Less common diseases belonging into this group include white sponge nevus (nevus spongiosus albus), lupus erythematosus and psoriasis (Fig. 12).

A **skin graft** can also appear as a whitish-yellow discoloration of the mucosa in the lower alveolar region (it used to be transplanted at the lower alveolar process to improve conditions for retention of removable dentures).

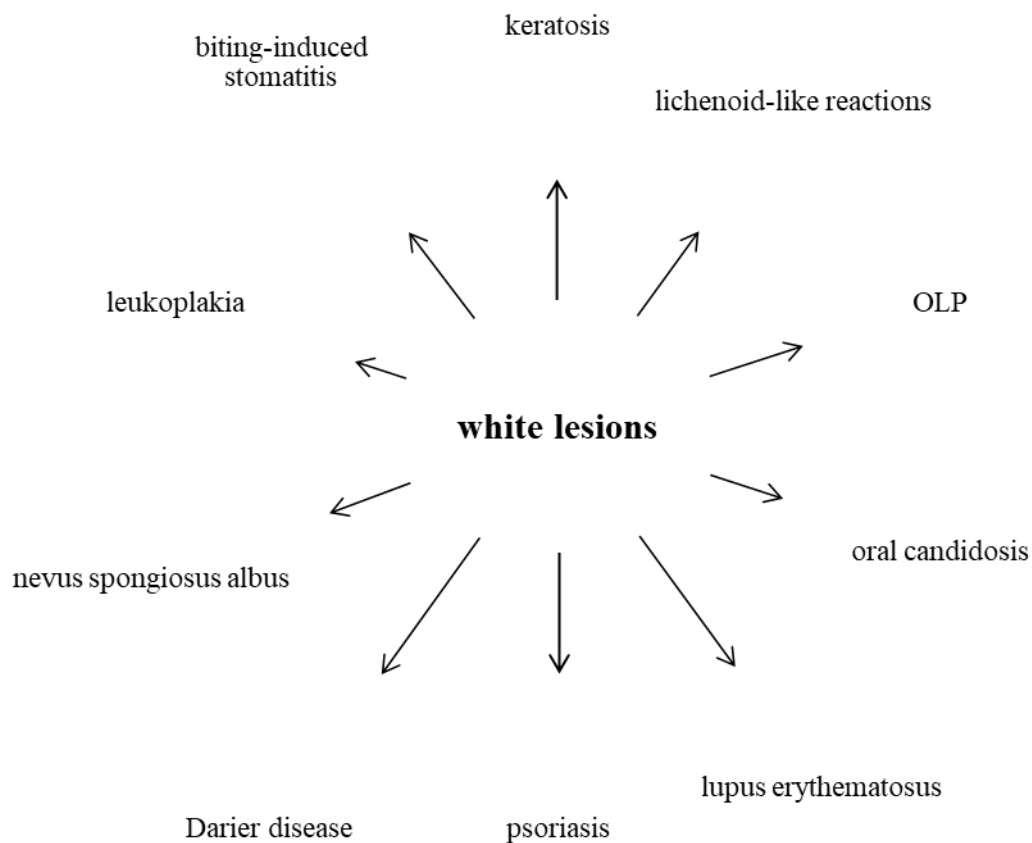


Fig. 12: Dif. dg. of diseases with oral white lesions as a prominent clinical symptom (Škach et al., 1975)

8.3. Red lesions of the oral mucosa

The basic form of the above mentioned diseases, i.e., of leukoplakia, oral lichen planus and oral candidosis, are white lesions (homogenous leukoplakia, reticular lichen planus, pseudomembranous candidosis). They can however manifest also as a red lesion (erythroplakia, erosive lichen planus, erythematous candidosis). Similar to the white lesions, diseases with red lesions are many and can differ both etiologically and pathophysiologically (Fig. 13).

The red lesions can represent:

- a) **atrophy** – epithelial thinning. An example of this is atrophic glossitis, atrophic cheilitis, atrophic oral lichen planus, atrophic form of the lupus erythematosus.
- b) **erosions** – the surface layer of the epithelium is disrupted by an injury, rupture of a vesicle, or immune process-induced apoptosis of keratinocytes.
- c) **inflammatory changes** – these are characterized by an erythema caused by multiplication of capillaries in the submucosa. Examples may include drug-induced stomatitis, contact allergic reactions, erythematous candidosises.
- d) **submucous haemorrhage** – manifests as petechiae, purpura, ecchymoses or a hematomas. They occur as a consequence of ordinary cheek biting or as a manifestation of haemorrhagic diathesis (thrombocytopenia/thrombocytopathy, vasculopathy, coagulopathy).

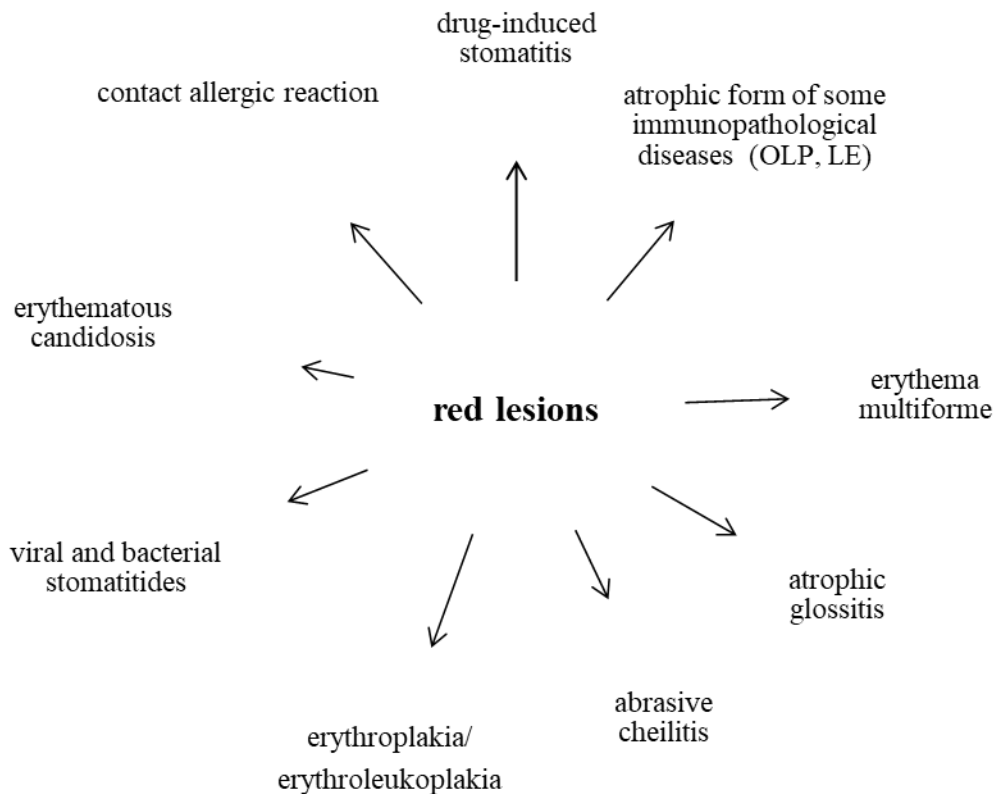


Fig. 13: Dif. dg. of diseases with red lesions as a prominent clinical symptom

8.4. Erosions and blisters on the oral mucosa

In these diseases, one must realize that a vesicle or a bulla on the oral mucosa is very susceptible to rupture and that the primary structure is therefore only rarely observed. During examination, we therefore usually either find erosions that can be tiny at the beginning and begin to combine and merge at a later stage (herpes and enterovirus infections) or extensive erosions covered by fibrin pseudomembranes (note: these do not represent a white lesion!) that are

often formed due to a rupture of a bulla or epithelial necrosis (toxic-allergic reactions, drug-induced stomatitis, erythema multiforme, the bullous form of the oral lichen planus, pemphigus, pemphigoid). Erosions can however represent the primary structure formed by the disease (traumatic erosions). In particular, a timely identification of autoimmune blistering diseases is of utmost importance as early initiation of therapy significantly improves patients' prognosis.

Diseases with erosions dominating the clinical picture can be in general categorized into several groups:

- 1) viral diseases – mostly caused by viruses of the herpes group
- 2) recurrent aphthous ulcers
- 3) toxic-allergic exanthemas
- 4) so-called blistering diseases – pemphigus, pemphigoid, Duhring's disease (dermatitis herpetiformis Duhring), epidermolysis bullosa

In differential diagnosis, the clinician has to consider the clinical findings and structures associated with the findings – vesicles, erosions or bullae (Fig. 14-16). The algorithm for differential diagnosis of blistering diseases is shown in Fig. 17.

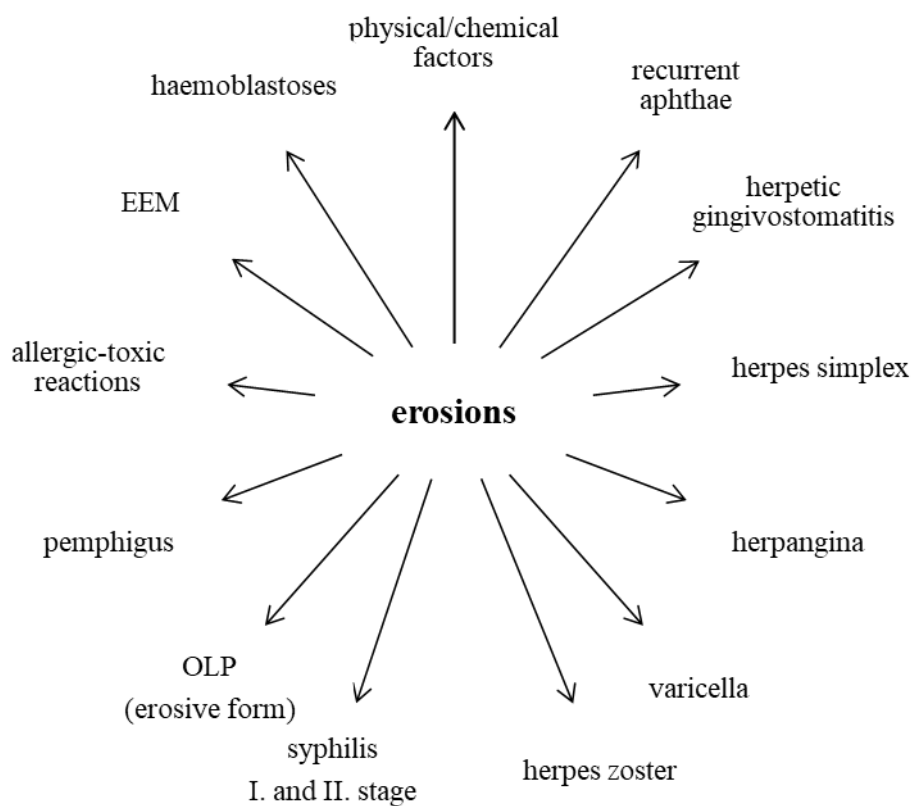


Fig. 14: Differential diagnosis of erosions (amended from Škach et al., 1975)

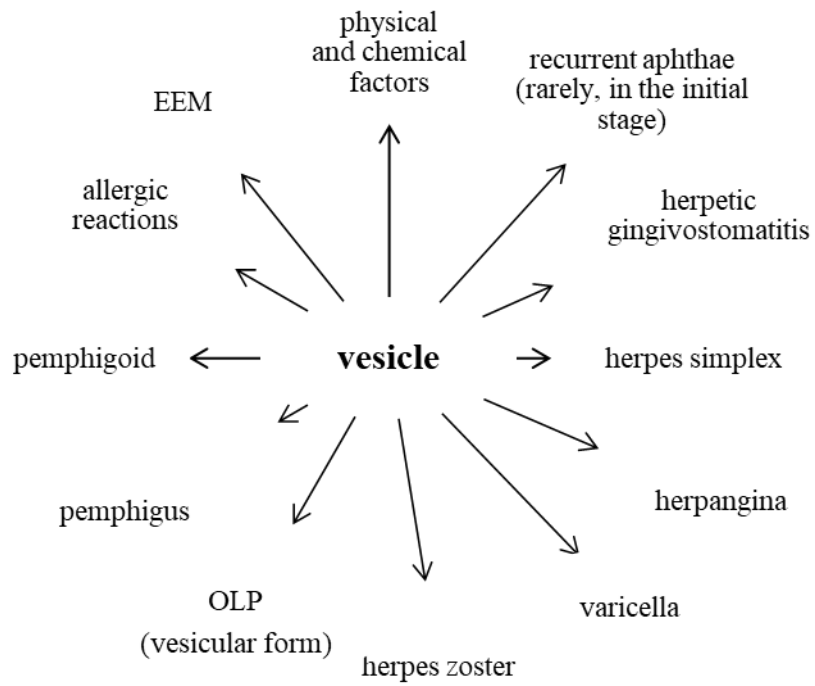


Fig. 15: Dif. dg. of vesicular diseases (Škach et al., 1975)

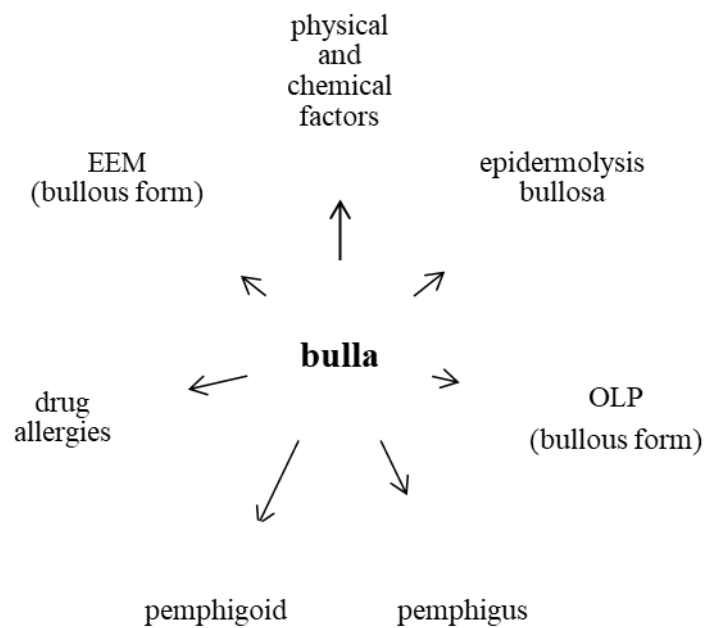


Fig. 16: Dif. dg. of diseases with a bulla as a principal structure (Škach et al., 1975)

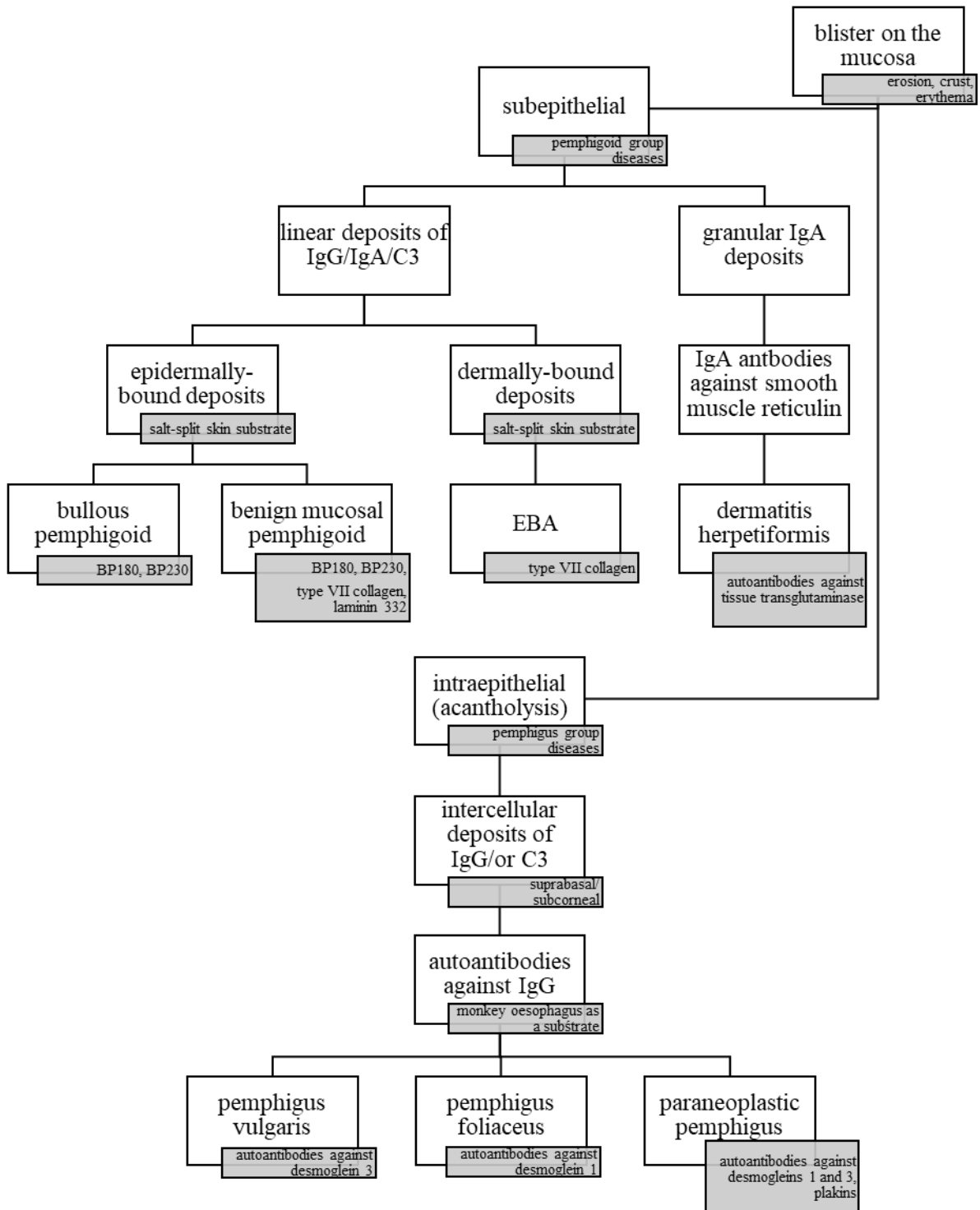


Fig. 17: Dif. dg. of diseases with blisters as the principal structure (amended from Otten et al., 2014). The clinical finding must be augmented by a histopathological examination and subsequent direct and indirect immunofluorescence. Molecular-biological techniques such as ELISA, immunoblotting, immunoprecipitation, etc. often play a key role in the differential diagnosis.

8.5. Ulcerations of the oral mucosa

Ulcers in the oral cavity can develop either as primary ulcers (traumatic ulcer, syphilitic ulcer, ulcers from burns/corrosion), or due to rupture of a blister (herpes zoster facialis) or bulla (pemphigus). The ulcers can vary in depth, deeper ones heal by scar. The difference between an erosion and an ulcer lies in the depth of the defect, clinical differentiation is however often impossible.

The following ulcerations are considered serious: carcinomas and other exulcerated tumours, haemoblastoses and agranulocytoses, deep invasive mycoses, syphilitic and tubercular ulcers.

Diseases that are dominated by ulcers as the main symptom in the clinical picture can be in principle classified (Fig. 18) into three main categories that will be discussed in the following subchapters.

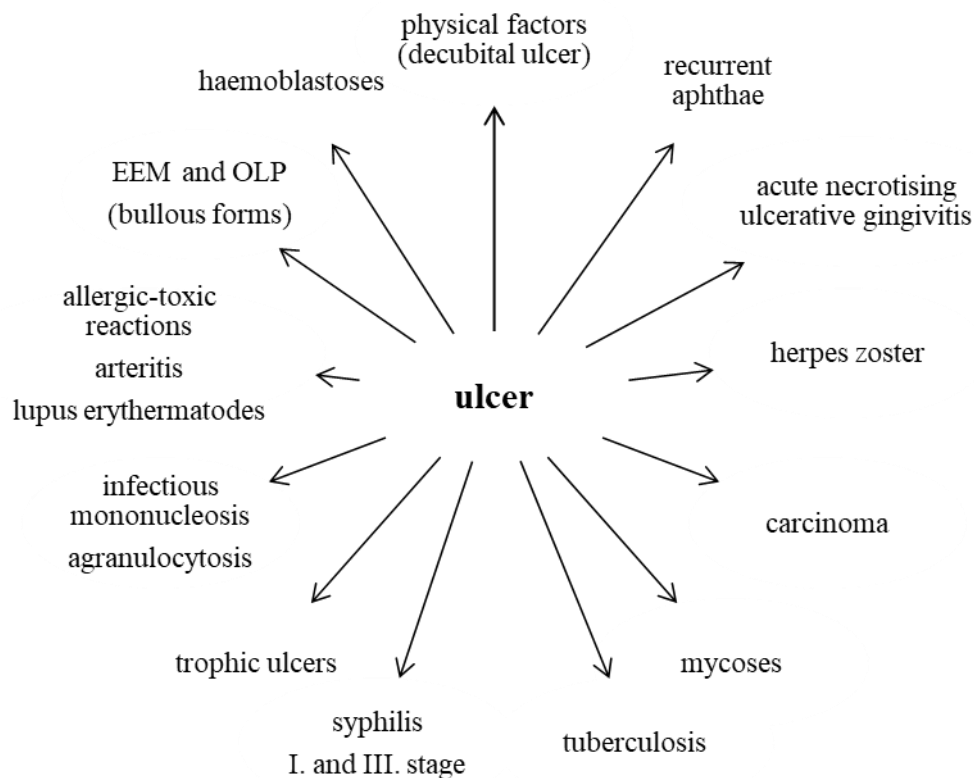


Fig. 18: Differential diagnosis of ulcerations (Škach et al., 1975)

8.5.1. Ulcers affecting primarily the gingiva

The first group encompasses diseases with predilection to gingiva while remaining parts of the oral mucosa are only rarely affected. This group includes in particular necrotizing ulcerative gingivitis and mucosal changes in agranulocytosis and leukaemia.

8.5.2. Ulcers primarily affecting other sites than gingiva

The second group is on the other hand characterized by the fact that the ulcers primarily affect other parts of the oral cavity (any but the gingiva).

Traumatic ulcer is usually an acute, painful solitary lesion that heals well (after removing the etiological factor and a suitable local therapy).

Recurrent major aphthae are painful round or ovoid erosions or ulcers, one to two cm in diameter. They can occur as solitary lesions or in a group of two to three lesions. Healing lasts several weeks. It is always necessary to enquire about the presence of minor aphthae in the past.

Autoaggressive diseases from the pemphigus and pemphigoid groups manifest typically rather by extensive erosions covered with fibrin pseudomembranes than by typical ulcers. They last longer and sometimes can occur together with cutaneous manifestations or precede them. If pemphigus or pemphigoid are suspected, biopsy and laboratory examination (including direct and indirect immunofluorescence!) are necessary.

Ulcers developing due to burns/corrosive substances can be easily diagnosed based on questions while taking the patient's history. According to the exact cause of the defect (temperature or concentration of the corrosive substance and duration of exposure), either acute painful erosions or ulcers can develop. If corrosive substances are involved, it is always necessary to verify whether the patient swallowed the substance because of the risk of burns deeper in the GIT.

Acute haemoblastoses and bone marrow failure are accompanied with a major change of the patient's general condition (exhaustion!) and systemic lymphadenopathy. The duration of the mucosal lesions is usually short (several days); haemorrhagic manifestations, gingival hyperplasia and painful mucosal ulcerations are observed. Suspected presence of these diseases requires immediate haematological examination.

Ulcers in systemic mycoses affect in particular the hard palate and the alveolar process of the upper jaw in immunodeficient persons. The disease progresses very rapidly.

Carcinoma of the oral mucosa – painless ulcer-like lesions may manifest months before the diagnosis. Pain usually only comes once nervous structures are affected. The ulceration usually shows palpable resistance, the ulcer is often irregular with rolled edges. In some patients, regional lymph nodes can be enlarged. If carcinoma is suspected, a histopathological examination is necessary.

Syphilitic chancre (1st stage) is a painless ulcer with elevated edges and hard floor surrounded by a notable collateral oedema – so-called initial sclerosis.

Tubercular ulcer in active lung tuberculosis is a solitary, deep and painful ulcer with rolled edges (tuberculoma) accompanied by enlargement of regional lymph nodes.

8.5.3. Ulcers in specific inflammations

The third group consists of ulcers arising during specific inflammations – in our region, it is in particular tuberculosis and syphilis. From the perspective of dentistry, such specific inflammations count among the diseases endangering the personnel and representing risk of professionally acquired infection. The knowledge of the disease and adherence to the hygienic principles are crucial as is the knowledge in the field of diagnosis and occurrence of the oral form of such diseases.

8.6. Lip inflammation (cheilitis)

If evaluating the inflammatory changes of the lips, it is necessary to consider the specifics of lips when compared to the other parts of the oral mucosa. The disease can affect the skin of the lip, the vermilion zone and/or the mucosal part. Sometimes, all three parts of the lips can be affected, sometimes only one of them; lesions on each of them however have their specifics. The fact that individual infection agents can have predilection for a certain part of the lips must be taken into account. For example, impetigo can be only found on the cutaneous part as well as folliculitis or furuncles (for which the presence of the skin adnexa are a necessary prerequisite) while recurrent aphthae can only affect the mucosal part of the lips.

8.6.1. Overview of the cheilitides

<i>Causes:</i>	<i>Objective findings:</i>
• Physical	
– mechanical:	erythema, excoriation – cheilitis simplex, cheilitis exfoliativa, fissures, erosions, ulcers, crusts
– thermal:	erythema, vesicles, eschar
– radiation:	– phototoxicity: cheilitis actinica (solaris, abrasiva) – photoallergy: cheilitis venenata – radioactivity: erythema, ulcer
• Chemical	
– burns (acids, bases):	eschar (bases – grey; acids – depends on the acid; e.g. after nitric acid – yellowish; after sulphuric acid – dark to black; after hydrochloric acid – white)
– pigments:	cheilitis exfoliativa (desquamation of the upper epithelial layers)
• Infections	
– viral:	herpes labialis
– bacterial:	ulcer, gangrene
– cocci:	furuncles, phlegmon, impetigo, erysipelas, painful corners of the mouth
– TBC:	swollen lips, ulcer
– syphilis:	primary – erosion, ulcer secondary - erosion, plaques muqueuses + opalines, condylomata lata tertiary – gumma (rare)
– fungal:	painful corners of the mouth (with other factors) angular candidosis
• Allergies	
– plant antigens, animal antigens, food proteins, chemicals:	eczema, Quincke's oedema
• Other diseases:	
	EEM – blisters, erosions, crusts pemphigus – blisters, erosions, crusts OLP, LE – erosions, crusts, lichenoid changes cheilitis granulomatosa in Melkersson-Rosenthal syndrome – lip oedemas
– in salivary gland heterotropia:	cheilitis glandularis simplex (cheilitis of Puente) cheilitis glandularis aposthematosa (of Volkmann) cheilitis glandularis suppurativa (Baelz)

8.6.2. Painful corners of the mouth (stomatitis angularis)

Painful lesions of the corners of the mouth can be caused by various factors. The predisposing conditions differ with age. Often, such lesions are caused by a mixed fungal-bacterial infection. The infection usually develops in macroscopically undetectable cutaneous and mucosal defects in the areas that are susceptible to infection by these conditionally pathogenic organisms (*anguli infectiosi*). Other causes may include lack of some vitamins (vitamins B₂, B₆, B₁₂, folic acid) and/or minerals (Fe).

The region of the corners of the mouth is predisposed towards salivary maceration, licking and drying, which results from its anatomical structure. The corner of the mouth can be divided into three zones:

- a) **cutaneous zone** (skin, outer) covered by normal skin including all adnexa.
- b) **transition zone** (vermilion) covered by a squamous cell epithelium of the vermilion with smaller degree of keratinization. Of the skin adnexa, sweat and sebaceous glands are missing as well as the apocrine and hair follicles.
- c) **mucosal zone** (inner) covered by non-keratinizing epithelium of the oral mucosa with orifices of tiny salivary glands.

Clinical picture: If the course disease is atypical, the corners of the mouth (cutaneous or transition zones) contain markedly erythematous painful patches with a central fissure. Sometimes, a whitish border can be found in the neighbourhood of such patches. The lesion is usually bilateral and its course depends on many factors. In children, painful corners of the mouth can occur in rare congenital cutaneous fistulas that can be susceptible to secondary infection. There are many other predisposing factors in children – various (bad) habits such as biting the oral mucosa and/or lips, licking the vermilion zone, putting various objects in the mouth and chewing them, etc. Microtraumatic lesions of the corners of the mouth get easily infected, which can lead to secondary infection, most commonly streptococcal impetiginization) and thus to the further trauma of the tissue.

In adults, the painful corners of the mouth also occur relatively commonly as the number of local and systemic predisposing factors grows. The skin partially loses its elasticity, submucous connective and adipose tissue, the bite height is reduced due to abrasion of the hard dental tissue or loss of supporting zones. The most important systemic factors include diabetes mellitus, Sjögren syndrome, malignant tumours and many other diseases.

8.6.3. Melkersson-Rosenthal syndrome

Etiopathogenesis remains unknown; aside of congenital predisposition, other etiologies are considered such as functional disorder of the autonomous nervous system, inflammatory or allergic reactions to various microbial agents, or an immunity-mediated reaction to various components of the diet. The histopathological findings include a granulomatous inflammation, lymphostasis

and accumulation of the lymphocytes in the tissue. Younger individuals (regardless of their sex) are more susceptible to this disease. A typical triad of symptoms is detailed below; some of them can however be missing in a particular patient at the same time:

- a) ***granulomatous cheilitis*** – recurrent lip oedemas occur in 80 % of patients. An asymmetrical oedema of one or both lips turns into macrocheilia over the course of several days as a result of the granulomatous inflammation. Sometimes, it can spread into the surrounding tissues – cheeks, eyelids, face including the forehead, ears and neck. In the oral cavity, it can affect the buccal mucosa, tongue, the mucosa of the hard palate, sometimes hypertrophic gingivitis.
- b) ***paresis of the facial nerve*** – usually peripheral, a central paresis with a unilateral tinnitus, vertigo and migraine-like headache can be however also present.
- c) ***lingua plicata (potentially accompanied by macroglossia)***

Rarely, organ symptoms can manifest, such as dysphagia, aphonia, attacks of asthma, megacolon, etc. Complete *ad integrum* recovery is rare.

Th.: Causal, corticoid depot injection can be applied, in some cases surgical therapy.

8.7. Macroglossia and microglossia

We speak about macroglossia/microglossia if the tongue is larger/smaller than normal. Of course, significant individual deviations from the normal size are possible – a reliable diagnosis can be only established if the deviation is major and causes problems. Reasons of macro/microglossia vary, we can classify them as congenital and acquired.

8.7.1. Congenital anomalies of the size of the tongue

Congenital macroglossia results from thickening of the muscle tissue (macroglossia muscularis), or can represent a diffuse lymphangioma or hemangioma (macroglossia lymphangiomatosa et hemangiomatosa). A partial macroglossia can be caused by struma lingualis or cysta ductus thyreoglossus. Macroglossia can also be a part of many other diseases, such as Down syndrome or cretinism (congenital hypothyreosis) due to a massive deposition of mucopolysaccharides in the muscle tissue of the tongue, the tongue can protrude from the mouth.

Congenital microglossia can also be a part of rare congenital craniofacial and extracranial anomalies. Hypoplasia of the tongue is usually associated with developmental disorder in the period between the 4th and 6th week of intrauterine development.

8.7.2. Acquired anomalies of the size of the tongue

Acquired macroglossia can be a consequence of haematopoiesis disorders (amyloidosis), metabolic disorders (glycogenoses), diseases of endocrine glands (myxoedema, acromegaly) or syphilis (syphilitic gumma).

Tumours causing enlargement of the tongue are not too common. Usually, they represent vascular anomalies such as lymphangioma (capillary, cavernous, cystic or, if multiple tumours are present, lymphangiomatosis) or haemangioma. Unlike lymphangioma, bluish discoloration can be seen through the mucosal surface in the latter as it is filled with erythrocytes (important for differential diagnosis). Focal enlargement of a part of the tongue can be caused by neurofibroma (Schwann cells tumour) – at that site, it is especially in association with Recklinghausen disease (neurofibromatosis).

Pseudobulbar palsy can cause microglossia due to a spastic cramp. If one-sided, the tip of the tongue aims to the affected side.

8.8. Pathologies of the coating of the tongue

The base coating of the tongue is formed by the epithelial parts of the filiform papillae that project above the level of the mucosa. Other parts of the coating (peeled-off epithelium, cellular detritus, saliva, bacterial microflora and food remnants) are its minor components. The intensity of the coating is determined by numerous processes, the foremost of which is the condition of the filiform papillae – their density, length and degree of keratinization. Other factors include the temperature and consistence of the food, chewing motor process and intensity (or reduction thereof in paralysis, loss of consciousness, etc.).

Physiologically, a thin whitish coating is normally present on the tongue. Such coating can be found in healthy individuals, its intensity however even in such people varies throughout the day both ways, depending on the daytime and food. The coating is usually the most intensive in the morning as the epithelial cells that peeled overnight and microorganisms are on the surface. In certain pathological conditions, however, the coating is either thickened or pathologically reduced.

The coating of the tongue is diagnostically very important. The tongue changes its appearance in various stages of a disease and it cannot be said that the manifestations are specific for some diseases (e.g. the so-called “strawberry tongue” in scarlet fever can also occur in other exanthema-associated diseases such as measles). The condition of the coating is rather a general indicator of the condition of the organism at any given moment. A dry, thickly coated, brownish tongue is a sign of a generally bad condition of the organism (typical e.g. for septic states). If the disease progresses, the coating sometimes creates a “skin-like” coating. When the patient’s condition improves, such “second skin” usually separates and a coating-free smooth tongue appears. Filiform papillae develop again within 2-4 weeks, which is, together with the moisturizing of the mucosa, a sign of recovery. A coating-free (smooth) tongue also indicates a metabolic disorder or circulatory insufficiency. As mentioned above, both extremes can develop over the course of a single disease.

8.8.1. Pathologically increased coating of the tongue

The increased thickness of the coating arises as a result of induration and increase in length of the filiform papillae and of increased keratinization of its epithelial projections. Acute coating develops rapidly, often within 24 hours of the onset of the disease. It is usually associated with serious acute diseases – serious infections (pneumonia, meningitis, sepsis, scarlet fever) or shock-associated diseases (acute abdomen, coma, serious myocardial infarction). In these diseases, the tongue self-cleaning is affected, the organism is dehydrated and high fever occurs. The tongue is often dry, with very obvious thick brown coating – individual papillae appear as if glued together (forming a kind of film) – **fuligo linguae**.

Besides this type, there are also other forms of acutely increased coating. As an example, we can mention a “fresh”, whitish coating that can be found in herpetic gingivostomatitis or allergic conditions. The tongue in this type of coating is moist (unlike in fuligo).

Pathologically increased tongue coating in chronic conditions is mostly associated with chronic lesions of the GIT. Such coating is often termed **dyspeptic coating**. It however may be present only during a certain stage of the disease, namely during exacerbation (of dyspepsia, gastric ulcer, gastritis, etc.). It does not reach the intensity of the acute coating, is often less obvious. A specific type of chronically increased coating of the tongue is **lingua villosa nigra**.

8.8.2. Pathologically reduced coating of the tongue

There are many transition states – from almost normal coating, through a coating in which filiform papillae are missing their keratinized prominences, up to a complete atrophy of the papillae. The coating may be lacking either across the entire tongue, or only on its parts. Most commonly, this is visible in **nutritional deficiency syndromes** such as in vitamin B-complex or Fe deficiency, in nutritional deficiency in cachectic states (hepatic cirrhosis, malignant diseases), or in **Sjögren syndrome**. The reduced coating of the tongue or its complete disappearance can also result from some drug intoxications (e.g. after Au or barbiturates intoxication).

Pathological changes of the tongue in deficiency states are usually termed by the traditional term glossitis, although strictly speaking, this term should from the pathological perspective only describe an inflammatory disease of the tongue. A more accurate term would probably be a “glossopathy” (or deficiency-associated lingual coating disorders). This group of diseases is etiologically variable.

The appearance of the deficiency-associated tongue is mostly atrophic, smooth (sometimes even glossy – completely without papillae). Mostly, it is atonic, smaller in size, with reduced tissue turgor, fissures or ulcerations may be sometimes present. The colour depends on etiology – pale red in anaemic diseases, dark red in hepatic cirrhosis, livid in cachexia. The patients complain about pain, burning or itching of the tongue. Deficiency-associated glossitis can appear in many diseases with negative metabolic balance – in inflammatory or malignant diseases, afflictions of GIT,

malabsorption, disorders of hepatic functions (including alcoholism), uraemia, chronic cardiac insufficiency and many other pathological conditions.

8.9. Inflammation of the tongue (glossitis)

The surface of the tongue can be divided according to the composition of the mucosa divided into two types. While the changes on the bottom of the tongue usually represent only a part of diffused changes of the lining mucous membranes, the mucosa of the dorsum of the tongue is usually the only affected surface and the clinical picture of the inflammation results from the structure of the dorsum of the tongue. Many changes on the tongue can be associated with multiple systemic diseases (glossitis atrophica can result from anaemia, avitaminoses or toxic effects of various substances). It is also necessary to assess the dynamics of the changes („wandering“ changes in lingua geographica). In the inflammations of the lingual mucosa, superficial (exudative) inflammations that only affect the mucosa must be distinguished from deep (interstitial) inflammations that penetrate deep into the mucosa.

8.9.1. Overview of glossitis

<i>Causes:</i>	<i>Objective findings:</i>
• Developmental deviations on the dorsum of the tongue	lingua plicata, lingua geographica
• Physical	
– mechanical:	erythema, fissures, erosions, necrosis, ulcer (traumatic glossitis)
– thermal:	erythema, vesicles (erosions), necrosis, ulcer
– electrogalvanic:	erythema, erosion, ulcer, lichenoid and hyperplastic changes
• Chemical	
– burns (acids, bases):	eschar (bases – grey; acids – colour varies according to the particular acid)
– pigments, antiseptics:	lingua villosa nigra
– others (smoking):	leukoplakia, lingua villosa nigra
• Infections	
– viral:	glossitis in herpetic gingivostomatitis, herpes zoster
– bacterial:	abscess, phlegmon, noma (if the organism is weak)
– cocci; streptococci:	strawberry tongue (scarlet fever)
staphylococci:	glossitis profunda, abscesses of the tongue
–TBC:	primary - ulcer secondary - tuberculoma
– syphilis:	primary – erosions, ulcer secondary – erosions, plaques muqueuses + opalines, lisses tertiary – gumma, glossitis interstitialis luetica, lingua lobata
– fungal:	oral candidosis, glossitis rhombica mediana, lingua villosa nigra; systemic mycoses
• Allergies	
– plant antigens, animal antigens, dietary proteins, chemicals, haptens:	Quincke’s oedema, glossitis venenata
• Immunopathological diseases	recurrent aphthae – ulcer, erosions (only major aphthae can manifest on the dorsum of the tongue) OLP – white lesion EEM – erosions covered by a fibrin pseudomembrane pemphigus, pemphigoid

9. Diseases of the oral cavity/manifestations in the oral cavity associated with pathology of the oral mucosa

9.1. Salivary secretion and its disorders

9.1.1. Saliva functions

Of the disorders of salivary secretion, reduced secretion is the more common problem; increased secretion is only rarely a reason for complaints. To better understand the consequences of insufficient salivation, let's make a short overview of the functions of saliva:

- a) **lubrication** – saliva helps in softening the food, creating food bolus, chewing, swallowing, it makes speaking easier, cleans the tissues of the oral cavity and protects teeth from damage.
- b) **digestion and taste perception** – saliva contains digestive enzymes (amylases and lipases) that initiate the cleavage of starchy substances. It facilitates taste perception of food and other substances.
- c) **regeneration of soft tissues** – epidermal (EGF) and transforming (TGF) growth factors present in the saliva help in the tissue growth, differentiation and healing of injuries.
- d) **maintaining the ecological equilibrium of the oral microflora** – saliva contains various antibacterial, antiviral and antifungal compounds instrumental in maintaining the microbial equilibrium and inhibiting bacterial colonization of teeth and soft tissues by altering the microbial adhesion capacity.
- e) **buffering activity** – the saliva has the capacity to reduce the acidity in the mouth and maintain it on the appropriate level, which reduces the risk of caries. The buffering capacity also protects the upper part of the GIT from the regurgitation from esophagus.
- f) **reminerzalization** – saliva protects the teeth and supports remineralization of the enamel as it contains essential minerals, which improves the mineral absorption into the demineralized tissue.
- g) **immunity** – small proteins, IgA, defensins, cytokins, growth factors, mucins and other components of the saliva may play a role in the natural immunity. Non-specific immune reactions are associated with the presence of many antibodies and enzymes in the saliva (lysozyme – kationic protein cleaving the components of bacterial cell wall; lactoferrin – a glycoprotein binding Fe^{3+} ions and thus depleting the environment of ions necessary for bacterial growth). Naturally occurring compounds with antiviral effect (leukocyte protease inhibitor, lactoperoxidase, etc.) can be also found in the saliva. Other compounds participating in the defence mechanisms of the body are also present in the saliva – the complement system with a significant cytolytic function also participates in phagocytosis (opsonisation) and inflammatory reaction. The cellular component of the non-specific immunity is represented by phagocytosis of cells of the mucosa (polymorphonuclear leukocytes, macrophages, Langerhans cells) that are at the same time acting as antigen-presenting cells in the oral cavity and are therefore important for triggering specific immune reaction.

The main specific defence mechanism of the oral mucosa is production of the sIgA. It is an IgA dimer, the molecules of which are connected by a so-called J-chain (joining chain). In addition, it carries a secretory component containing a glycoprotein serving as a transmembrane polymeric immunoglobulin IgA (and IgM) receptor, facilitating the transport of sIgA through the epithelial cell (transcytosis) and its protection from proteolysis.

9.1.2. Salivary secretion

Saliva is secreted by three pairs of major salivary glands and many minor mucosal salivary glands. The stable moisture of the oral mucosa is maintained predominantly by the minor salivary glands continuously secreting the saliva. On the contrary, the major salivary glands produce saliva mostly after stimulation. Such stimulation most commonly originates in the oral cavity with its mechanoreceptors and chemoreceptors. Salivary production is under physiological circumstances dependent on the degree of activity of the vegetative nerves and that activity is to a large degree given by the degree of mastication activity. The parotid gland produces serous secret, the sublingual and submandibular glands produce mixed saliva. As mentioned above, the salivary glands are innervated by the autonomous nervous system. The parasympathetic nerves into the submandibular and sublingual glands leave the intermediate nerve, run in parallel with the facial nerve across the chorda tympani and enter the glands together with the lingual nerve. The parasympathetic nerves for the parotid gland leave the glossopharyngeal nerve and enter the gland through the auriculotemporal nerve. Sympathetic nerves enter the glands together with the vessels. The nucleus salivatorius in the medulla oblongata serves as the “salivary control centre” and is in turn controlled by another “control centre” in the hypothalamus. Parasympathetic stimulation increases the production while anticholinergic drugs reduce the secretion. Irritation of the sympathetic nervous system results in production of thick saliva.

Quantitative analysis of the saliva (Škach’s test)

The examined person is instructed to spit all saliva collecting in the mouth into a graduated cylinder for 15 minutes. The saliva can be neither swallowed nor sucked out from glands. This way, the “**resting (unstimulated) salivary flow**” is established. Subsequently, the patient is given a paraffin tablet for chewing and the saliva produced while chewing is collected into another graduated cylinder (**stimulated salivary flow**). Those values are subsequently measured and summed up. Normal values are between 8 and 15 ml per 2x 15 minutes, any smaller values are considered pathological.

9.1.3. Salivary secretion disorders

Disorders of the salivary secretion concern in particular its quantity and can manifest in many diseases of the oral mucosa.

Ptyalism (sialorrhoea, hypersalivation)

This is an increase of salivary secretion that can occur under physiological circumstances based on conditioned reflexes (mostly pleasant stimulations of taste buds, smell, sight or hearing – Pavlov reflexes). An increased salivary production can be also observed in pregnancy as a result of hormonal and neurovegetative changes accompanying that condition.

Of pathological causes, infections must be mentioned in particular – many acute stomatitides are accompanied by reflex-induced salivation, sometimes combined with painful or difficult swallowing. It regresses spontaneously when the mucosal defects heal and does not require any therapy. Hypersalivation can be also a symptom of injuries to the mouth and salivary glands or their orifices. Other reasons for hypersalivation include poisoning by heavy metal salts (lead, arsenic, mercury) or disorders of the central nervous system (hemiplegia, bulbar palsy). Some medications (pilocarpine, prostigmine, iodides, etc.) can also induce the salivary gland secretion.

Th.: In some cases, it is unnecessary as it would regress spontaneously after the infection is gone; otherwise, a causal treatment according to etiology is indicated. Symptomatic treatment using atropine is possible.

Hyposialia (hyposalivation)

Salivary gland production can be reduced in many pathological conditions. In congenital salivary glands aplasia, the lack of saliva is self-explanatory. Reduced salivary production is observed in deficiency diseases (serious anaemia, avitaminosis), autoimmune diseases (Sjögren syndrome), or in metabolic diseases (diabetes mellitus, hypothyreosis, liver cirrhosis, etc.) where, besides the salivary secretion, reduced HCl production associated with hypoacidity (anacidity) symptoms is often observed. Hyposialia can be also present in advanced atherosclerosis; a likely reason is reduction of the stimulation for salivary production or involution of salivary glands.

Unconditioned production of saliva is usually more affected than the conditioned production. A major reduction of salivary production can be observed in cases of radiation-induced mucositis, which is associated with the destruction of minor salivary glands in patients with a tumour who undergo radiation therapy in the region of the head and neck. Hyposialia appears in infectious diseases of the oral mucosa, primarily only in acute erythematous candidosis associated with GIT dysmicrobia. It can also manifest in patients in whom the mucosal diseases collide with drug-induced hyposalivation (psychopharmaceuticals, parasympatholytics, non-selective antihistamines, etc.). It is also often present in patients with high fever in systemic acute diseases (where the reduced reflex salivary secretion combines with dehydration). It can be relatively often found in HIV-positive individuals (although it is debatable whether the true cause is a primary disease of salivary glands or drug-induced hyposalivation). Salivary secretion can be reduced to various degrees; due to a major

individual variability, we only suspect hyposalivation when subjective complaints are reported by the patient.

Xerostomia

Xerostomia (a constant sensation of dryness in the mouth) is a common consequence of hyposalivation. Other consequences of hyposalivation include difficulty chewing and swallowing (especially when eating dry food), sensitivity to spicy foods, unpleasant aftertaste, burning or even pain, pain of salivary glands or difficulty speaking.

In milder forms of hyposalivation, the oral mucosa appears to be clinically normal; in more severe forms, however, objective changes can be observed (i.e., besides the dryness of the mucosa, atrophy and/or erythema can be present, crevices can be found, the tongue is often smooth, dry and wax-like glossy. Lachrymal glands can be also present, with corresponding manifestations of dry keratoconjunctivitis.

There are many reasons (acute and chronic) that can provoke hyposalivation (objective finding) and xerostomia (subjective):

- a) congenital salivary glands hypoplasia or aplasia
- b) inflammation of salivary glands – in particular parotitis epidemica (Mumps), TBC, sarcoidosis, actinomycosis
- c) tumours – both primary tumours of salivary glands or secondary infiltrations of other tumours
- d) blocked orifices – lithiasis, tumours, inflammatory changes
- e) atrophy of the salivary glands – senile, postradiation inflammations
- f) autoimmune diseases – Sjögren syndrome, Mikulicz syndrome
- g) drugs – anticholinergics, opiates, ergotamine and many others
- h) Other factors – dehydration, vitamin deficiency, diabetes mellitus, hypothyroidism, anaemia, advanced atherosclerosis, emotional disorders (depression), etc.

Th.: Causal treatment, otherwise symptomatic therapy. Salivary production can be stimulated by medications (mostly pilokarpine, a parasympathomimetic-acting alkaloid). The effect is however very individual and cardiovascular side effects can occur, it is therefore also necessary to take the general condition of the patient and contraindications into account. Reflex stimulation by sucking sugar-free candies or chewing sugar-free chewing gums, more frequent drinking (without caffeine, alcohol or sugar) can be beneficial. If this does not lead to success, substitution by artificial saliva is necessary (or other means that are on the market now such as moisturizing gels, special mouthwashes, toothpastes, chewing gums or drops).

9.2. Glossodynia and stomatodynia

The term glossodynia (or stomatodynia) describes unpleasant feelings in the oral cavity for which no objective grounds are usually found. Most commonly, it is burning of the tongue (therefore glossodynia). Stomatodynia is a broader term used in situations when the complaints are associated with multiple regions of the oral cavity. The reasons can be both internal and external – hormonal changes, atherosclerosis, psychogenic influences, neuroanemic syndrome without mucosal changes, etc.

Stomatodynia in a broader sense of the word can also describe conditions where unpleasant feelings in the oral cavity are associated with an objective finding, e.g. stomatodynia in deficiency diseases such as Plummer-Vinson syndrome, Sjögren syndrome, etc.

Stomatodynia in the narrow sense of the word means conditions with no obvious pathological changes in the oral cavity and negative results of general (systemic) examinations. Stomatodynia can occur due to psychogenic influences, hormonal disorders in the menopause, or in atherosclerosis. Most commonly, middle-aged and elderly women between 45 and 70 years of age are affected (under 30 years of age, occurrence of stomatodynia is very rare). It is likely that multiple mechanisms participate in stomatodynia development, including the constitutional predisposition of the organism (rich in sensitive innervation), terrain predisposition (neuropathic or psychoneuropathic terrain), acute predisposition (e.g. menopause) and a triggering mechanism (that can be represented in principle by any painful or unpleasant impulse including a simple dentistry procedure).

Clinical picture: The patient complains about unpleasant sensations in the oral cavity, such as sensation of paresthesia (burning, itching, pain, dryness, aftertaste). The objective finding on the oral mucosa however does not correspond with the described complaints or is completely normal. The tongue is most commonly affected (in approximately 80 % of cases), followed by the palatal mucosa and, less commonly, other regions. The complaints can be of wandering character and their intensity can fluctuate.

Dg.: Establishing diagnosis requires a meticulous taking of the patient's history (search for a possible cause in systemic diseases), a detailed examination of the oral cavity (examination of the teeth, prosthetic devices, galvanic currents, microbiology), overall examination of the patient (expert opinions from other fields of medicine, including psychiatric and neurological examinations) and lab tests (blood count, biochemistry, plasmatic Fe levels), X-ray of the cervical spine and of the temporomandibular joints. For example, atypical forms of neuralgias of glossopharyngeal nerves may manifest by lingual pain only.

Th.: Glossodynia (and stomatodynia) can be looked upon not just as a disease but as a manifestation that can accompany various afflictions. As a broad range of provoking factors can result in this problem, it is necessary to identify and treat the causal factor (e.g. galvanic irritation) or disease (e.g. pernicious anaemia). If the cause cannot be identified, vitamins, antibiotics, anabolics, physical treatment, sedatives and psychotherapy can all be tried.

9.3. Bad breath (foetor ex ore, halitosis)

Foetor ex ore, also called mouth odour or halitosis, is defined as intensive odour from the oral cavity. It is therefore a symptom the manifestation of which can be associated with many local, intraoral, causes as well as extraoral factors (pathological changes in the nasopharynx, sinuses, lungs, or smell of food the patient has eaten).

Causes:

a) local:

- in the mouth:
 - insufficient hygiene, dental plaque, gangrenous teeth, periodontal pockets
 - retention of remnants of the food in carious teeth or under prosthetic devices
 - mucosal diseases: ulcerative gingivostomatitis, post-extraction coagulum decay, ulcerative tumours, etc.
- nose: chronic rhinitis and sinusitis (in particular ozaena), tumours
- nasopharynx: tonsillitis, pharyngitis (particularly the chronic atrophic forms)
- pharynx: if diverticula, strictures or disintegrating tumours are present
- lungs: bronchiectasis, pulmonary abscesses

b) systemic diseases:

- diabetes mellitus (acetone odour)
- uraemia (ammoniac)
- lead intoxication (sweetish metallic)

The bad breath can also follow ingestion of some foods (onion, garlic, alcohol) – the odour has its origin in metabolic products that are, following absorption into the organism from the GIT, excreted from the bloodstream in the lungs.

Th.: Causal, i.e., requiring identification and removal of the cause. Adherence to the rules of the oral hygiene, perfect dental treatment; if diseases are at fault, their treatment. Locally, deodorants or antiseptic means for washing the mouth can be used (hydrogen peroxide, CHX in commercially produced preparations, etc.).

10. Treatment of mucosal diseases

10.1. General rules for treatment of mucosal diseases

In most mucosal diseases we routinely encounter in the dental practice, local treatment is sufficient. **Systemic therapy** (antibiotics, antimycotics, antivirotics) is usually indicated in a serious course of infectious diseases; such drugs should always be administered if the infection is found in an immunodeficient person or in patients otherwise susceptible to a rapid disease progression.

Systemic therapy is also relevant where an immunopathological disease is concerned. If we suspect an allergic reaction, antihistamines and corticoids are indicated, which should be followed by a complex allergological examination. In blistering and autoimmune epithelial diseases (especially pemphigus, systemic lupus erythematosus, scarring pemphigoid, etc.), systemic corticoids, often combined with immunosuppressants, are administered, the therapy is however always to be prescribed and managed by a dermatologist. Similar situation (treatment shall be managed by a dermatologist) applies to other cutaneous diseases that can manifest in the oral cavity (e.g. a more serious course of erosive and bullous forms of oral lichen planus).

Causal treatment is focused on the true cause of the disease (e.g. antivirotics in herpes zoster facialis). The situation when we have to make do with just symptomatic treatment is however far more common (analgesia, antipyretic or anti-inflammatory medication).

Preventive administration of some drugs (mostly antibiotics, antimycotics, antivirotics) is reasonable in some individuals to prevent infectious complications or recurrences. Patients who may benefit from such prophylactic treatment include individuals with recurrent oral candidosis and serious predisposing factors, in HIV-positive patients with recurrent infections or in people in whom a herpetic infection often provokes an acute manifestation of erythema multiforme.

The first step after establishing diagnosis or preliminary diagnosis of the mucosal disease is to **remove all mechanical irritation** that could cause injuries to the mucosa (sharp edges of the teeth, of dentures, orthodontic apparatuses). Next come the **lifestyle measures**. The patients must be advised to avoid spicy and irritant food (note that citrus, paprika, tomatoes, onion, garlic, etc. frequently also act as irritants) and to mind the suitable consistency of the food. The oral hygiene is to be performed thoroughly but with care using a soft toothbrush (use of a single tuft toothbrush and interdental toothbrushes is recommended). Depending on the diagnosis, we may or may not recommend the use of mouthwashes; those containing ethanol and other irritant substances (propylene glycol, menthol, etc.) are always to be avoided. In extensive lesions, washing the mouth with herbal infusions (using herbs with antiseptic and epithelialization effects such as sage) is preferred; potential allergic reactions must always be taken into account.

Local therapy is indicated in most oral mucosal diseases. Mostly, this includes mouthwashes, mucoadhesive pastes with antiseptic, antiflogistic, epithelialization, anaesthetic or adstringent effects. There is only a limited number of preparations intended for the local therapy of the oral cavity

in the form of mucoadhesive pastes/gels and it is therefore sometimes useful to prescribe custom-made preparations (magistral prescriptions). The dentist should be aware of the active substances and their effects in the widespread mouthwashes and gels to be able to choose a product suitable for the patient. The principal antimicrobial agent is chlorhexidine with its antibacterial, antifungal and antiviral effects. The main indication for its use are therefore bacterial infections and prevention from secondary infection, especially in diseases causing erosions and ulcerations on the oral mucosa (recurrent aphthae, traumatic ulcers, etc.), viral infections (especially herpetic or enteroviral), and oral candidosis. The recommended chlorhexidine concentration for the use in the oral cavity is 0.12-0.2 %, it should always be administered only for a short term (0.2 % no more than two weeks). Hexetidine and benzydamine have somewhat weaker antiseptic effects and are used predominantly for their anti-inflammatory and mild anaesthetic effects. In treatment of acute necrotising ulcerative gingivitis, hydrogen peroxide in appropriate concentrations (different for home care and clinical care) remains the prescription of the first choice. In oral candidosis, we at present use a magistral prescription for a nystatin suspension. If the patient's diagnosis is prosthetic stomatitis, the hygiene of the dentures is also of utmost importance. In case of immunopathological diseases (recurrent major aphthae, pemphigus, pemphigoid, erosive and bullous forms of the oral lichen planus), a short-term local corticosteroid treatment is usually indicated (at present, it is also a magistral prescription).

In local treatment of extensive erosions, consideration must be given to the possibly rapid resorption of the active substances through the eroded mucosa. In such cases, rinsing the mouth with herbal infusions possessing antiseptic and epithelialization effects (e.g. sage) is preferred.

The local treatment must be modified in children. If they are of age when they are unable to spit out the mouthwash, it is necessary to instruct the parents to gently apply a mild antiseptic preparation (e.g. hexetidine in oral candidosis in infant age) using a pad or swab.

For treating changes on the lip red, many other local preparations with antibacterial, antimycotic, epithelialization and anti-inflammatory effects are available. It is necessary to heed the manufacturer-recommended maximum duration of the therapy.

If the lesion does not react to the local treatment within one to two weeks, the patient should be referred to a specialized department.

10.2 New trends in the treatment of oral mucosal diseases

Like in other diseases, the research in the field of therapy of oral mucosal diseases keeps bringing novel treatment protocols and approaches.

10.2.1. Ozone therapy

Ozone for the use in dentistry is produced by so-called "plasma lamps"; the amount of the ozone produced is minimal. Germicidal properties of ozone are associated with its high oxidation potential. Its action can eliminate bacteria, viruses, protozoans and yeasts as well as their

products and necrotic remnants (Domb, 2014). The action of ozone stimulates the immune response and microcirculation in the gingiva.

Ozone therapy is painless, quick and has no side effects. It can be used as a supplementary therapy in gingivitis, herpetic diseases, stomatitis, recurrent aphthae, crevices, alveolitis, yeasts infections and other diseases of the oral cavity. In **OLP**, a corticoid therapy combined with ozone therapy was found more effective than laser therapy (Kazancioglu a Erisen, 2015). Thanks to the antibacterial effects of ozone, it can be a useful tool in treatment of **halitosis**. A topical ozone therapy combined with antivirotic and laser therapy helped reduce pain, shorten the course of the disease and improve patients' condition in patients with **herpes zoster**; it was statistically significantly more efficient than antiviral treatment without the use of ozone (Huang et al., 2018). If ozone is used early, while the patient only complains of burning and itching, the blisters may be completely prevented.

Ozone therapy however still requires establishing safe, well-defined parameters and guidelines based on randomized controlled trials that would provide indications of ozone therapy for treatment of various pathological conditions (Nogales et al., 2008).

10.2.2. Laser therapy

In the treatment of oral mucosal diseases, it is also possible to employ biostimulation lasers supporting tissue regeneration and healing. These so-called LLLT lasers (low-level laser therapy) emit energy as a beam of electromagnetic radiation. In **oral mucositis**, laser therapy was shown to reduce the extent and intensity of the disease as well as to shorten its overall duration (Carvalho et al., 2011). As many pilot studies demonstrated, treatment of **recurrent aphthae** using LLLT provides satisfactory results including pain reduction and shortening of the time needed for ulcer healing, no standardized protocol is however in place yet (Valo et al., 2015). The laser therapy can also serve as an auxiliary treatment to corticosteroid administration in individuals with **mucosal pemphigoid** (Yilmaz et al., 2010). It can be used in treatment of **herpes simplex** as well (Ferreira et al., 2011), even in children (Stona et al., 2014).

10.2.3. Biological treatment

Biological treatment based in particular on monoclonal antibodies is used in the treatment of squamous cell carcinoma of the oral mucosa, autoimmune diseases affecting salivary glands (Sjögren syndrome) and oral mucosa (pemphigus vulgaris, benign mucosal pemphigoid), as well as in some other diseases of the oral mucosa with uncertain etiological participation of immunopathology (OLP, recurrent major aphthae, Behçet disease). The action of the biological treatment in particular indications is based on the inhibition of the proliferation activity of the tumour cells and angiogenesis (cytostatics) or on suppression of effects of pro-inflammatory cytokines, particularly TNF α , IL-1 and IL-6. Most commonly, biological treatment agents such as rituximab,

cetuximab and erlotinib are indicated in treatment of the above-described diseases (Slezák et al., 2013). Biological treatment shall be always prescribed by a specialist.

10.2.4. Other substances potentially useful in treatment of mucosal diseases

Prevention of the mucosal diseases includes maintaining oral hygiene, healthy lifestyle (diet, non-smoking, physical activity), avoiding potentially dangerous influences (especially excessive use of xenobiotics), etc. In treatment of oral mucosal diseases, many other substances can be used; they can be locally administered in the form of solutions, mucoadhesive pills, etc.

Levamisol, originally an antihelmintic veterinary drug, was used in patients with **serious recurrent aphthae, OLP and pemphigus vulgaris** with promising results.

Vitamin D belongs to a group of lipid-soluble steroids; in humans, the vitamin D₃ and D₂ are the most important forms, the primary function of which is the regulation of the homeostasis of Ca²⁺ and phosphorus in the organism. It plays also a role in the process of carcinogenesis and has immune modulation effects. It also influences the condition of the oral mucosa. Its reduced serum concentrations are a common finding in patients with autoimmune diseases, recurrent aphthae, **Behçet disease, Sjögren syndrome and neoplastic lesions**. Supplementing vitamin D has a great potential in treatment of patients with oral mucosal diseases in whom hypovitaminosis is clinically confirmed by lab tests and kidney disease is excluded. It can also have a preventive function (Anand et al., 2017).

Resveratrol is a phytoalexin synthesized by many plants; it is present in relatively large quantities in the red/blue grapes and it is reported to have antioxidative, anti-inflammatory, cardioprotective, neuroprotective and immunomodulation effects (Perrone et al., 2017).

Other substances that can be used for supplementary therapy of oral diseases include e.g. **ginger** (*Zingiber officinale*), **quercetine** (plant flavonoid present in many species of fruit and vegetable), **aloe vera** and many other natural materials and substances.

Acknowledgement

Creating this textbook was supported by the project of the University Development Fund No. MUNI/FR/1412/2018, granted to the Masaryk University, and in part by the Ministry of Health, grant NV17-30439A.

References

- Anand A, Singh S, Sonkar AA, Husain N, Singh KR, Singh S, Kushwaha JK. Expression of vitamin D receptor and vitamin D status in patients with oral neoplasms and effect of vitamin D supplementation on quality of life in advanced cancer treatment. *Contemp Oncol*. 2017;21(2):145-51.
- Bakhtiari S, Sehatpour M, Mortazavi H, Bakhshi M. Orofacial manifestations of adverse drug reactions: a review study. *Clujul Med*. 2018;91(1):27-36.
- Bardellini E, Amadori F, Conti G, Majorana A. Oral mucosal lesions in electronic cigarettes consumers versus former smokers. *Acta Odontol Scand*. 2018;76(3):226-228. doi: 10.1080/00016357.2017.1406613.
- Bereš M, Ďurovič E, Hügecová A, Hügec P. Výber poznatkov o lichen ruber planus. *Čes stomatol Prakt zubní lék*. 1999;99/47(4):112-18.
- Carvalho P a. G, Jaguar GC, Pellizzon AC, Prado JD, Lopes RN, Alves FA. Evaluation of low-level laser therapy in the prevention and treatment of radiation-induced mucositis: a double-blind randomized study in head and neck cancer patients. *Oral Oncol*. 2011;47(12):1176-81.
- Ciferská H, Horák P, Heřmanová Z, Ordeltová M, Zadražil J. Sjögrenův syndrom. *Interní Med*. 2006;10:423-426.
- Dios PD, Scully C, Almeida OP de, Bagán JV, Taylor AM. Ulcers and erosions: aphthae. *Oral Medicine and Pathology at a Glance*. 2nd ed. Ames, Iowa: John Wiley & Sons; 2016. s. 64-67.
- Domb WC. Ozone therapy in dentistry. A brief review for physicians. *Interv Neuroradiol*. 2014;20(5):632-36.
- Fassmann A, Dvořáková A, Wotke J. Pemfigus vulgaris v orofaciální oblasti. *Zborník 4 Medzinárodnej stomatologickej konferencie*. Bratislava; 1996. s. 45-50.
- Ferreira DC, Reis HLB, Cavalcante FS, Santos KRND, Passos MRL. Recurrent herpes simplex infections: laser therapy as a potential tool for long-term successful treatment. *Rev Soc Bras Med Trop*. 2011;44(3):397-99.
- Fidel PL, Huffnagle, GB. *Fungal Immunology : From an Organ Perspective*. Ashman R., Farah C. US: Springer, 2005. Dostupný z [www: http://springerlink.metapress.com](http://springerlink.metapress.com). Oral candidiasis: Clinical manifestations and cellular adaptive host responses, s. 59-83.
- Jurge S, Kuffer, R.; Scully, C.; Porter, S. R.: *Mucosal Disease Series*. Number Vi. Recurrent aphthous stomatitis. *Oral Dis*. 2006;12(1): 1-21.
- Grein Cavalcanti L, Lyko KF, Aralljo RL, Amenabar JM, Bonfim C, Torres-Pereira CC. Oral leukoplakia in patients with Fanconi anaemia without hematopoietic stem cell transplantation. *Pediatr Blood Cancer*. 2015;62(6):1024-26.

- Gurín D, Slávik M, Shatokhina T, Kazda T, Šána J, Slabý O, Hermanová M. Current perspective on HPV-associated oropharyngeal carcinomas and the role of p16 as a surrogate marker of high-risk HPV. *Klin Onkol.* 2019; 32(4): 252-260.
- Handley TP, McCaul JA, Ogden GR. Dyskeratosis congenita. *Oral Oncol.* 2006;42:331-36.
- Huang J, Huang J, Xiang Y, Gao L, Pan Y, Lu J. [Topical ozone therapy: An innovative solution to patients with herpes zoster]. *Zhong Nan Da Xue Xue Bao Yi Xue Ban.* 2018;43(2):168-72.
- Irani S. Herbal medicine and oral health: A Review. *J Int Oral Health.* 2016;8(10):989-94.
- Jelenová H. HLA systém a některé choroby v dutině ústní: Souborný referát. *Čes Stomat.* 1995;95(4):138-42.
- Kalmar JR. Oral Manifestations of drug reactions. *Medscape.* 2016.[vid. 2018-09-12] Dostupné z: <https://emedicine.medscape.com/article/1080772-overview#a4>
- Kauzman A, Pavone M, Blanas N, Bradley G. Pigmented lesions of the oral cavity: review, differential diagnosis, and case presentations. *J Can Dent Assoc* 2004;70(10):682-83f.
- Kazancioglu HO, Erisen M. Comparison of low-level laser therapy versus ozone therapy in the treatment of oral lichen planus. *Ann Dermatol.* 2015;27(5):485-91.
- Kovach I, Kravchenko L, Khotimska Y, Nazaryan R, Gargin V. Influence of ozone therapy on oral tissue in modeling of chronic recurrent aphthous stomatitis. *Georgian Med News.* 2017;3(264):115-19.
- Kovalová E. Orálna hygiena: 3. časť Ilustrovaný atlas orálneho vyšetrenia. Prešov: Pavol Šidelský - Akcent print, 2010. 273-282 s. ISBN 978-80-89295-24-1.
- Laskaris G. Color atlas of oral diseases. 2nd ed. New York: Thieme Medical Publishers; 1994.
- Malek R, Gharibi A, Khlil N, Kissa J. Necrotizing ulcerative gingivitis. *Contemp Clin Dent.* 2017;8(3):496-500.
- McCarthy PL, Shklar G. Diseases of the oral mucosa. 2nd ed. Philadelphia: Lea & Febiger; 1980.
- Mehanna HM, Rattay T, Smith J, Mcconkey CC. Treatment and follow-up of oral dysplasia-a systematic review and meta-analysis. *Head Neck.* 2009;31(12):1600-9.
- Michalusová I, Dostálová T, Kozák J, Hubáček M. Vaskulární anomálie – hemangiomy. Možnosti jejich diagnostiky a terapie. *Prakt zub Léč,* 2011; 59(5):94-100.
- Ministerstvo zdravotnictví české republiky. Metodický návod k řešení problematiky infekce HIV/AIDS v České republice. *Věstník MZ* č. 10/2016. 2016. online: http://www.mzcr.cz/dokumenty/vestnik-c10/2016_13122_3442_11.html Citováno dne 12. 11. 2019.
- Napier SS, Speight PM. Natural history of potentially malignant oral lesions and conditions: an overview of the literature. *J Oral Pathol Med.* 2008;37(1):1-10.

- Nogales CG, Ferrari PH, Kantorovich EO, Lage-Marques JL. Ozone therapy in medicine and dentistry. *J Contemp Dent Pract.* 2008;9(4):75-84.
- Perrone D, Fuggetta MP, Ardito F, Cottarelli A, De Filippis A, Ravagnan G, De Maria S, Lo Muzio L. Resveratrol (3,5,4'-trihydroxystilbene) and its properties in oral diseases. *Exp Ther Med.* 2017;14(1):3-9.
- Otten JV, Hashimoto T, Hertl M, Payne AS, Sitaru C. Molecular diagnosis in autoimmune skin blistering conditions. *Curr Mol Med.* 2014;14(1):69-95.
- Plucarová B, Roubalíková L. Orální projevy HIV infekce. *Čes stomatol Prakt zubní lék.* 1997;97/45(5):73–85.
- Reichart PA, Philipsen HP. Oral erythroplakia-a review. *Oral Oncol.* 2005;41(6):551-61.
- Scully C. Oral and maxillofacial medicine: the basis of diagnosis and treatment. Churchill Livingstone; 2nd Revised edition 2008. Sharma S, Ali FM, Saraf K, Mudhol A. Anti-helminthic drugs in recurrent aphthous stomatitis: a short review. *J Pharm Bioallied Sci.* 2014;6(2):65-68.
- Silverman S Jr, Gorsky M, Lozada F. Oral leukoplakia and malignant transformation. A follow-up study of 257 patients. *Cancer.* 1984;53:563-68.
- Skoupilová M, Mejchar B. Onemocnění ústní sliznice. Olomouc; 1991.
- Slezák R, Dřízhal I, Horáček J, Kopecký O. Infekční choroby ústní sliznice. Praha: Grada; 1997.
- Slezák R, Kopecký O, Krejsek J. Recidivující afty. Praha: Galén; 2000.
- Slezák R, Lindrová I, Buchta V, Paulusová V, Šustová Z, Kopecký O, Ryšková L. Přehled novějších možností ve farmakoterapii nemocí ústní sliznice, slinných žláz a parodontu. *Čes Stom.* 2013;113(3):64-73.
- Slezák R, Rencová E, Krejsek J. Sjögrenův syndrom - polysystémové onemocnění. Pohled stomatologa, oftalmologa a klinického imunologa. *Folia Gastroenterol Hepatol.* 2003;1:30-47.
- Slezák R, Ryška A. Kouření a dutina ústní. Praha: Havlíček Brain Team; 2006.
- Slootweg PJ, Eveson JW. Tumours of the Oral Cavity and Oropharynx. In: Barnes L, Eveson JW, Reichart P, Sidransky D, eds. World Health Organization classification of tumours. Pathology and genetics of head and neck tumours. 4th ed Lyon: IARC Press 2017.
- Stona P, da Silva Viana E, Dos Santos Pires L, Blessmann Weber JB, Florian Kramer P. Recurrent labial herpes simplex in pediatric dentistry: low-level laser therapy as a treatment option. *Int J Clin Pediatr Dent.* 2014;7(2):140-43.
- Stoopler ET, Sollecito TP. Oral mucosal diseases: evaluation and management. *Med Clin North Am.* 2014;98(6):1323-52.
- Škach M et al. Onemocnění ústní sliznice. Praha: Avicenum; 1982.

- Škach M, Švejda J, Liška K. Onemocnění ústní sliznice : patologie, terapie a diferenční diagnostika onemocnění ústní sliznice. Praha: Avicenum; 1975.
- Tyldesley WR. Oral medicine. 2nd ed. Oxford: Oxford University Press; 1981.
- Vale FA, Moreira MS, de Almeida FCS, Ramalho KM. Low-level laser therapy in the treatment of recurrent aphthous ulcers: a systematic review. *Scientific World Journal*. 2015;2015:150412.
- Venclíková Z, Mrklas L. Výskyt metabolických pigmentací gingivy. *Čes stomatol Prakt zubní lék*. 1999;99/47(5):151-54.
- Waal I. Oral leukoplakia, the ongoing discussion on definition and terminology. *Med Oral Patol Oral Cir Bucal*. 2015;20(6):e685-92.
- Waal I. Oral leukoplakia, the ongoing discussion on definition and terminology. *Med Oral Patol Oral Cir Bucal*. 2015;20(6):e685-92.
- Wotke J. Patologie orofaciální oblasti. Praha: Grada; 2001.
- Yilmaz HG, Kusakci-Seker B, Bayindir H, Tözüm TF. Low-Level Laser Therapy in the treatment of mucous membrane pemphigoid: a promising procedure. *J Periodontol*. 2010;81(8):1226-30.
- Yuan A, Woo SB. Adverse drug events in the oral cavity. *Oral Surg Oral Med Oral Pathol Oral Radiol*. 2015;119(1):35-47.
- Záruba F et al. Dermatovenerologie. Praha: Univerzita Karlova; 1992.

Appendix

Overview of drugs that can lead to the development of oral mucosal diseases, xerostomia or alterations of taste perception

Diseases of the oral mucosa	Medications group	Active substance
stomatitis medicamentosa (drug-induced stomatitis)	antianginal drugs	Nicorandil
	ATB	metronidazole, penicillin, erythromycin, tetracycline
	antiepileptics	clonazepam, hydantoins, lamotrigin
	antidepressants	imipramine, fluoxetine
	antihypertensives	captopril, enalapril, propranolol
	antiretrovirotics	ritonavir, saquinavir, zidovudine
	antimalarials	chloroquine
	chemotherapeutics	cisplatin, cyclosporine, doxorubicin, methotrexate, vincristine
	anti-inflammatory drugs	ibuprofen, salicylic acid, naproxen, indomethacin
immunosuppressants	sirolimus	
ulcerations and mucositis	cardiac drugs (beta blockers, ACE inhibitors)	propranolol, captopril
	sympathomimetics	methyldopa
	sedatives	barbiturates
	anxiolytics	meprobamate
	ATB	sulfonamides, tetracyclines
	urological drugs	tadalafil
	laxatives	phenolphthalein
	diuretics	thiazide derivatives, spironolactone
	antidiabetics	tolbutamide
	bisphosphonates	alendronate
	NSAIDs	salicylates, indomethacin, Au salts, naproxen, phenazone

		derivatives
	antirheumatics	penicillamine, phenylbutazone
	antiepileptics	phenytoin
	antineoplastics	methotrexate, 5-fluorouracil, doxorubicin, melphalan
	chemotherapeutics	dapsone
	imunomodulators	
	antiseptics	hydrogen peroxide, phenol, potassium tablets
swellings	ATBs	penicillin and its derivatives, sulphonamide, cephalosporin
	NSAIDs	acetylsalicylic acid
	cardiac drugs (ACE inhibitors)	
	sedatives	barbiturates
xerostomia and hyposalivation	sympatholytics	
	sympathomimetics (beta2- agonists)	
	retinoids	
	cytotoxic agents	
	muscle relaxants	
	decongestants	
	antihistamines	
	antihypertensives	
	diuretics	
	protease inhibitors	
	proton pump inhibitors, antacids	
	antimuscarinic agents, anticholinergics	
	antidepressants	
	sedatives	
	anxiolytics	
	anti-inflammatory drugs	
	opioids and cannabinoids	

	antiparkinsonics	
	antiepileptics	
increased susceptibility to infection (oral candidosis)	ATBs	
	immunosuppressants	
	corticosteroids	
	chemotherapeutics	
gingival hyperplasia	antiepileptics	phenytoin, valproate
	antihypertensives (calcium channel blockers)	nifedipine, amlodipine, diltiazem, verapamil
	cardiac drugs (dihydropyridines)	bleomycin
	chemotherapeutics	cyclosporine
	immunosuppressants	
	oestrogens	
increased gingival bleeding	anticoagulants	
	NSAIDs	acetylsalicylic acid
altered taste perception	cardiac drugs (beta blockers, calcium channel blockers)	
	neurostimulants	
	ATB	metronidazole
	others	nicotine
pigmentations	laxatives	phenolphthalein
	cardiac drugs (potassium channel blockers)	amiodarone
	antimalarials	chloroquine
	oestrogens	
	sedatives	chlorpromazine
	antivirotics	zidovudine
	cytostatics	clofazimine
	antimycotics	ketoconazole
	antineoplastics	imatinib
	chemotherapeutics	busulfan
	cytostatics	cyclophosphamide

	ATB	tetracycline (minocycline)
OLL	anti-alcohol drugs	cyanamide
	antihyperuricemics	allopurinol
	antidiarrheals	bismuth
	antidiabetics	chlorpropamide, glipizide, insulin, tolbutamide
	antihistaminics	cimetidine, cinnarizine, triprolidine
	antimycotics	amphotericin B, ketoconazole
	antiretrovirotics	zidovudine
	antihypertensives	atenolol, beta blockers, captopril, chlorothiazide, enalapril, furosemide, hydrochlorothiazide, methyldopa, metoprolol, oxprenolol, propranolol, spironolacton
	antiepileptics	carbamazepine, oxacarbazepine, phenytoin, valproate
	NSAIDs	salicylates, diflunisal, ibuprofen, indomethacin, naproxen, rofecoxib, sulindac
	antimalarials	quinine derivatives, pyrimethamine
	ATB	isoniazid, rifampicin, streptomycin, tetracyclines
	cardiac drugs (ACE inhibitors, beta blockers, potassium channel blockers)	flunarisine
	chemotherapeutics	dactinomycin, imatinib, palladium
	immunomodulators	dapsone, Au salts, levamisole, interferon alpha
	antirheumatics	penicillamine
psychopharmaceuticals	levomepromazin, lithium,	

	(benzodiazepines, tricyclic antidepressants)	lorazepam, phenothiazines, pyritinol
	diuretics	furosemide
EEM and Stevens-Johnson syndrome	ATB	penicillins, sulfonamides, tetracyclines, amoxicillin, clavulanic acid
	antimalarials	
	antihyperuricemics	allopurinol
	psychopharmaceuticals	barbiturates
	protease inhibitors	
	NSAIDs	
	antiepileptics	phenytoin, lamotrigin
pemphigus	NSAIDs	ibuprofen, piroxicam, Au salts
	antirheumatics	phenylbutazone, penicillamine
	antidiabetics	glibenclamide
	antitubercular drugs	ethambutol
	diuretics	theobromine
	cardiac drugs (beta blockers)	propranolol, captopril, practolol
	psychopharmaceuticals	barbiturates (phenobarbital), pyritinol, heroin
	ATB	ampicillin, cephalixin, rifampicin
	others	thiopyridoxine, mercaptopropionyl glycine
pemphigoid	ATB	penicillins, sulfonamides
	antirheumatics, NSAIDs	penicillamine, ibuprofen, phenacetin
	cardiac drugs	furosemide, captopril, clonidine
LE-like reactions	ATB	streptomycin
	antirheumatics	penicillamine
	NSAIDs	Au salts
	psychopharmaceuticals	lithium, chlorpromazine

sympathomimetics	methyldopa
antimalarials	quinine derivatives
antiepileptics	carbamazepine, ethosuximide, hydantoins, primidone, trimethadion
antimitotics	griseofulvin
antitubercular drugs	isoniazid
antiarrhythmics	procainamide
antihypertensives	reserpine
vazodilatints	hydralazine
others	thiouracil

List of Figures

Fig. 1: A schematic view of the microscopic structure of the skin and oral mucosa (Škach et al., 1982)	12
Fig. 2: An illustration of keratinizing epithelium (Tyldesley, 1981).....	13
Fig. 3: A simplified chart of the basal complex of the oral epithelium: connection of basal cells and connective tissue by means of hemidesmosomes (Tyldesley, 1981).....	14
Fig. 4: The schematic view of basic histopathological changes (Záruba et al., 1992)	18
Fig. 5: Primary efflorescences of the oral mucosa (Záruba et al., 1992).....	20
Fig. 6: Secondary efflorescences of the oral mucosa (Záruba et al., 1992).....	21
Fig. 8: Etiology of exogenous pigmentations.....	45
Fig. 9: To establish the diagnosis of Sjögren Syndrome, at least 4 criteria must be met, one of which must be a positive biopsy or positive detection of antibodies (diagram acc. to Ciferská et al., 2000; Slezák et al., 2003)	81
Fig. 11: Classification of melanin pigmentations according to the etiopathogenesis.....	106
Fig. 12: Dif. dg. of diseases with oral white lesions as a prominent clinical symptom (Škach et al., 1975).....	118
Fig. 13: Dif. dg. of diseases with red lesions as a prominent clinical symptom.....	119
Fig. 14: Differential diagnosis of erosions (amended from Škach et al., 1975).....	120
Fig. 15: Dif. dg. of vesicular diseases (Škach et al., 1975)	121
Fig. 16: Dif. dg. of diseases with a bulla as a principal structure (Škach et al., 1975).....	121
Fig. 17: Dif. dg. of diseases with blisters as the principal structure (amended from Otten et al., 2014). The clinical finding must be augmented by a histopathological examination and subsequent direct and indirect immunofluorescence. Molecular-biological techniques such as ELISA, immunoblotting, immunoprecipitation, etc. often play a key role in the differential diagnosis.	122
Fig. 18: Differential diagnosis of ulcerations (Škach et al., 1975).....	123

List of Tables

Tab. 1: Potentially malignant diseases of the oral mucosa.....	110
Table 2: Diagnostic criteria for epithelial dysplasia. The N/C rate (nuclear:cytoplasmic ratio, the ratio of the volume of the nucleus and the cytoplasm) relates to the cell maturity.....	112
Table 3: Classification systems for the oral epithelial dysplasia.....	112

University textbook on oral mucosal diseases

prof. MUDr. Lydie Izakovičová Hollá, Ph.D.

prof. MUDr. Antonín Fassmann, CSc.

MUDr. Hana Poskerová, Ph.D.

doc. RNDr. Petra Bořilová Linhartová, Ph.D.

MUDr. et MUDr. Zdeněk Daněk, Ph.D.

Translated to English by: RNDr. Jaroslav Janošek, Ph.D.

Published by Masaryk University Press, Žerotínovo nám. 617/9, 601 77 Brno

3rd electronic edition, 2020

ISBN 978-80-210-9563-2